Leiden, 1961 THESIS Lane

SUBCORTICAL PROJECTIONS ON THE SPINAL GREY MATTER OF THE CAT

LANE LIBRARY. STANFORD UNIVERSITY

A. STAAL

SUBCORTICAL PROJECTIONS ON THE SPINAL GREY MATTER OF THE CAT

PROEFSCHRIFT TER VERKRIJGING VAN DE GRAAD VAN DOCTOR IN DE GENEESKUNDE AAN DE RIJKS-UNIVERSITEIT TE LEIDEN, OP GEZAG VAN DE RECTOR MAGNIFICUS DR. G. SEVENSTER, HOOGLERAAR IN DE FACULTEIT DER GODGELEERDHEID, TEGEN DE BEDENKINGEN VAN DE FACULTEIT DER GENEESKUNDE TE VERDEDIGEN OP WOENSDAG 8 NOVEMBER 1961 TE 16 UUR

DOOR

ARTHUR STAAL

GEBOREN TE 'S-GRAVENHAGE IN 1926

DRUK: KONINKLIJKE DRUKKERIJEN LANKHOUT-IMMIG N.V. - 'S-GRAVENHAGE

PROMOTOR

PROFESSOR Dr. W. J. C. VERHAART

To my wife

To my parents

ACKNOWLEDGEMENT

THIS IS TO EXPRESS MY GRATITUDE TO DR. H. F. M. BUSCH FOR HIS INVALUABLE ADVICE IN TECHNICAL MATTERS

CONTENTS

INTRODUCTION 7

CHAPTER I

Material and Methods 9

CHAPTER II

The grey matter of the spinal cord 15

CHAPTER III

The interstitiospinal fibresystem

Review of the literature 20

Experiments 21

Discussion 34

CHAPTER IV

The tectospinal fibresystem

Review of the literature 37

Experiments 39

Discussion 50

CHAPTER V

The rubrospinal fibresystem

Review of the literature 52

Experiments 55

Discussion 70

CHAPTER VI

The vestibulospinal fibresystems

Review of the literature 73

Experiments 78

Discussion 99

CHAPTER VII

The reticulospinal fibresystems

Review of the literature 101

Experiments 105

Discussion 146

CHAPTER VIII

General discussion 152

SUMMARY 155

REFERENCES 165

INTRODUCTION

In this thesis the course of some subcorticospinal fibresystems and their terminalia in the spinal cord of the cat have been investigated. For this purpose lesions were made in various subcortical areas and the secondary fibre degeneration in the grey and the white matter of the cord was studied.

The systems concerned are the interstitiospinal, the tectospinal, the rubrospinal and the vestibulospinal systems and the reticulospinal fibres originating in the pons Varoli and the medulla oblongata.

The methods used for visualizing the degenerated fibres in the white and the grey matter of the cord were respectively Häggquist's modified methylblue-eosin staining and the silver impregnation introduced by Nauta and Gygax. The course of the fibresystems in the white matter is dealt with concisely, as the main objective in this experimental study is to localize the terminations of the subcorticospinal fibresystems in the grey matter of the cord.

After explaining in the first chapter the choice of methods used, the various classifications of the grey matter of the cord are discussed in the second chapter. Next the different systems are dealt with, each in a separate chapter. These chapters contain a survey of the literature, the descriptions of the experiments, and a comparision of the results of the experiments with the data of the literature. The last chapter is dedicated to a general discussion of the experimental results. Finally a summary concludes this study.

CHAPTER I

MATERIAL AND METHODS

Animals experimented on were normal adult cats, which were operated upon under general anesthesia, brought about by intraperitonially injected 1 percent evipan solution, about 1 mil per kg body weight. Lesions were mostly made stereotactically by electrocoagulation. In the descriptions of the lesions we used the sections through the brainstem as described by Busch (1961). Some of the animals of which we described the degeneration in the cord, were originally used by Busch in his study of the brainstem. The animals were killed from 10 to 21 days after the operation, by perfusion with 10 percent formalin in deep evipan-anesthesia.

The technique

In order to determine the fibresystems of the white matter involved, a number of preparations according to Häggqvist's modified methylblue-eosin staining were made at various levels of the cord. As this method shows both normal and degenerated fibres, it is especially appropriate to indicate such fibresystems and their localization in the white funiculi. The technique has been elaborately described by Van Beusekom (1955). Next it had to be considered in which way the degenerated terminations of these tracts in the grey matter could best be visualised. As is generally known, myelinstaining methods are of no avail, because the myelinsheath ends before the terminal part of the fibre is reached. Therefore only silverimpregnation methods staining the axon can be used (Nauta 1950). However, distinguishing degenerating terminals and preterminal axons requires more, and degenerating axons will also have to be distinguished from the normal. Gibson (1937), using Cajal's 6–a reduced silver method, succeeded in demonstrating degeneration of the "boutons terminaux" in the anterior and posterior horns after chordotomy in the cat. He reported that Cajal already in 1888 described that collaterals in the cord end on ganglioncells with a varicosity which is in contact with the neuronal cell-membrane, and in 1903 could visualize the connection between the axon and the bouton. Glees in 1946 thought to be able

to impregnate both the normal and the degenerating axon and its terminal branches with a modified Bielschowsky technique, and he proposed to consider both the boutons and the free endings as terminalia. This method and its pecularities has been discussed elaborately by Glees and Nauta in 1955. The simultaneous impregnation of both the normal and the degenerating terminals proved to be a disadvantage as it made it unfeasible to distinguish them from each other, because normal boutons, fragments of coarse axons and degenerating axons can present an almost identical appearance (Hayhow 1959). According to Bowsher (1960) a bouton can be assumed to be affected by degeneration, only when it is seen to be connected to a degenerating axon. This is hard to realize, because the bouton and its axon rarely lie in the same level and therefore are not present in the same preparation. Therefore a method for staining degenerating axons selectively was looked for.

Nauta and Ryan in 1952 introduced a silverimpregnation method which showed some selectivity with regard to the degenerating axon, staining it black, whereas the normal only takes a pale brown color. However, the axon does not stain down to its very end, and the degenerating boutons remain unstained; the authors therefore call it a preterminal axonal degeneration stain. In 1954 Nauta and Gygax published a modification of the former technique, by which the degenerating axon was almost exclusively stained and the co-staining of normal fibres could be suppressed to a high degree. In this way degenerated fibres can be much more easily discovered than by the former method which required high power magnification. Many authors are of the opinion that it is a very welcome addition to Glees' method. Kuijpers (1958) even states that this method "allows satisfactory identification of degenerating axons including their end-ramifications".

In the present investigation the Nauta-Gygax method is used as modified by Chambers in 1956; it is performed in the following way:

After the cat has been perfused with formalin in deep anesthesia, the brain and the cord are taken out and fixed in 10 percent formalin, neutralized with calcium carbonate, during a relatively long time. It has appeared that material fixed in formalin during some years gave often better results than relatively fresh material. After fixation small blocks are cut from the cord both for Häggqvist and Nauta-Gygax

staining. The latter are cut in frozen sections about 20 mu thick, which are stored in 10 percent neutral formalin. Before being impregnated they are rinsed in aqua bidestillata for a short time, and put in a 1/2 % phosphormolybdenic acid solution during 20 minutes. Next they are put in a potassium permanganate solution 0,1 to 0,05 % for 4–10 minutes. When the solution is too strong and the time too long, neither the affected nor the normal axons are impregnated; when the reverse is the case both are impregnated, and distinguishing them is unfeasible. Both factors moreover, seem to vary from day to day and from one animal to the other. Determining the lenght of time and concentration of the solution may take quite a time.

Then comes short rinsing in bidistilled water and 1–2 minutes decoloration in a mixture of equal parts of a 1 % hydroquinone and a 1 % oxalic acid solution.

The sections are rinsed three times in aqua bidestillata, and impregnated during from 30 minutes to 3 hours in a 1 1/2% silvernitrate solution, preferably in the dark. After this phase the sections should be handled one by one. Next follows short rinsing in aqua bidestillata, and one minute in Laidlow's solution in which they are to be kept in motion.

For one minute the sections should be kept moving in reducing fluid, in which they take on a brown colour. When this colour gets too dark a few drops of ammonia should be added to Laidlow's solution; when it gets too light some 2,5 % caustic soda solution. The reducing solution consists of aqua bidest. 400 ml, pure aethanol 45 ml., unneutralized formalin 13,5 ml, citric acid 1 % 13,5 ml. The sections are washed briefly in aqua bidestillata, soaked in 1,0 % sodium thiosulfate for one minute and again washed in three changes of aqua bidestillata. Before mounting the impregnated material the slides are soaked briefly in 70 and 96 % alcohol respectively.

Nauta is of the opinion that no strict rules can be offered about the period of survival after the operation. In the cat he prefers a 7–10 days period, but Hayhow advocates a 3–7 days survival (1959). Evans and Hamlyn (1956) found preterminal degeneration to be complete only after a 28 days survival; they could demonstrate it up to from 112 to 164 days after the operation.

In the present investigation the animals were sacrificed from 10–21 days after the operation.

Description of the microscopical picture in Nauta-Gygax stained slides

In well-stained slides degenerating axons show a black colour against a yellow-brownish background. Occasionally the background stains much lighter, which makes the affected axons the more conspicuous. Preterminal degeneration is characterized by fragmentation and varicous disintegration of the axons, which may be localized around ganglioncells and their dendrites (Nauta 1957, Thomas 1956). Disintegrated axons also may occur; they show as rows of drop-like formations. When they can be followed over some distance they will have to be considered as passing axons, but distinguishing them from real preterminal degeneration may be awkward. Thus not all of the degeneration seen exclusively concerns the final part of the axon, but when fragmentation is very fine in caliber, preterminal degeneration may be assumed to be highly probable, even if it is not located close to a ganglioncell. The apparent absence of a ganglioncell in Nauta-Gygax preparations may be due to the cell or its dendrites not being stained over their total lenght; often the dendrites are readily recognisable only in the close promixity of the perikaryon. Other methods that make them visible demonstrate that the cellbody and the dendrites of the anterior horn cells are all but covered with boutons (Rasmussen 1957). The term "preterminal degeneration" therefore is applicable not only to preterminals near the ganglioncell body but also to those terminating along the stained and not stained dendrites (Sprague, 1958). This means that pictures suggesting preterminal degeneration have proved to indicate the presence of non-stained ganglioncells or their dendrites. In addition to degenerated axons a number of normal axons also are visible, and in them a number of artefacts may occur that will have to be distinguished from signs of degeneration.

These are the so-called myelinsheath artefacts, black cufflike formations (Nauta 1957), which are considered to be seen especially in Chambers modification of the Nauta-technique (Chambers 1956).

Normal axons may show spindleshaped and romboïd enlargements, mostly spread at random in a section but occasionally confined to certain

fibresystems, which render them more liable to be mistaken for degenerating ones (Glees and Nauta 1955). Coarse normal axons may be incompletely impregnated, but degenerative fragmentation can be distinguished from them by their dropshaped fragments. Transversely cut axons in the white matter of the cord may show very poorly in Nauta-Gygax stained preparations; however, in this study we are only concerned with prae-terminalia (in the grey matter). Otherwise it is recommendable not to draw conclusions from one solitary degenerating axon, as according to others they may occur in normal material as well. More or less fine precipitation of silver occasionally may be present, but with some experience it can usually be easily distinguished from degenerating axons. According to Nauta and Glees (1955) "droplike disintegrating is the sole dependable criterion of axonal disintegration". From this it will be apparent that the Nauta-Gygax impregnation cannot be considered as completely selective with regard to degenerating axons, and preterminal degeneration has to be concluded also from the morphological aspect. In the cord of a normal cat stained with the Nauta-Gygax technique however, pictures resembling degenerating preterminals could not be found. The same was established for the normal diëncephalon of macaca by Adey et al. in 1958.

In the following chapters in accordance with Kuijpers (1958), "degeneration" will mean that disintegrating passing axons and very fine preterminals are seen. When such degeneration is visible along the dendrites of the nerve-cells, it will be reported especially, whereas preterminal degeneration around a ganglioncell will be called "pericellular degeneration".

Relatively coarse disintegrating axons or bundles of axons showing the criteria of preterminal degeneration, that can be seen already at the transition of the grey and the white matter and can be followed over some distance, will be reported as "passing disintegrating axons". Finally it seems justified to conclude to preterminal degeneration, even when very sporadic, if it is found at the same site in a number of preparations and in more then one similar experiment.

Localization of the preterminal degeneration within the grey matter

As a generally accepted cytoarchitecture of the spinal grey matter still

does not exist, localizing the degeneration is awkward. Therefore the affected fibres will be depicted in schemes of the different levels of the cord. Subsequently its localization will be described in well-known terms such as the anterior and the posterior horns, the intermediate grey matter, the base of the posterior horn, Clarke's column and the central grey matter. At the end of the description of each experiment the degeneration will be identified in Rexed's architectonic system (1952, 1954). As the sections used are only 20 mu thick and the neurons show much less clearly than in Rexed's 100 mu Nissl stained sections, localization in this way will indicate only the site with regard to Rexed's 10 lamellae.

Practically, it proved unfeasible to express the intensity of degeneration in the pictures, therefore the dots in the schemes are intended to indicate the site of the degeneration only. In the description the intensity will be classified as slight, moderate or severe.

Depiction of the degeneration of fibres within the white matter

Degeneration within the white matter will be depicted by hatching the areas where those fibres are most numerous, which does not exclude the presence of a number of degenerated fibres outside the area hatched. As the localization of the degenerated fibres within the white matter serves only as a control on the preterminal degeneration within the grey matter, il will be described only briefly.

CHAPTER II

THE GREY MATTER OF THE SPINAL CORD

Within the scope of this study it is not appropriate to review the large number of papers, published on the classification of the different nuclei of the grey matter of the cord. Therefore only a short survey will be given of the various neuro-anatomical ways in which the grey matter has been studied.

I. *Cyto-architecture*

In general, cyto-architecture entails describing the characteristics of the nerve-cells: their numbers, arrangement, size, shape, internal structure and density. Another aspect of cyto-architecture is the occurrence of different kinds of nerve cells in one area. Besides this the characteristics of the areas to be investigated will be of paramount importance, as for instance in the cyto-architecture of the cerebral cortex the points of importance will be very different from those in the reticular formation of the brainstem (Meessen and Olszewsky, 1949).

The cord of man and different animals has been studied in this way by Clarke (1851), Stilling (1856, 1859), Waldeyer (1888), Ziehen (1899) and Jacobsohn (1908) already in the second half of the previous and the beginning of this century. More recent work by Massaza (1922, 1923 and 1924) and by Bok (1928) was done in essentially the same way. Later investigators, similarly studying the cyto-architecture of the cord, objected that formerly only very thin transverse sections of one or a few specimens of the cord were used and only the segmental structure was revealed, whereas the vertical organization was neglected (Elliot 1942, Rexed 1952). Besides this it appeared that the different workers attributed different names to the same group of cells and more or less arbitrarily united numbers of cells to groups and nuclei.

Rexed studied the grey matter of the cord in transverse, longitudinal, sagittal and parasagittal sections, mostly serially cut. This author described a lamellation of the ganglioncells in the grey matter of the spinal cord of the cat, which he numbered in dorsoventral direction

from 1 to 10. The scheme he gave will be used in the present investigation, as was similarly done by Massopust in 1957.

II. Classification of the elements of the grey matter of the cord according to their *synaptic features* even though most of them are as yet unknown, already gives rise to great confusion.

Nathan and Smith (1955) emphasized that since Golgi and Cajal discovered the collaterals of the axons, termination of an axon on one ganglioncell only can no longer be expected.

A. Division of the ganglioncells according to the cells upon which their axon project was done by Cajal in 1909; his division is as follows:

1. Ganglioncells of which the axon leaves the cord, such as the motor neurons of the anterior horn.
2. Ganglioncells of which the axon does not pass beyond the cord itself. To this group belong the "Cellules commissurales antérieures" which send their axon to the contralateral anterior funiculus, and the "Cellules homofuniculaires", which send their axon to the ipsilateral anterior funiculus where they take part in the formation of a number of fibre-systems, and the "Cellules à cylinder-axe complexe", of which the axon divides in parts that proceed to both halves of the cord and take part in the formation of fibre-systems in both.
3. Ganglioncells with a short axon terminating in the grey matter both ipsi- and contralateral to the neuron of origin.
4. Ganglioncells of which only the axon lies within the cord (the sensory neurons of the spinal ganglia).

Evidently this method (especially ad 1) has given rise to the formation of a number of ganglioncell groups or nuclei, depending on their way of projection only, such as the cells of origin of the accessory nerve (Tsuruyama 1938), those of the phrenic nerve (Warwick 1956), the radial nerve (Ono 1933) and the peroneal nerve (Balthasar 1952). Concerning their axonal connections, Romanes (1951) was able to make a distinction between a ventromedial and dorsomedial cellcolumn in the ventral horns of the lumbar enlargement in the cat, by means of studying the retrograde celldegeneration after peripheral nerve sections. In the cellcolumns mentioned he could even make subdivisions with regard to single muscles.

B. Next we may base the classification of the ganglioncells of the cord on the character of the afferentia of the neurons such as:

1. The afferentia comprised in the posterior roots, whether or not interrupted in an intercalate cell.

2. The extraspinal afferentia, the study of which has been stimulated much by the silverimpregnation techniques. Kuijpers et al. in 1960 explored the pathways originating in the subcortical centra and distinguished a lateral and a ventromedial fibresystem. The first proved to terminate around ganglioncells located in the base of the posterior horn and the intermediate grey matter, the other in the medial and dorsomedial portions of the anterior horn and "the adjacent parts" of the intermediate zone of the grey matter. The other data about this matter from the literature will be referred to in the chapters concerned with them. The terminations of the cortico-spinal fibres have been described in the cat by Szentágothai-Schimert (1942) at the base of the posterior horn and within the intermediate grey matter but not in the anterior horn. Besides this he observed that even in large lesions of the mesencephalon no degenerated terminals were found in the anterior horn. These were found only when the medulla and the vestibular nuclei or the vestibulospinal pathways were damaged. He used Reumont's method, the Bielschowsky block silver impregnation and that of Bielschowsky and Gross. Similarly, Chambers and Liu (1956) with the Nauta-Gygax technique, following severance of the corticospinal pathway in the cat, found the terminals to be confined to the posterior horns and the intermediate grey matter.

Investigations about these terminations with the Nauta-Gygax technique were done by Kuijpers (1958, 1960). In the cat, after section of the lateral pyramidal tract, he found only very few terminals and preterminal ramifications in the anterior horn. The large majority of the terminals in the upper cervical cord could be followed into the nucleus proprius and the basal parts of the posterior horn and the zona intermedia. In Macaca he found a projection of the precentral cortical area to the basal parts of the posterior horn, the intermediate grey matter and the anterior horn. The postcentral gyrus however, proved to project mainly on the nucleus proprius and the posterior horn, whereas in the chimpansee terminals in the anterior horn were numerous.

This confirmed more or less the results of the experiments in three macaques, a baboon and a chimpanzee, done by Hoff and Hoff (1934). These authors used the Cajal's reduced silver method. After unilateral extirpation of area 4 of Brodmann "degenerated nerve endings were found in the cervival and lumbar enlargements on dendrites and cell-bodies lying in the intermediate zone of the contralateral grey matter and in the ventral horn". Following removal of both motor- and pre-motor areas, degenerated boutons were found at the contralateral side, around cells of the base of dorsal- and ventral horns and the intermediate grey matter, but also on cells "evenly distributed throughout the entire ventral horn of both sides".

C. Besides the long ascending and descending fibresystems a great number of spino- spinal fibresystems have been assumed to exist (van Beusekom, 1955).

Nathan and Smith (1959), described the following nine systems:

1. The anterior, lateral and posterior ground bundles.
2. Lissauer's tract.
3. The cornu- commissural tract.
4. The comma-tract.
5. The septo-marginal tract.
6. The anterior septal fibres of Hoche.
7. The anterior commissure.
8. The posterior commissure.
9. The intrinsic fibres of the grey matter.

From these references it is clear that no practical classification of the ganglioncell groups of the cord can be given on account of their fibre-connections. This is the more so because most of the fibresystems mentioned, during their course in the cord, give off collaterals at various levels, which fact rather complicates the picture.

At the end of this chapter the connections of the spinal cord ganglion-cells can be summarized as follows:

1. Efferent connections along the anterior root, the propriospinal systems, and the long ascending pathways.

2. Afferent connections from: the ganglioncells of the spinal ganglia, ganglioncells in the same and in other segments of the cord, ganglion-cells of the cerebral cortex, and subcortical nuclei.

It is questionable whether it is feasible to classify the ganglioncells in the cord according to their connections, because these are very complicated and far from surveyable. Therefore it seems important to repeat Rexed's study on the cyto-architectural classification of the spinal grey matter.

CHAPTER III

THE INTERSTITIOSPINAL FIBRESYSTEM

REVIEW OF THE LITERATURE

The origin of the interstitio-spinal fibres

In 1892 and 1893 Held already described in the cat, a nucleus in the mesencephalon, consisting of large ganglioncells, which he localized ventrolateral to the superior oculomotor nucleus and dorsal to the red nucleus. He called it the "oberen Lateralkern", superior lateral nucleus or Darkschewitsch nucleus, but by other authors it had been named the nucleus of the fasciculus longitudinalis, the nucleus of the posterior commissure and the nucleus anterolateralis. However, the course of the fibres originating in it prove it to be Cajal's interstitial nucleus and not Darkschewitsch's nucleus, which contains small cells.

Kohnstamm (1900, rabbit) found retrograde cellchanges in the interstitial nucleus following a hemichordotomy. Similarly it can be concluded that Lewandosky's tractus nuclei Darkschewitschi certainly had its origin in the interstitial nucleus, because it had exactly the same course and termination as the interstitiospinal tract. Moreover fibres descending from Darkschewitsch nucleus into the cord have never been seen, neither have retrograde cellchanges been reported after section of the anterior funiculus of the cord (Foerster and Gagel 1932). As yet it is generally accepted that the fibres of the system under consideration have their origin in the large multipolar ganglioncells of Cajal's nucleus interstitialis (Nathan and Smith 1955).

The course of the interstitiospinal fibres

A relatively large number of authors using the Marchi technique saw degenerated fibres in the ipsilateral sulcomarginal zone of the cord after severance of the insterstitiospinal tract in the brain stem.

Probst (1900), after a lesion of the nucleus commissuralis posterior in the cat found degeneration in the medial longitudinal fascicle down to the lumbar segments of the cord. At a cervical level he localized the degenerated fibres at the dorsal side of the anterior fissure, ipsilateral

to the lesion. However, he did not give a name to this fibresystem. Muskens (1914), in the cat following experimental lesions, saw thick degenerated fibres in the anterior funiculus of the cord, close to the middle of the medial anterior fissure descending into the lumbar cord, which he considered to belong to the interstitiospinal tract.

Bucher (1952), after lesions of the interstitial nucleus in the cat, could trace degenerated fibres down to spinal levels, which, however, she did not define as to their exact site. They ran at the side ipsilateral to the lesion. Hassler (1954), in the cat, gave a description of the course of the interstitiospinal fibres that is similar to those already reported.

In a series of experiments in the cat with the help of Häggqvist's methyl-blue-eosin stain Van Beusekom (1955), Verhaart and Van Beusekom (1958) and Busch (1961) could confirm the older observations about the interstitiospinal fibres. They found thick fibres, arising from Cajal's nucleus, descending in the ipsilateral, medial longitudinal fascicle or sulco-marginal zone; these fibres could be followed according to Van Beusekom down to the 7th cervical segment.

Termination of the interstitiospinal fibres

From Marchi-stained slides Lewandowsky drew the conclusion that his tractus nuclei Darkschewitschi terminates scattered in the anterior horn ("sich im cornu anterius aufsplittert"). Kuijpers et al. in 1960 in their study about the subcorticospinal systems in which they used the Nauta-Gygax method, did not report about the termination of the interstitiospinal fibres particularly. They only described a system running in the anterior funiculus of the cord in which interstitiospinal fibres are present, which terminated in the medial and dorsomedial parts of the anterior horn and adjacent parts of the zona intermedia.

EXPERIMENTS

Cat H 3617

Electrocoagulation of the medial longitudinal fascicle at a high pontine level. The lesion encroaches upon the medial parts of the deep tegmental nuclei of Von Gudden and the dorsalmost parts of the predorsal fasciculi

and of the crossing of the brachium conjunctivum (Cat M 5 of Busch). The animal was killed 10 days after the operation.
Microscopical examination of the lesion proved that bilaterally the interstitiospinal system area was severed while the tectospinal system area was only somewhat damaged. Descending degeneration in the cord therefore could not be expected to be entirely selective with regard to the interstitiospinal fibres, though the admixture with tectal fibres might be supposed to be very slight.

Degeneration in the cord is found to be located as follows: in the C 2 segment in the white matter there is a bilateral area of degeneration in the sulcomarginal zone near the anterior commussure, at both sides of the fissura mediana. There is an other area in the most ventral part of the anterior funiculus, attributable to the severed tectal fibres. In the C 5 segment the white matter degeneration is unaltered, except for that of the tectal fibres which can no longer be seen. In the grey matter at the side where the degeneration is most intense and widespread, it is seen in the most dorsal portion of the medial half of the anterior horn and from there it spreads in a latero-ventral direction to halfway the width of the horn. In the central grey matter degeneration can be found at both sides of the central canal whereas bilaterally in Rexed's lamina 7 pericellular degeneration is distinct. Its intensity is moderate. The C 7 segment. Degeneration in the white matter is unchanged. In the grey matter at the side of the more severe degeneration this degeneration enters the anterior horn in its most dorsomedial part and can be followed in a latero-ventral direction to about the centre of the horn. At the other side the degeneration is found at the dorsal half of the medial margin of the anterior horn and within the horn it extends somewhat laterally. At both sides it is slight to moderate in intensity.
Upper thoracic segment. Compared with the previous level, degenerated fibres within the white matter are seemingly less in number. At one side in the grey matter degeneration is found along the dorsal part of the medial margin of the anterior horn, from where it can be followed into the central grey matter, in casu Clarke's column. At the other

1

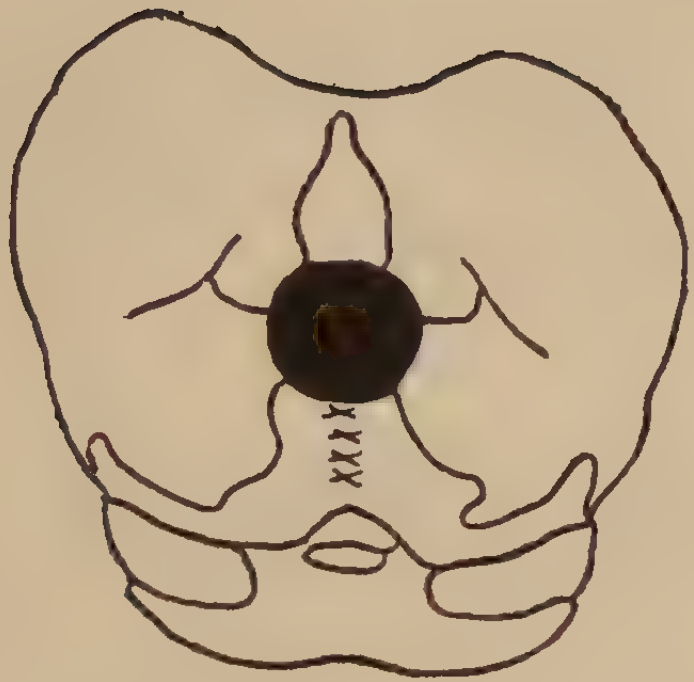

2

3

4

Lesion in Cat H 3617. The lesion involves the medial longitudinal fascicle bilaterally, and the surrounding central grey matter at the caudal extremity of the aqueduct. It encroaches upon the medial parts of the deep tegmental nuclei of Von Gudden and the dorsal parts of the predorsal fascicles and the crossing of the brachium conjunctivum, (cat M 5 of Busch, 1961).

side, degeneration is less intense at the margin of the anterior horn; it shows the same localization but laterally it can be traced to the centre of the horn without touching even the ventral border of the central grey matter. The degeneration is only slight in intensity.

Caudal thoracic segment. Degenerated fibres in the white matter have shifted somewhat laterally in the anterior funiculus; at one side they are more numerous than at the other. On this level the Nauta-impregnation gave no good preparations.

In the L 1 segment the white matter still shows a few degenerated fibres but in the L 3 segment these cannot be found anymore. In the grey matter at the L 3 segment there is some degeneration in the laterodorsal part of one of the anterior horns and in the L 7 segment some degeneration is seen along the medial margin of the anterior horn at one side only. In the sacral segments degeneration is entirely absent.

SUMMARY

Within the white matter a small number of degenerated fibres were present at both sides of the fissura mediana anterior, at the dorsal part of the anterior funiculus near the anterior commissure. They could be followed down to the first lumbar segment. Only in the upper cervical segments some degeneration was seen in the ventromedial part of both anterior funiculi.

Within the grey matter degenerated fibres were localized in the different segments as follows:

segments C 5 and 7 in Rexed's laminae 7 and 8, and in C 5 also at both sides of the central canal. The intensity of the degeneration was slight to moderate. At the upper thoracic cord it lay in the laminae 7 and 8, and at one side near the lateral margin of Clarke's column, in lamina 7. At the L 7 segment it lay in lamina 8 but it comprised only a few fibres. Similarly to the thoracic segments it was only of slight intensity.

Cat H 4856

Electrocoagulation in the plane A 6, which proved to destroy the interstitiospinal system unilaterally near its origin. No other descending systems to the spinal cord were damaged. The animal was killed ten days after the operation.

C 2

C 5

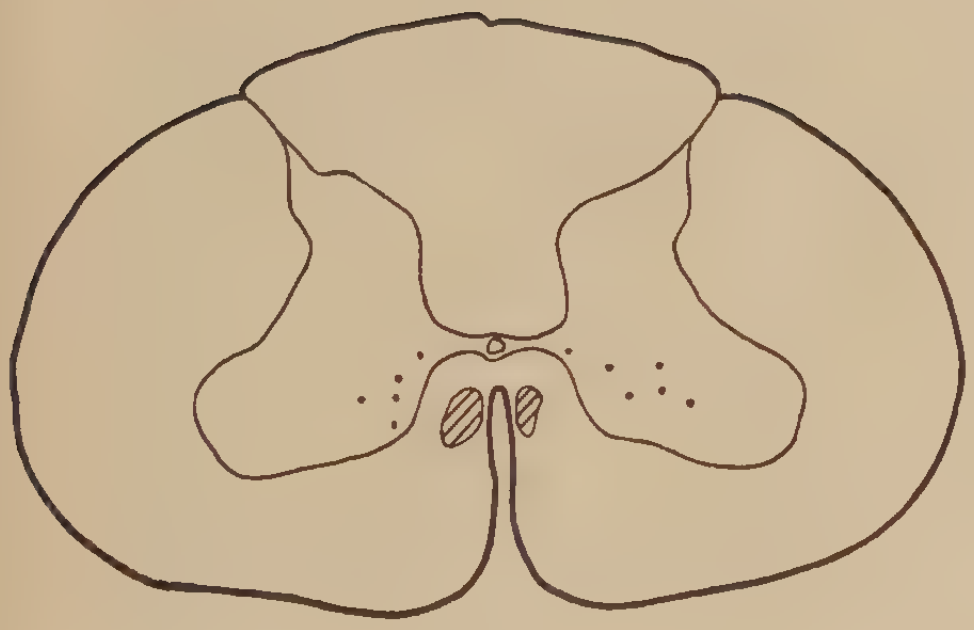

C 7

Th. hoog

Th. laag

L 3

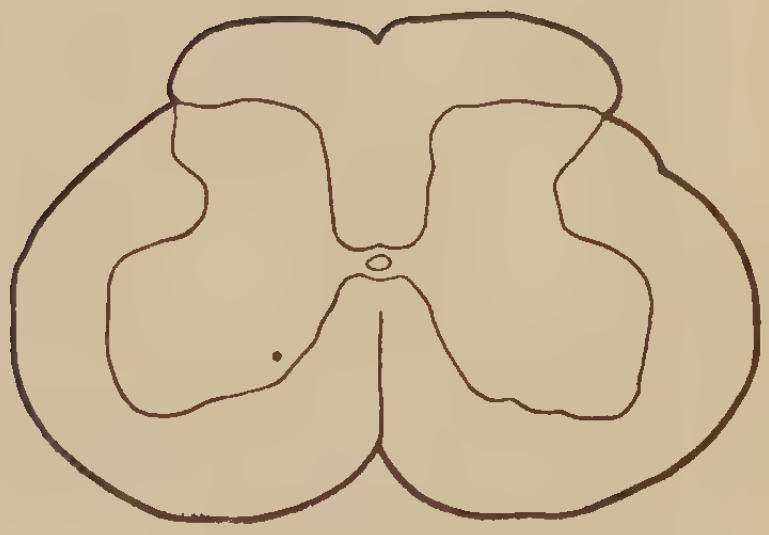

L 7

Degeneration in the cord of Cat H 3617.

Degeneration in the cord

In the C 1 segment a unilateral area of degeneration is found in the sulcomarginal zone, near the anterior white commissure, separated from the fissure only by a narrow strip of normal fibres.
Within the grey matter, degenerated passing fibres enter the anterior horn by its medial margin and traverse it to almost its lateral border. From the area of entrance some fibres radiate both dorsally and ventrally and fine preterminal degeneration is seen along the dendrites of the neurones as well as pericellularly a short distance from the medial margin. The degeneration is moderate in intensity.
In the C 2 segment the localization of the degenerated fibres within the white and the grey matter is identical to that in the C 1 segment. Pericellular degeneration is present at several places in lamina 8.
In the C 3 segment the white matter shows the same degeneration. In the grey matter the degeneration is less severe than in the previous level; from the medial margin of the anterior horn it proceeds far laterally, and pericellular degeneration is found occasionally.
In the C 7 segment the white matter shows only a few degenerated fibres, markedly less than in the C 3 segment. The grey matter shows some degeneration only at its medioventral portion, and the lateral half is nearly free from degenerated fibres. At the contralateral side in some slides very few degenerated fibres are seen, but in others it is not found at all; therefore is it not depicted in the scheme.
In the thoracic segments the white matter shows no degenerated fibres. The grey matter in the lower thoracic segments unilaterally shows a slight to moderate degree of degeneration; pericellular degeneration can be distinguished repeatedly in lamina 7. In the L 3 segment within the grey matter in the mediodorsal portion of the anterior horn slight degeneration is present which spreads in a dorsolateral direction. Similarly pericellular degeneration is visible in lamina 7. In the L 6 segment some degeneration is present in the dorsomedial half of the anterior horn at the border of laminae 7 and 8.
At the segment L 7 and in the sacral cord only in some of the slides a few degenerated fibres are found within the laminae 7 and 8, the medial half of the anterior horn (not depicted in the scheme).

A 8

A 7

A 6

Lesion in Cat H 4856.

SUMMARY

In the white matter, down into the C 7 segment, degenerating fibres were found in the dorsal part of the sulcomarginal zone, close to the anterior commissure and very near the fissura mediana anterior.
Within the grey matter preterminal degeneration was localized as follows: C 1: laminae 7 and 8; C 2, 3, and 7: lamina 8; Th 7 and L 3: lamina 7. In the upper cervical segments it was of moderate and more caudally of slight intensity.

Cat H 4857

The lesion at plane A 6 comprises unilaterally part of the interstitiospinal system near its origin. No other descending systems to the spinal cord were damaged.
In this animal, which was killed ten days after the operation, the degeneration in the white matter is found at the same localization as in cat H 4856, it can be followed down to the seventh cervical segment, its intensity being somewhat less than in the previous animal.
In the grey matter the degeneration is found as follows: in the C 1 segment ipsilateral to that in the white matter, degeneration of slight intensity is spreading from the medial margin of the anterior horn latero-dorsally to the centre of the horn. The central grey matter is free from degeneration.
In the C 2 segment the degeneration is somewhat diminished in intensity; its site has not changed. In the C 3 segment it can be followed into the intermediate grey matter.
In the C 7 segment it begins in the most dorsal part of the medial margin of the anterior horn, and proceeds ventrolaterally to the centre of the horn. The intensity is somewhat increased and can be qualified as slight to moderate.
Low thoracic segments. The degeneration is found in the dorsal part of the medial anterior horn margin and proceeds fairly far laterally along the ventral border of the central grey matter. Its intensity is only slight.
In the L 4 segment the degeneration is equal to that in the low thoracic cord.
In the L 6 and 7 and the S 1 segments degeneration is found along the medial anterior horn margin, but it is very scarce.

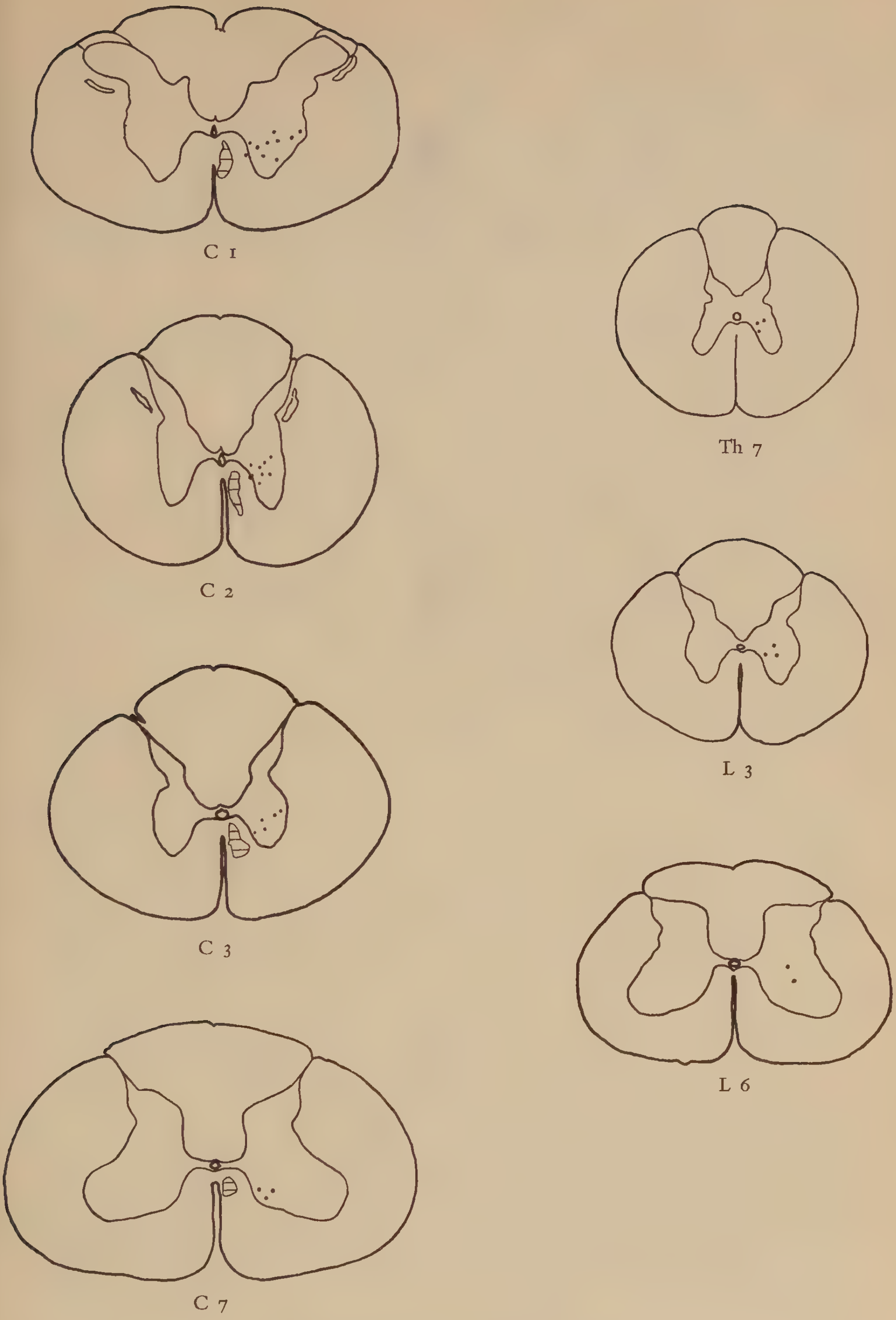

Degeneration in the cord of Cat H 4856.

A 7

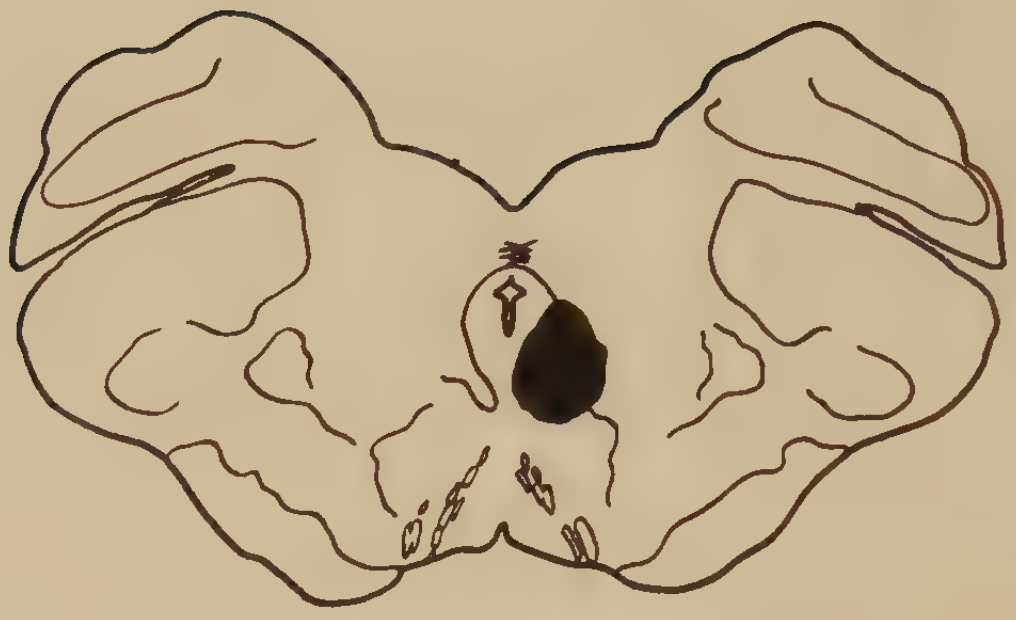

A 6

A 5

Lesion in Cat H 4857.

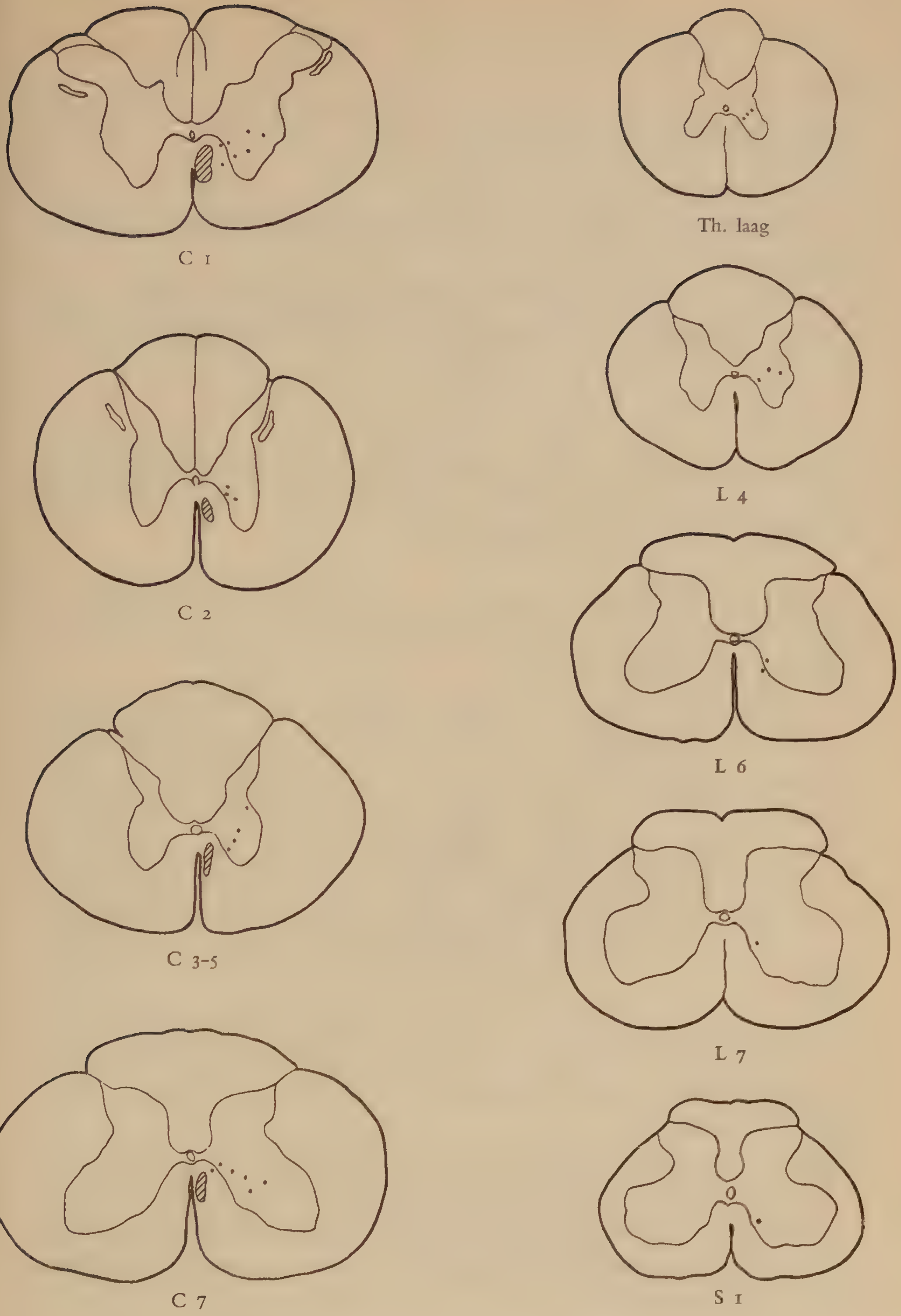

Degeneration in the cord of Cat H 4857.

SUMMARY

Degeneration in the grey matter was found to be slight. It was localized as follows:

In C 1, 2, L 6 and 7 and Sa in lamina 8.

In C 3 in laminae 8 and 6; in C 7 in laminae 8 and 7; in Th 7 and L 4 in lamina 7.

In general real preterminal degeneration was seen everywhere in the areas of degeneration; disintegrating passing axons, however, were also seen.

Cat H 4858

In this animal similarly the origin of the interstitiospinal system was partly destroyed, and the lesion was restricted to its area. The animal was killed ten days after the operation.

The degeneration in the white matter of the cord is about equal to that in the previous cat; it can, however, be followed into the lower segments of the thoracic cord.

In the grey matter in the C 1 segment it enters the anterior horn by the ventral part of its medial margin and proceeds to the lateral part of the horn in a dorsolateral direction. Besides this, some degeneration is seen at the dorsal part of the medial margin. The intensity is slight to moderate.

In the C 2 segment the degeneration is found along the dorsal part of the medial anterior horn margin. In the C 4 segment the degeneration can be followed further dorsolaterally to the lateral half of the anterior horn, however, it does not enter the central grey matter. Its intensity is slight.

In the C 7 segment it is found along the medial anterior horn margin and can be followed laterally to the middle of the horn. Unfortunately, a reliable Nauta-Gygax impregnation could not be obtained in the thoracic segments.

In the L 4 segment the degeneration proceeds from the medial margin of the anterior horn dorsolaterally to the centre of the horn. In the L 6 segment some very slight degeneration is seen in the most dorsal part of the medial anterior horn margin. In lower segments degeneration can no more be found.

A 6

A 5

Lesion in Cat H 4858.

SUMMARY

Within the white matter homolateral degeneration was found in the cervical and thoracic segments, where it lay in the dorsal part of the sulcomarginal zone, close to the fissure. In the grey matter it was located as follows: in the C 4 and 7 segments in the laminae 8 and 7. In the C 1 and 2, the L 4 and 6 segments in lamina 8. The degeneration consisted partly of passing disintegrating axons, and of preterminal structures lying both around and between the ganglioncells. The intensity in general was slight, but in the first cervical segment it had to be qualified as slight to moderate.

DISCUSSION

In three animals (H 4856–4857–4858) the interstitiospinal system in the brain stem could be interrupted subtotally on one side without other systems being encroached upon; in one animal (H 3617) it was severed bilaterally together with the tectospinal system. The degeneration of the latter system, however, in Häggqvist-stained slides could not be followed beyond the upper cervical cord, therefore the degeneration in the grey matter below the cervical cord was attributed to the interstitiospinal system mostly.

In two more cats the interstitiospinal system was severed together with the rubro- and the tectospinal systems (H 3610 and 3710); they will be described in the chapter on the rubrospinal system. With respect to the interstitiospinal system they can give information only about its site in the white matter, because in the grey matter the areas of preterminal degeneration overlap considerably, as will appear later.

The degeneration in the white matter was located in a small area in the dorsomedial part of the sulcomarginal zone. In the case where the system had been most completely severed this degeneration could be followed to the caudal thoracic segments where it consisted of a few fibres only. In the other animals it seemed to stop already in the low cervical or the upper thoracic segments. It is a well known fact that a few degenerating fibres between a great number of normal ones cannot easily be detected.

Within the grey matter preterminal degeneration was most marked

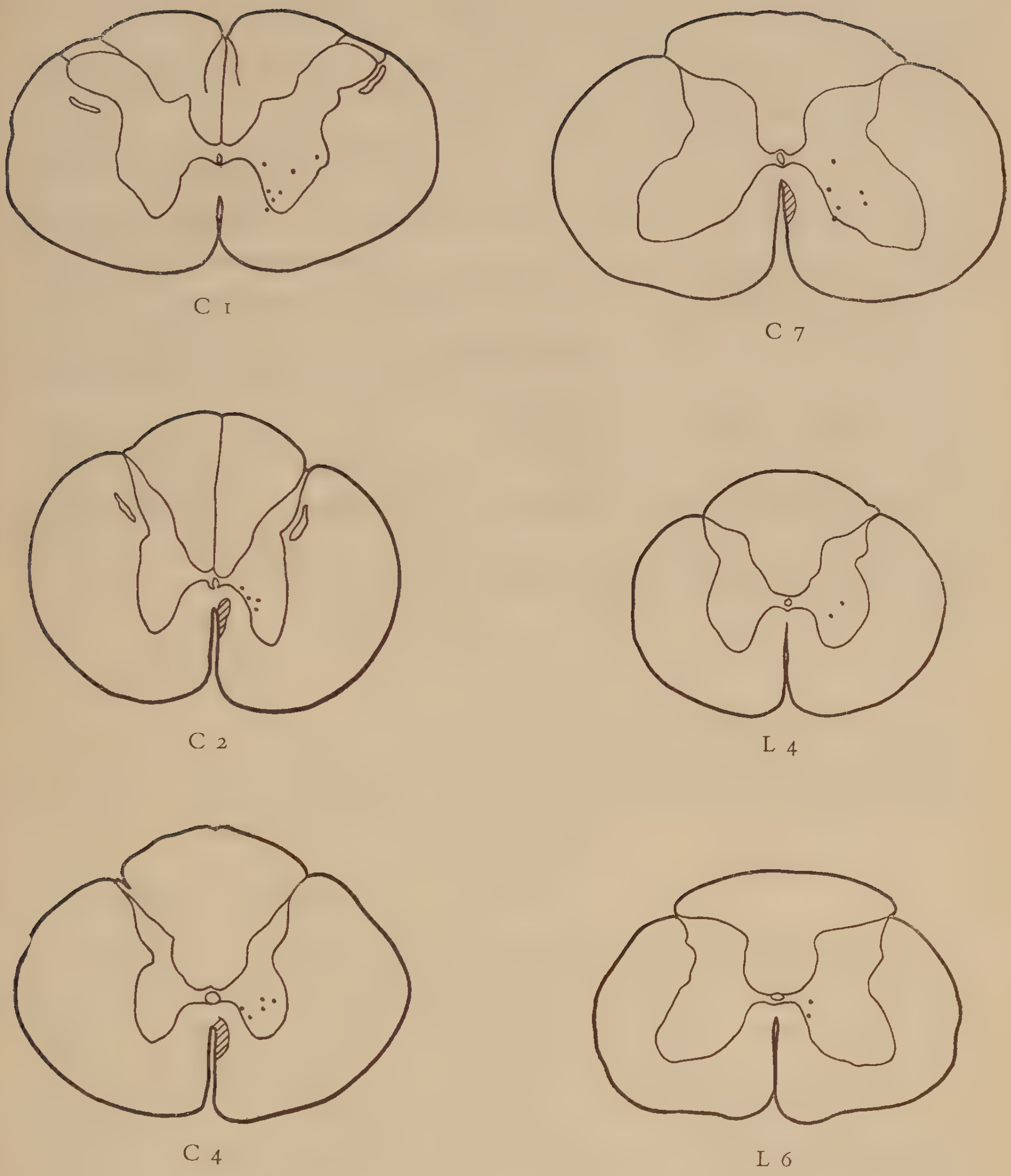

Degeneration in the cord of Cat H 4858.

in the cervical and thoracic levels, whereas in the lumbar it was much less distinct. Only in one cat some degeneration was visible in the upper sacral segments. In the cervical segments it was moderate in intensity, otherwise it was only slight. In the unilateral lesions the degeneration in all of the cases proved to be located ipsilateral to the side of the lesion. Preterminal degeneration of the interstitiospinal fibres in the cervical segments was seen in Rexed's laminae 7 and 8, where pericellular degeneration was also regularly observed. Therefore it is justified to assume that the fibres have their terminations in these laminae. In the lower segments degeneration was mostly restricted to lamina 8.

The localization of the interstitiospinal system in the white matter of the cord as displayed in the present experiments is in accordance with that reported in the literature.

With regard to the termination in the grey matter, data from studies performed with the help of the silver impregnation methods recently developed do not seem to be available. The data acquired in the present study therefore should be regarded as new.

CHAPTER IV

THE TECTOSPINAL FIBRESYSTEM

REVIEW OF THE LITERATURE

Origin of the tectospinal fibres

Most of the studies of this system, similarly to those on the other systems under consideration, have been performed in experimental material with the help of Marchi's osmic acid impregnation method. When not stated otherwise, Marchi's technique has been used by the authors.

In 1893 Held already described "eine aus dem vorderem Vierhügel entspringende Bahn" a tract arising from the anterior quadrigeminal body, whereas Von Bechterew in 1897 declared that in 1888 he had found the fibres of the "Fountain" decussation to arise from the deep cell-layer of the superior colliculus. Tschermak (1898), from his experiments in the cat, came to the conclusion that fibres arising in the superior colliculus descended into the cord. His lesions, however, were too large to justify localizing their origin in the colliculus. Probst (1899), Lewandowsky (1904) and Rasmussen (1936) similarly determined that the fibres originating in the superior colliculus at least partly descended into the cord. Van Beusekom (1955) and Busch (1961) in Häggqvist preparations could confirm this statement.

Course of the tectospinal fibres

According to Held and Von Bechterew the tectal fibres cross in Meynert's fountain decussation, and according to the former, they subsequently travel in a bundle located ventral to the medial longitudinal fascicle. Tschermak (1898) gave to this bundle the name of "prae-dorsales Längsbündel", predorsal longitudinal fascicle. About this bundle he stated "... lagert sich bei Katzen in ein gesondertes Faserbündel, welches durch den ganzen Hirnstamm dicht ventral vom dorsalen längsbündel liegt", in the cat it takes its site in a special fibrebundle, which throughout the lenght of the brainstem lies closely ventral to the medial longitudinal fascicle.

Contrary to these statements, Thomas (1899) in the dog, Pavlov (1900)

and Munzer (1902), in the rabbit, were unable to follow the fibres from the superior colliculus into the cord. Similarly Von Monakow (1909) with Von Gudden's method, could not demonstrate tectospinal fibres in the rabbit and he only accepted the existence of tectobulbar fibres.

Redlich (1899) and Probst (1899), in the cat, saw the tectal fibres diminish in numbers in the brain stem; some of them could be followed into the sulcomarginal zone of the cervical cord.

Probst even found a few in the thoracic segments. Lewandowsky, Von Economo (1910), Rasmussen (1936), Mettler (1943) and Marburg (1947), were of the opinion that in the cat tectal fibres from the superior colliculus descend in the contralateral half of the brain stem and at least partly reach the anterior funiculus of the cord. Tasiro (1940) came to the conclusion that in the cat the tectobulbar and tectospinal fibres travel in separate bundles, and that both contain crossed as well as uncrossed fibres. Although the tectobulbar fibres are beyond the scope of this study they are referred to because most of the authors state that from the tectospinal system many fibres or their collaterals terminate in cellgroups in the pons and the medulla.

Termination of the tectospinal fibres

Probst and Lewandowsky, in the cat, found the fibres to end in the contralateral anterior horn; Probst could follow them to the thoracic segments. Von Economo, in the cat, found them to terminate in the intermediate grey matter and the medial part of the anterior horn, but Marburg in 1947 only mentioned terminations in the anterior horn. Rasmussen, also in the cat, could establish the terminations by localizing them in the medial anterior horn cells and the spinal accessory nerve nucleus.

Rasdolsky (1923), after a hemichordotomy in the high thoracic cord in dogs, studied the terminations of the descending tracts in acid fuchsin light green stained slides. He found tectospinal fibres in the lumbar segments to terminate around small neurons at the base and the centre of the anterior horn. However, it is difficult to understand how he could make such conclusions in total hemichordotomies in which a large number of descending systems are severed.

Szentágothai-Schimert (1941), in albino rats, made lesions in the superior colliculi and studied the brain stem and the cord in Reumont, Bielschowsky and Bielschowsky-Gross impregnated sections. He found degeneration in the grey matter down to the upper thoracic segments, the affected fibres entering the grey matter by the medial anterior horn margin and subsequently curving dorsally, to the intermediate grey matter and the ventral cells of the posterior horn. Terminals on the medially situated motor neurons were relatively scanty but they were numerous on the cells of the nucleus cornucommissuralis.
Pearce (1956) not only used the Marchi technique but also the Nauta-Gygax method, and came to the conclusion that about $^2/_3$ of the superior colliculus fibres end in the brainstem. The remaining fibres, he stated, end in the grey matter of the upper cervical segments. He could follow the degenerated fibres from the anterior funiculus traversing the anterior horn in a dorsolateral direction to reach the spinal part of the accessory nerve nucleus, where the degeneration was fairly marked. In the intermediate zone, the nucleus commissuralis anterior and the dorsal part of the medial half of the anterior horn, degeneration was less conspicuous.

From the literature it can be established that the fibres arising from the superior colliculus descend in the contralateral predorsal fascicle, that a large proportion of them terminate in the brain stem and that the rest takes its site in the sulcomarginal zone of the spinal cord, where it descends to the upper thoracic segments. In the grey matter of the cord terminations are found in the accessory nerve nucleus, the medial part of the anterior horn and the intermediate grey matter.

EXPERIMENTS

Cat H 3614

A lesion in the left half of the tectum has interrupted part of the tectospinal fibres rostral to their crossing. Part of the lesion lies at the junction between the superior and inferior colliculi involving the dorsal half of the mesencephalic root of the trigeminus nerve and the adjoining tectal radiation. The bulk of the lesion lies within the ventromedial

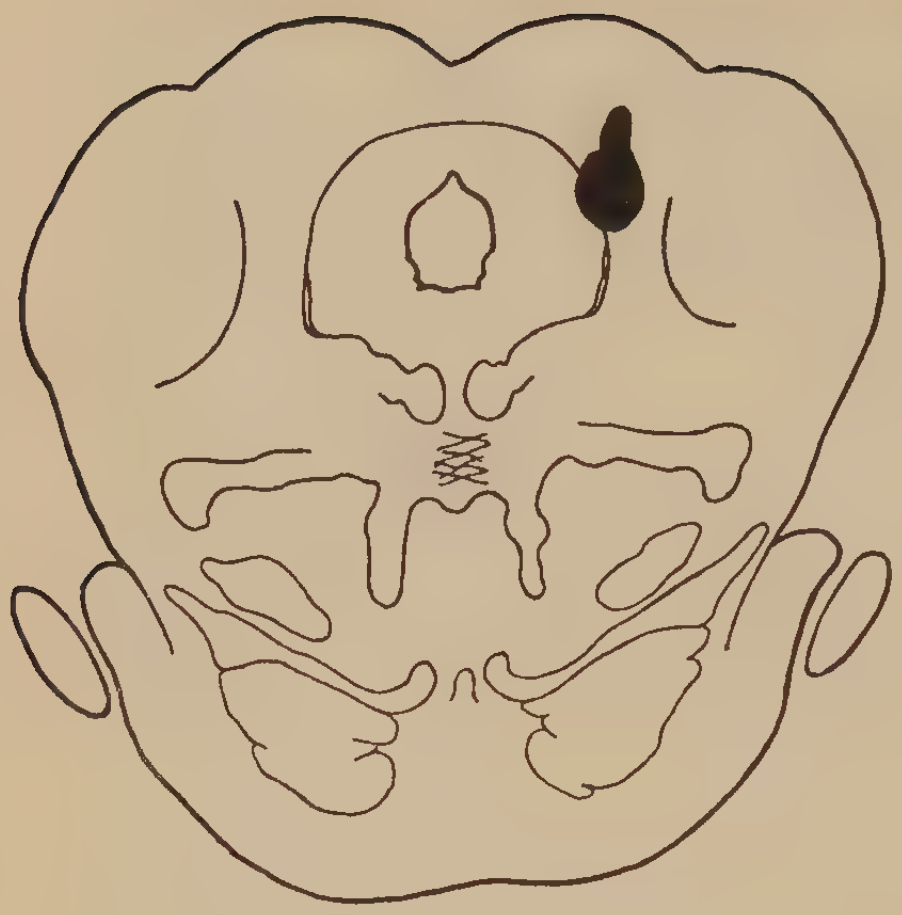

A 1

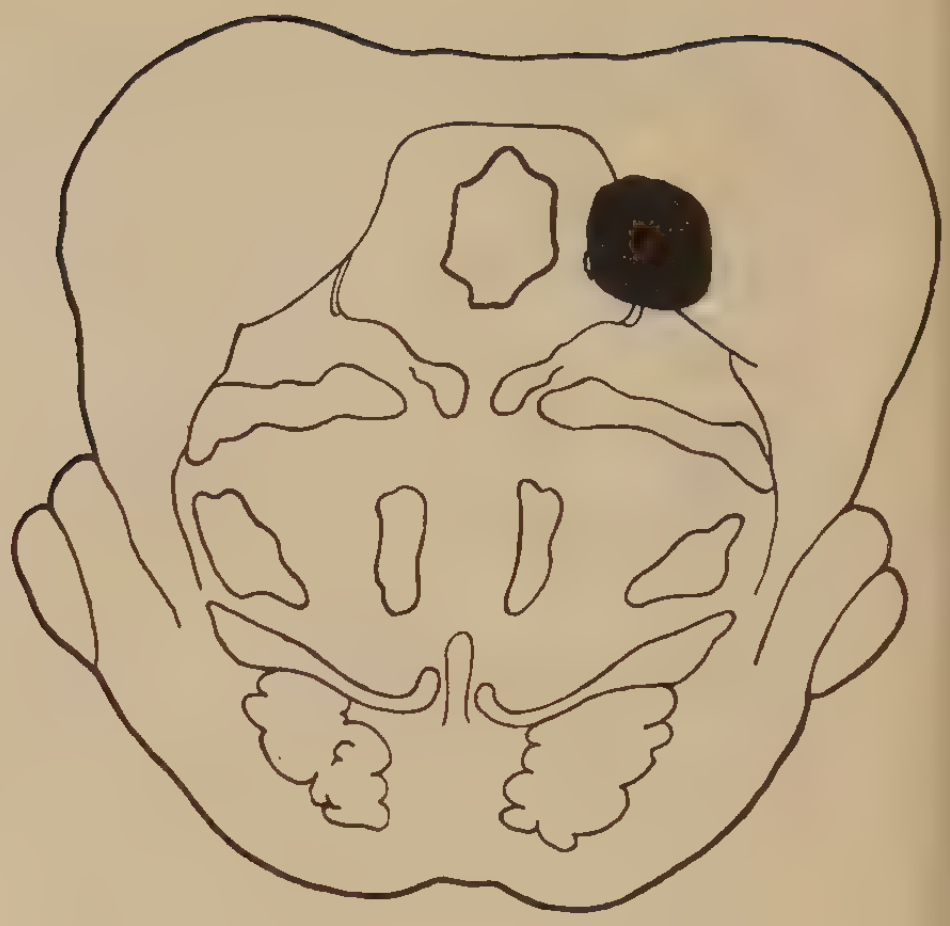

AP 0

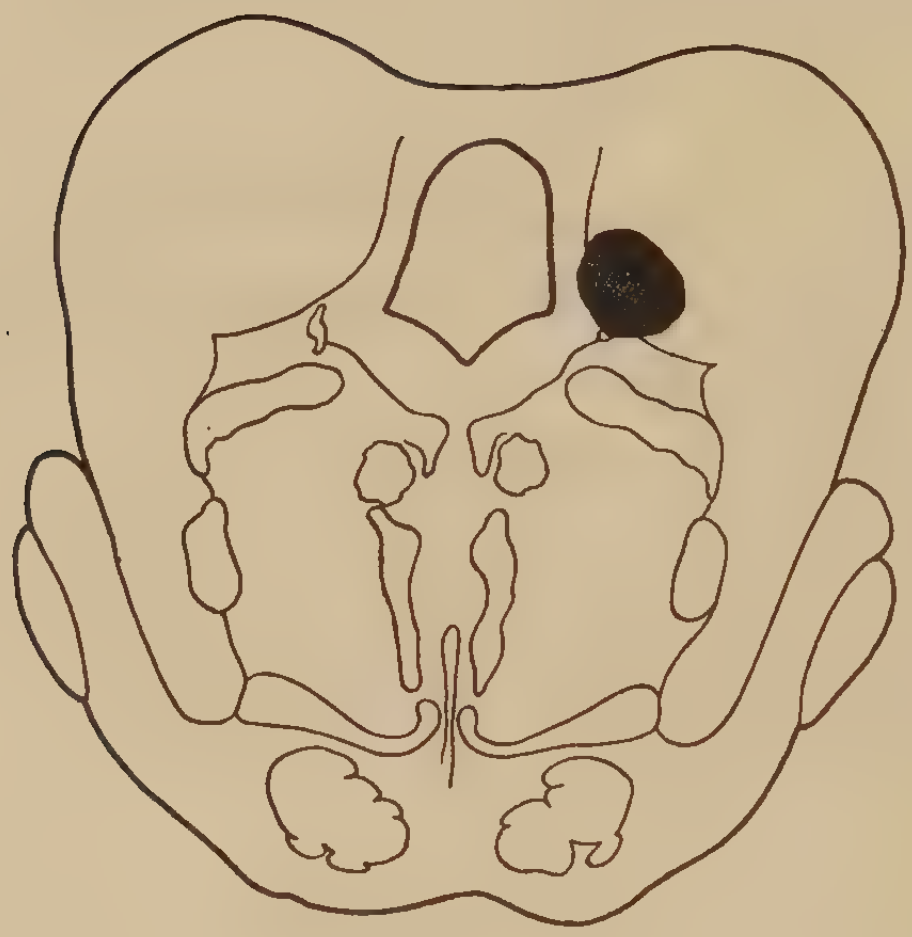

P 1

Lesion in Cat H 3614.

part of the nucleus of the inferior culliculus. The electrode track passes dorsally through the superior colliculus. (Cat M 12 of Busch).
The animal was killed nineteen days after the operation.

In the white matter of the cord an area of degeneration is found at the contralateral side in the ventromedial part of the sulcomarginal zone. It decreases much in intensity in the cervical cord and peters out in the upper thoracic segments.

The grey matter, in a mid-pyramidal crossing level, shows some degeneration of slight intensity at one side in the accessory nerve nucleus and at the other in the mediodorsal part of the anterior horn. In the C 2 segment in some preparations some degeneration is seen bilaterally in the intermediate grey matter.

In the C 3 segment degeneration is found in both the anterior horns, at its ventromedial margins and proceeding dorsolaterally to the intermediate grey matter; it is from slight to moderate in intensity. Pericellular degeneration is present both in the centre of the anterior horns and the intermediate grey matter.

In the C 7 segment the degeneration is only slight, at one side it can be followed from the ventromedial part of the anterior horn to the intermediate grey matter, at the other side there is some degeneration along the medial anterior horn margin.

In the thoracic segments, only at one side, some slight degeneration is seen in the centre of the anterior horn. In the L 3 segment degeneration again is present bilaterally, it is very slight and spreads throughout the anterior horn. In the L 6 segment some degeneration is located in the medial and central parts of both anterior horns. In the L 7 segment in some preparations occasionally some degeneration is found along the medial anterior horn margin and within the intermediate grey matter. In the sacral segments some very slight degeneration is visible in the ventromedial and central parts of the grey matter at one side only.

SUMMARY

In the white matter heterolateral degeneration was found in the anteromedial part of the sulcomarginal zone down to the upper thoracic cord. In the grey matter the preterminal degeneration observed was slight in intensity and mostly spread diffusely over both halves of the cord

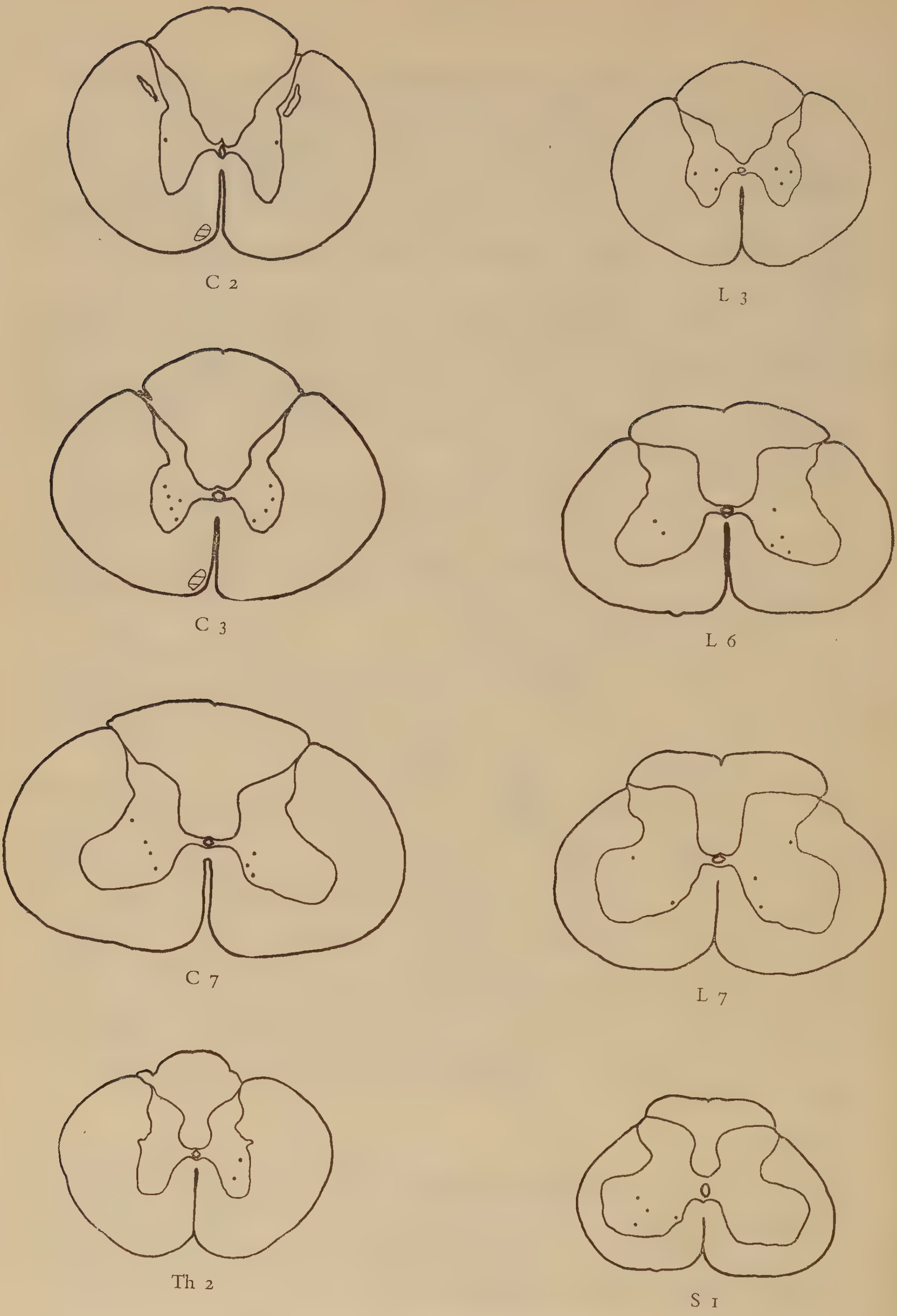

Degeneration in the cord of Cat H 3614.

without much difference between the right and the left side being visible. Affected fibres were not present in the area of decussation; at the levels of the pyramidal decussation degeneration was located in the accessory nerve nucleus. In the cord the localization was as follows:
C 2 segment in lamina 7; C 3 and 7, L 3 and 7 and the first sacral segment in laminae 7 and 8; Th 2 and L 6 segments in lamina 8.
As in the white matter degeneration is restricted to one side, whereas in the grey matter it is found bilaterally, it is justified to conclude that part of the tectospinal fibres or their collaterals cross in the cord. Such crossings, however, could not be demonstrated.

Cat H 4860

In this animal, which was killed ten days after the operation, the descending fibresystem of one superior colliculus has been subtotally severed in the tectum rostral to its crossing.
In the white matter of the cord degeneration is seen in the cervical segments only; it is located in the anteromedial part of the contralateral sulcomarginal zone.
In the C 1 segment the grey matter shows degeneration at one side only, it is of strong to moderate intensity. Degenerated fibres enter the anterior horn at its ventrolateral side and spread to its centre and far into the intermediate grey matter, where the degeneration is most intense. Along the dorsomedial margin of the anterior horn some degeneration only is present. All over the areas of degeneration there are passing disintegrating axons as well as fine preterminalia lying along the ganglioncells. In some preparations degeneration of slight intensity is seen in the other half of the cord; it is located near the central canal and in the dorsomedial part of the anterior horn.
In the C 2 segment at one side the degeneration lies in the lateral half and the centre of the anterior horn, from where it spreads to the intermediate grey matter. It consists chiefly of fine preterminal axons whereas passing disintegrating axons are relatively rare. Pericellular degeneration is seen in the intermediate grey matter (lamina 7). Its intensity everywhere is moderate. At the other side, in several preparations, some degeneration is seen in the dorsomedial and central parts of the anterior horn.

A 4

A 3

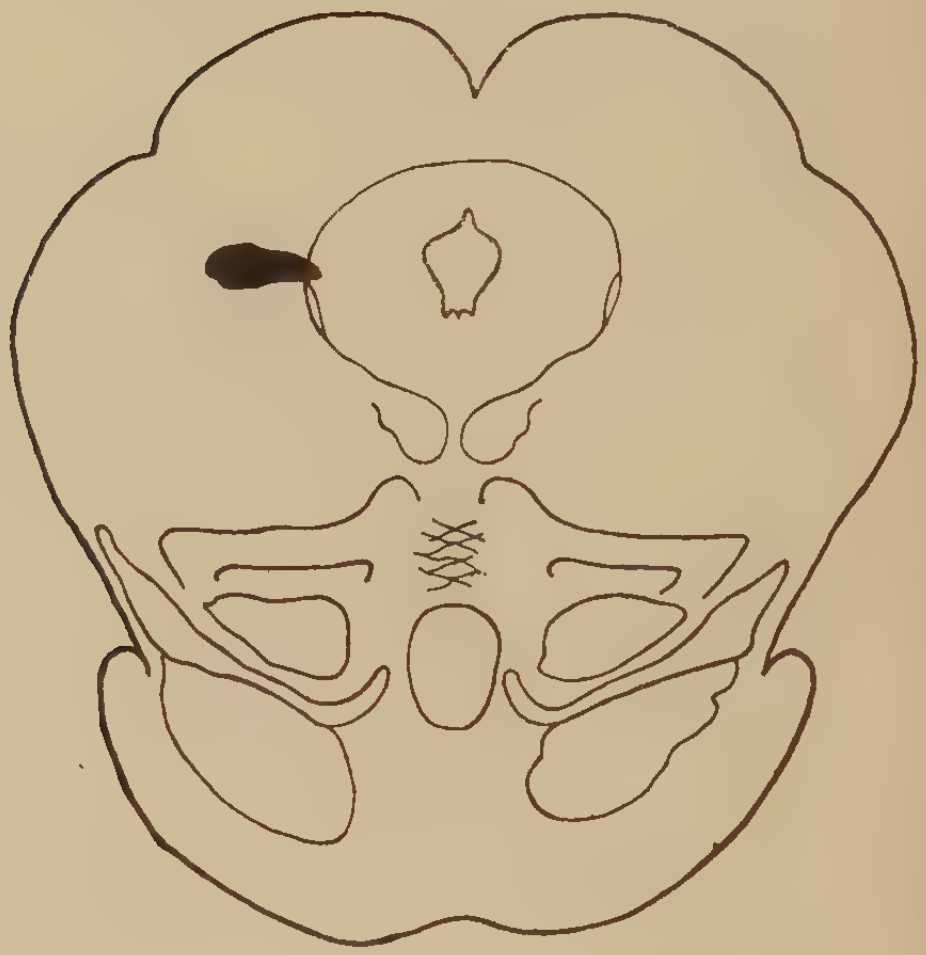

A 2

Lesion in Cat H 4860.

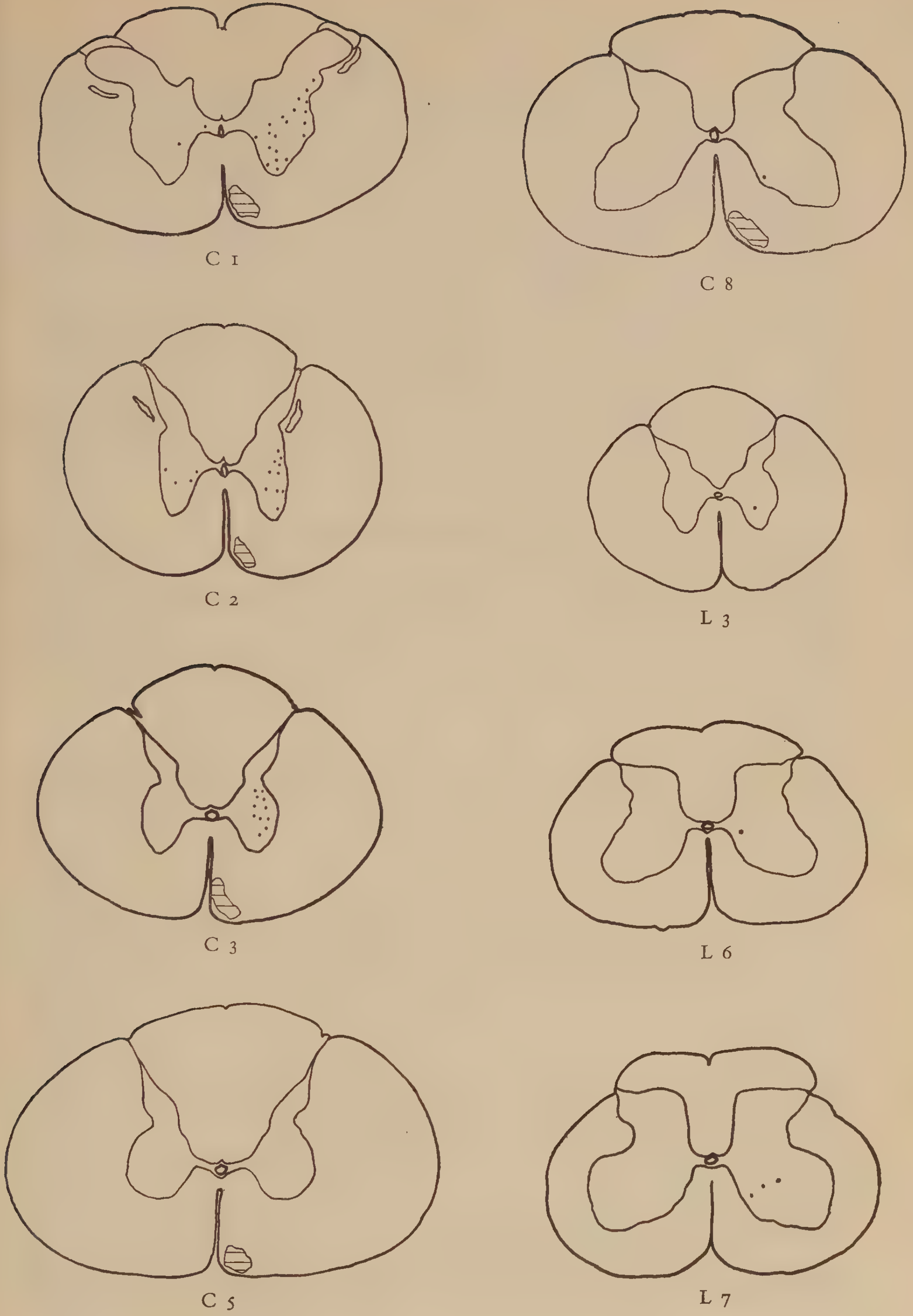

Degeneration in the cord of Cat H 4860.

In the C 3 segment a moderate to strong degree of degeneration is present only unilaterally in the ventrolateral part of the anterior horn, spreading to the intermediate grey matter. Besides fine preterminal axons, there are passing disintegrating axons showing a coarse fragmentation.
C 8 segment. In this segment degeneration is confined to the ventromedial corner of the anterior horn at one side; it is very slight and only in one preparation pericellular degeneration is obvious.
In the thoracic segments degeneration could not be found though a relatively large number of preparations were examined.
The L 3 segment in several preparations at one side of the cord shows some slight degeneration in the dorsal and central parts of the anterior horn. In some of the preparations at the other side a similar degeneration can be seen (not depicted in the scheme).
In the L 7 segment in several preparations degeneration is visible at one side in the medial and the central parts of the anterior horn. In one preparation only, at the other side some degenerated axons are found in the area of decussation and the dorsomedial part of the anterior horn. In the lower segments the findings are too unreliable to be reported.

SUMMARY

In the white matter degenerated fibres were found in the ventral part of the sulcomarginal zone, at the heterolateral side. They were no longer found in the thoracic segments.
In the grey matter the degeneration was most marked in the upper cervical levels; it was localized in the lateroventral part of the anterior horn, from where it spread to the intermediate grey matter, where it was strongest in intensity. In some preparations it spread to the dorsomedial parts of the anterior horn as well. With regard to Rexed's laminae degeneration spread from laminae 8 and 9*a* to the laminae 7, 6 and 5. In the low cervical down to the lower lumbar segments degeneration was seen sporadically in the central or medial parts of the anterior horn. In the segments C 1, 2 and 8 pericellular degeneration was localized in the laminae 7 and 8.
At the other side of the cord degeneration was present in the C 1 and 2 segments and to a lesser degree also in L 3 and 7, localized in the dorsomedial part of the anterior horn near the decussation in the raphe.

These areas belong to lamina 10 and to parts of laminae 7 and 8. Only in the high cervical segments it was more or less marked.

Cat H 4862

In this animal, which was killed ten days after the operation, the praedorsal fascicle was sectioned bilaterally at the P 3 plane.
In the white matter degeneration is distinct only in the cervical segments, it is localized in the ventromedial part of the sulcomarginal zone. Already at the C 3 segment it diminishes much in intensity.
In the C 2 segment at both sides degenerated axons enter the medial anterior horn margin and proceed to the intermediate grey matter. At the left side they are also visible in the lateral part of the anterior horn; everywhere degeneration is of moderate intensity.
In the C 3 segment degeneration within the grey matter is less in intensity, its area of extension is less sharply circumscribed and comprises the centre and the lateral portion of both anterior horns. At the left side it also comprises the intermediate grey matter and encroaches upon the base of the posterior horn.
In the Th 7 segment preparations are unsuccesfully impregnated; they show some degeneration in the centre of the anterior horns.
In the L 6 segment degeneration spreads all over the central and ventral parts of both anterior horns, the intermediate grey matter and at one side the base of the posterior horn. The intensity is somewhat higher at one side than at the other and varies from slight to moderate.
The Sa 3 segment displays some slight degeneration, in the medial and central parts of the anterior horn at one side in all preparations, and at the other side occasionally in the intermediate grey matter.

SUMMARY

In the white matter degeneration was seen bilaterally in the ventral part of the sulcomarginal zone at the upper cervical segments. Unfortunately, no preparations were available of the lower cervical segments whereas in the thoracic segments degeneration was not present. The grey matter exhibited degeneration in the upper and middle cervical segments fanning from laminae 8 and 9a to the laminae 7, 6 and the ventral part of lamina 5. Disintegrating axons entering by the medial anterior horn

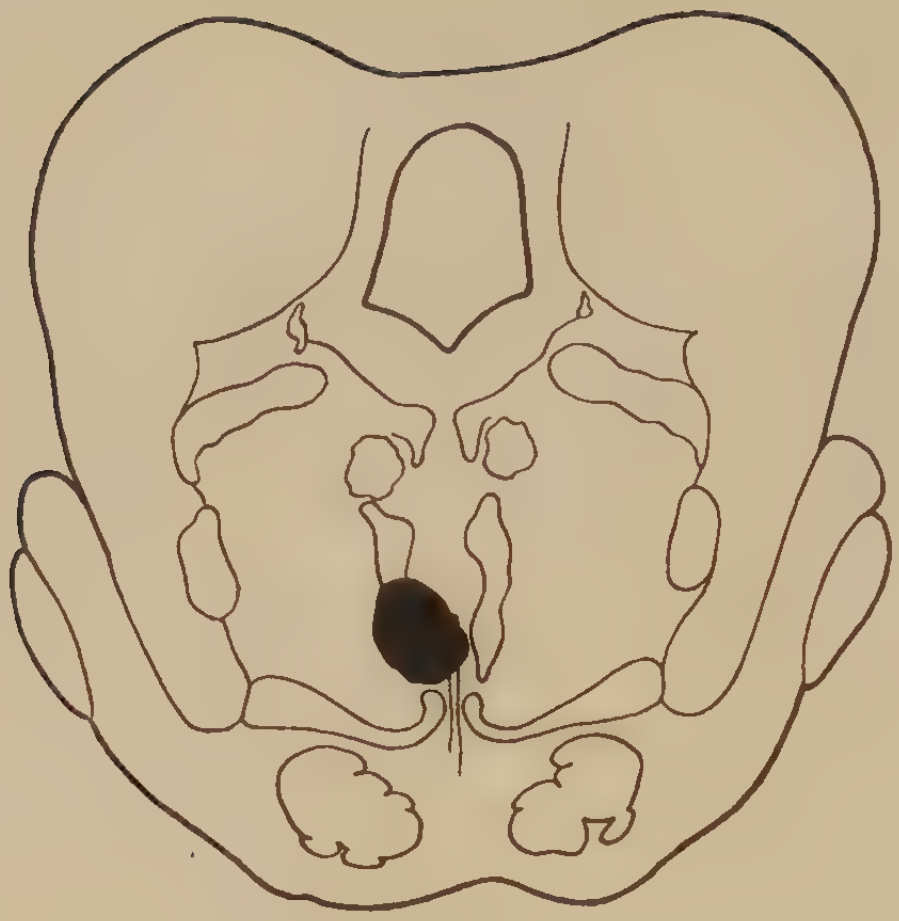

P 1

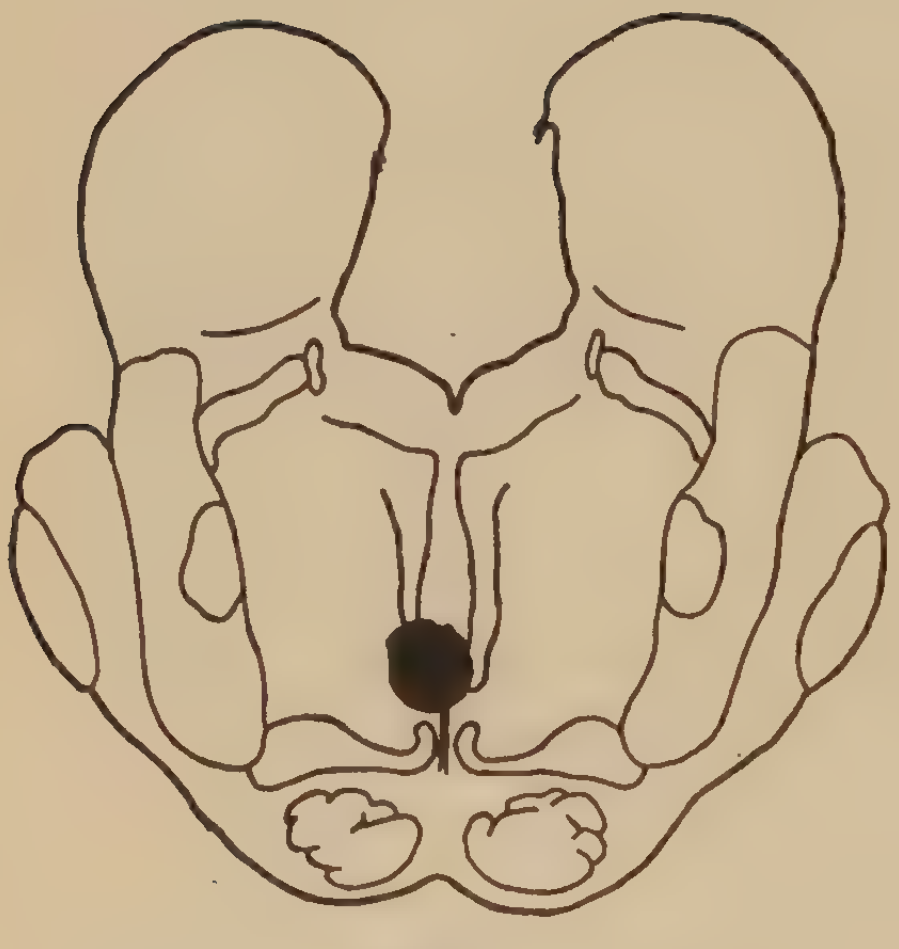

P 2

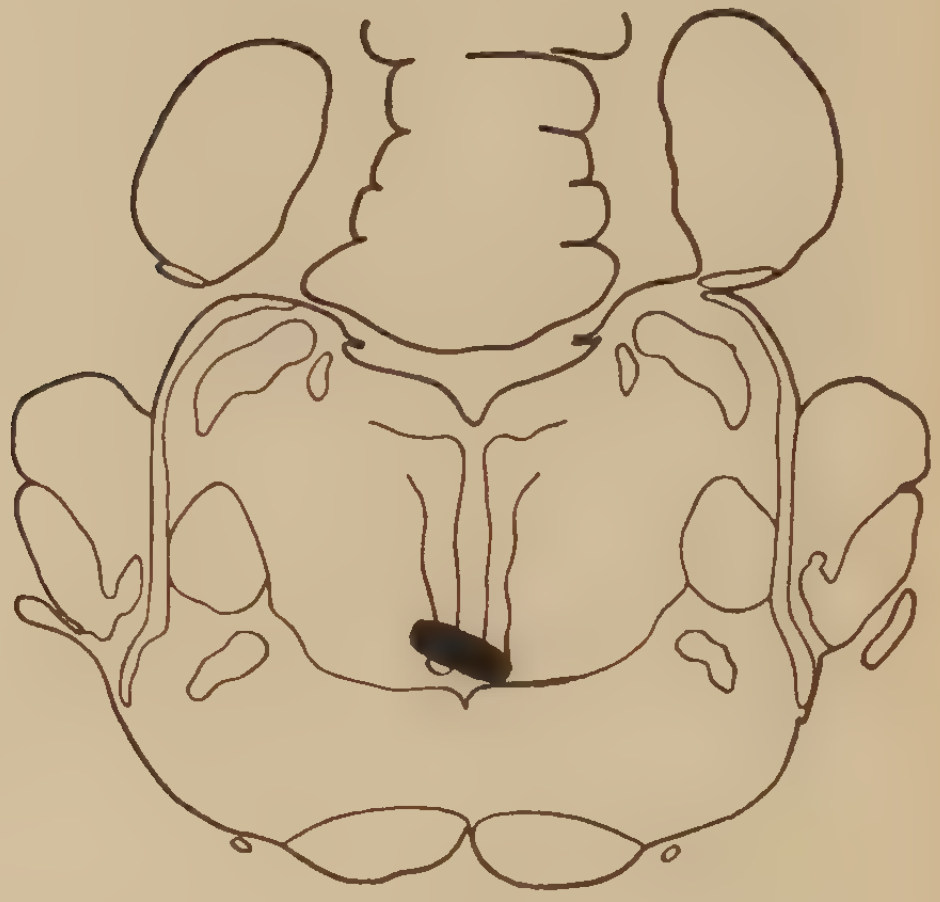

P 3

Lesion in Cat H 4862.

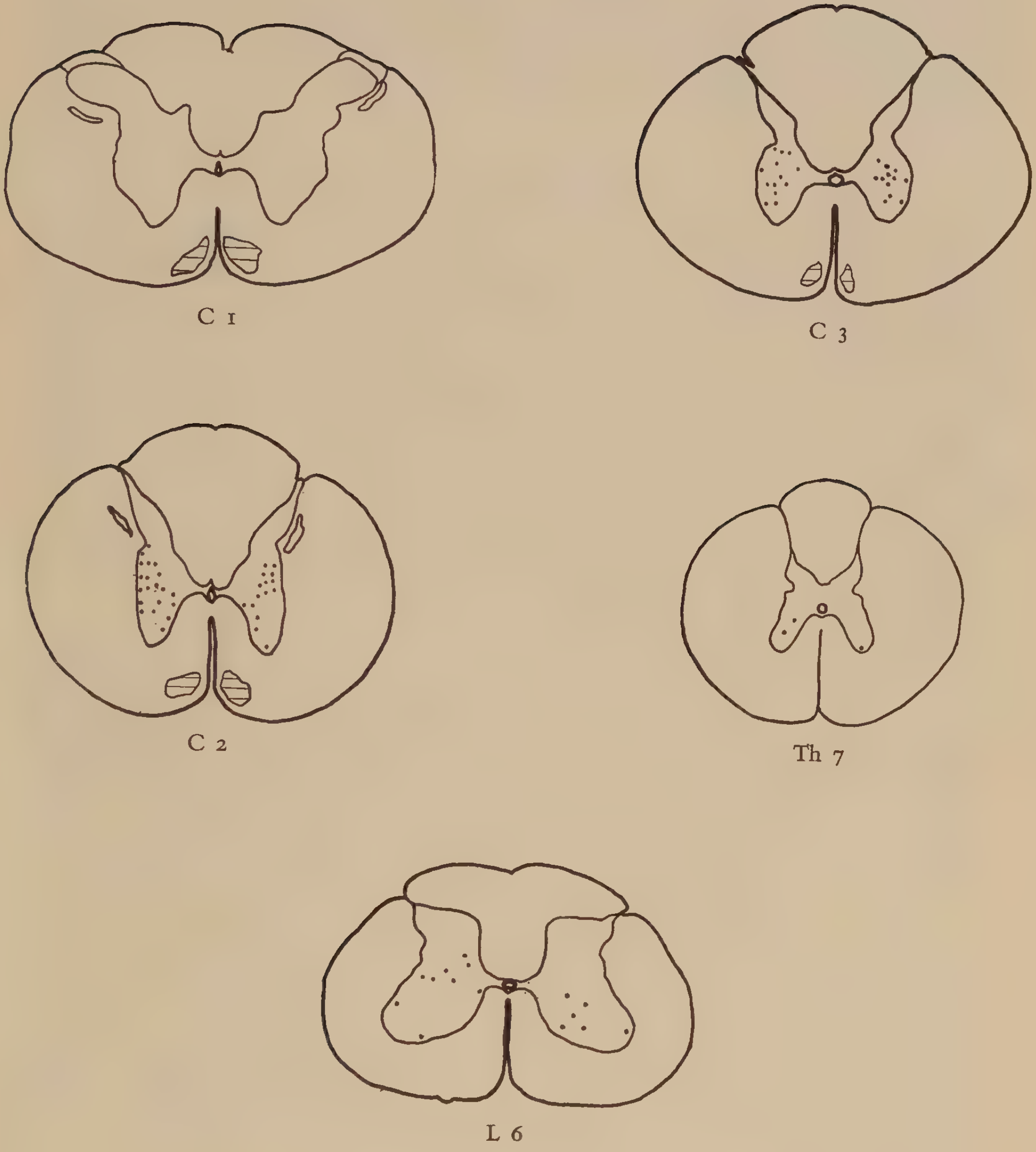

Degeneration in the cord of Cat H 4862.

margin were only seen definitely in the C 2 segment. Within the 7th thoracic segment some very slight degeneration was present in lamina 8, and in the lumbar intumescence a slight to moderate degree of degeneration was found in the laminae 8, 7 and unilateral in 6. Similarly in the third sacral segment some degeneration was present in the laminae 7 and 8.

DISCUSSION

In three animals the fibres from the superior colliculus to the spinal cord were severed (unilat. in cat H 3614, partial in cat H 4860, subtotal, bilat. in cat H 4862). Moreover in 2 cats the tectospinal system was interrupted together with the rubro- and interstitiospinal systems (cat H 3710, sagittal section of the mesencephalon, cat H 3610, electrocoagulation of the red nucleus and some of its vicinity). The last two experiments will be described in the next chapter. In these cats, only the localization of the fibres in the white matter could be studied as in the grey matter preterminals of the other tracts may overlap with those of the system under consideration.

In all of the experiments, either uni- or bilaterally there was an area of degeneration in the ventromedial part of the sulcomarginal zone of the anterior funiculus, near the fissure, which could be followed down to the most caudal cervical or the upper thoracic segments. This is in accordance with the findings reported in the literature as reviewed in this chapter. In the two experimental animals in which the tectospinal system had been selectively and unilaterally severed (H 3614 and 4860), preterminal degeneration in the grey matter of the upper cervical segments could be followed from the laminae 8 and 9a, (spinal accessory nerve nucleus), to lamina 7 and the ventral part of lamina 5. Within the lumbar intumescence preterminal degeneration was found in the laminae 7 and 8, and especially in cat H 4860 pericellular degeneration at the rostral and caudal cervical segments was present in the laminae 7 and 8.

The intensity of the degeneration in the upper cervical segments was moderate to strong; more caudally it was only slight. Some preterminal degeneration homolateral to the lesion was also fairly frequently visible in the grey matter. This might imply, that part of the tectospinal fibres

or their collaterals once more pass the midline before terminating. In cat H 3614 the localization of the preterminal degeneration was about equal at both sides of the cord. In cat H 4860, however, the ipsilateral preterminal degeneration was confined to a small area near the central canal, and the dorsomedial part of the anterior horn. This degeneration can most probably be attributed to axons or collaterals which crossed the midline again. It was most conspicuous in the upper cervical segments. However, within the area of crossing degenerated fibres could not be found.

After bilateral interruption of the tectospinal fibres (H 4862) the features of the degeneration were in accordance with those following unilateral interruption; marked differences between both sides were not found.

Localization of the preterminal degeneration in the upper cervical segments proved to be about identical with that found by Pearce. Similarly, the observations made by Rasmussen and Von Economo are in accordance with those in the present study with regard to the degeneration in the intermediate grey matter and the spinal accessory nerve nucleus. However, degeneration in the medial part of the anterior horn in their animals was much more marked than in those described in this chapter.

Preterminal degeneration, if only of slight intensity, in the lumbar intumescence, and ipsilateral grey matter degeneration have not been reported previously.

CHAPTER V

THE RUBROSPINAL FIBRESYSTEM

REVIEW OF THE LITERATURE

When not stated otherwise, the authors to be mentioned have used the Marchi osmic acid impregnation.

The origin of the rubrospinal fibres

Von Monakow in 1890 following a lesion closely caudal to the inferior colliculus saw an ascending "atrophy" that crossed in the low mesencephalon and could be followed to the ventromedial margin of the contralateral red nucleus. He found this red nucleus to show a marked loss of ganglioncells.

Tschermak (1898) from data in the literature, especially Held's paper of 1893 in which he depicted the rubrospinal fibres in his Golgi preparations without mentioning them, accepted the existence of "das kreuzende absteigende Spinalsystem aus dem rothen Kern der Haube" the crossed descending spinal system from the red nucleus of the tegmentum. Probst in 1899 from a number of partial lesions of the red nucleus in the cat could prove that "das Monakowsche Bündel", Monakow's fascicle, takes its origin from the whole extent of the red nucleus. Collier (1901), in the cat and the monkey, in contrast to Probst, assumed it to arise from the caudal part of the red nucleus only; Lewandowsky, however, agreed with Probst about its origin from the whole extent of the red nucleus.

The course of the rubrospinal fibres

In 1883 Von Monakow following a hemichordotomy at the C 1 segment in a rabbit saw "atrophy" of a bundle in the ipsilateral lateral funiculus of the cord. In 1885 he repeated the same experiment in a cat but he was unable to establish the origin of the fibres. Therefore he called the fascicle involved the "aberrirendes Seitenstrangbündel" the aberrant lateral funiculus bundle.

Probst, in his experiments reported above, saw a number of degenerated

fibres curve round the rostral border of the red nucleus before entering Forel's decussation. Boyce (1896) and Probst were of the opinion that the rubrospinal tract in the medulla is not mixed with ascending fibres; they considered it to consist of coarse fibres that descend in the brain stem along the ventral side of the descending trigeminus ramus.

Redlich (1899) and Probst found the fibres to lay in the dorsolateral funiculus of the cord and Probst could follow them into the sacral segments.

The topographic features in the cord have been elaborately studied in Häggqvist slides in the cat by Verhaart (1955), Van Beusekom (1955), Verhaart and Van Beusekom (1958), and Busch (1961). They agree with the former authors that the rubrospinal fibres cross shortly after originating from the red nucleus, that they descend in the dorsolateral funiculus of the cord, and can be followed in gradually diminishing numbers down to the sacral cord. During the descent they shift somewhat to the periphery of the cord. Mussen (1927), in the cat, accepted a subdivision of the rubrospinal tract and distinguished a special rubrocervical tract originating from the rostral parvocellular part of the red nucleus.

Woodburne (1939) from the study of the normal brainstem of the rat found a lateromedial arrangement of fibres originating from the different parts of the red nucleus. As he had only normal material at his disposal and made no experiments, his opinion seems not fully proved.

Pompeiano and Brodal (1957) point out that somatotopic studies are unreliable when based on lesions in different parts of the red nucleus because such lesions interrupt fibres from other parts of the nucleus as well. They rely only upon study of retrograde neuronal changes after severance of parts of the rubrospinal tract, and made use of a modified Von Gudden method, in their experiments on young kittens. They come to the conclusion that the rubrocervical fibres originate in the dorsal and dorsomedial portions of the caudal three quarters of the nucleus, the rubrolumbar fibres in the corresponding ventral and ventromedial portion, and the rubrothoracic fibres in between.

Walberg (1958), using the Glees method, studied experimental material in the cat and found the fibres from the ventral part of the red nucleus to lie in the ventral part of the tract in the cord also.

Termination of the rubrospinal fibres

Probst (1899) already localized the terminations of the rubrospinal fibres in the anterior horn of the cord. Rothmann (1900), in the dog, could follow the fibres to the intermediate grey matter of the cord, but he could not demonstrate its terminations.

Fraser (1902), in the cat and the monkey, found the fibres to enter the intermediate grey matter and subsequently "... to break up around the anterior horn cells".

Rasdolsky's experiments with regard to the termination of the rubrospinal fibres are equally inconclusive with regard to the tectospinal fibres, as exposed in chapter IV.

Szentágothai-Schimert (1942) was able to destroy the red nucleus in the cat more or less exclusively and he found the fibres in moderate numbers in the low cervical and in much smaller numbers in the high lumbar cord to enter the contralateral grey matter. He saw degenerating terminals around the cells of the nucleus intermediomedialis and the large cells of the centre of the intermediate grey matter. He did not find them in the anterior horn and Clarke's column.

Hinman and Carpenter (1959) made stereotactic lesions in the red nucleus of the cat, but could not avoid damage to the medial longitudinal fascicle, the central grey matter, the oculomotor nucleus and the brachium conjunctivum. These authors used the Nauta-Gygax technique. Therefore it is probable that the terminations found, are not restricted to those of the rubrospinal fibres. The majority of degenerated fibres entered the grey matter in the cervical cord, nevertheless they were still found in the sacral segments. The area of entrance lay at the "reticular process" of the intermediate grey matter, and both dorsal and ventral to it. Severe preterminal degeneration was located in the basal parts of the posterior horn and the intermediate grey matter, but it could be followed into the base of the anterior horn, especially to the cells of the medial column. The lateral part of the anterior horn showed a much smaller number of degenerated fibres. This localization was equal in the cervical-, the thoracic-, and the lumbar segments, with the exception of the base of the posterior horn in the lumbar cord and the addition of Clarke's column in some thoracic segments.

Kuijpers et al (1960) studied preterminal degeneration in Nauta-Gygax stained preparations of the cord of macaca monkeys with large tegmental lesions at the level of the hypoglossus nerve nucleus, with the exception of the pyramid. The degenerated fibres in the lateral funiculus of the cord, which according to the authors are chiefly rubrospinal fibres, proved to terminate in the basal parts of the posterior horn and the intermediate grey matter. This termination was present down to the lumbar segments.

From this review it may be summarized that the fibres under consideration originate in the red nucleus, cross near their level of origin and in the cord travel in the posterolateral funiculus unto the sacral segments. The terminations, except in the investigations with the Marchi-technique, were demonstrated conclusively only by Szentágothai-Schimert in his Bielschowsky impregnated preparations. He found them mostly in the cervical and much less in the lumbar levels within the medial part of the intermediate grey matter and the nucleus intermediomedialis. In the investigations with the modern silver technique, the lesions were unfortunately too large to permit conclusions about the termination of the rubrospinal fibres.

EXPERIMENTS

Cat H 3610

Coagulation of the red nucleus at one side, the most rostral part excepted, with lesion of the crossed rubrospinal fibres ventral to the nucleus, interstitiospinal fibres in the medial longitudinal fascicle by the electrode tract, and tectospinal fibres, rostral to their crossing in the tectum. The animal was killed eighteen days after the operation.

In this experiment overlapping was to be expected of degenerated preterminals in the grey matter of the cord, belonging to crossed rubro- and tectospinal and homolateral rubro- and interstitiospinal fibres, which, however, in the lumbar segments will be inconspicuous because the tecto- and interstitiospinal fibres were very rare in this part of the cord.

1

2

3

4

Lesion in Cat H 3610. In this animal the lesion was made with two electrodes, which were introduced in the red nucleus at the planes A 4 and A 6, (cat M 4 of Busch, 1961).

Degeneration in the cord:

C 1 segment. In the posterolateral funiculus of both sides degeneration is marked, though not equal in intensity. At the side of the lesser intensity some degeneration is seen in the sulcomarginal zone near the fissura mediana anterior, at the other side it is found more ventrally, in the same zone.

C 2 segment. The degeneration in the white matter is unchanged. At the side of the more severe degeneration in the white matter, the intermediate grey matter shows a moderate to strong degree of degeneration, from which degenerated axons spread fanlike to the base of the posterior horn and the dorsal part of the central grey matter. At the other side the degeneration in the intermediate grey matter is much less intense and the affected fibres can be followed much less far centrally, whereas to the base of the posterior horn degenerated axons proceed in moderate numbers.

At both sides some degeneration is visible along the medial margin of the anterior horn.

C 3 segment. In the white matter the anterior funiculus degeneration is much less marked at the side of stronger degeneration in the posterolateral funiculus. The grey matter degeneration is about equal to that in the C 2 segment.

C 7 segment. In the white matter the degeneration of the sulcomarginal zone is confined to the side of less intense degeneration of the posterolateral funiculus.

C 8 to Th 1 segment. At one side the degeneration in the intermediate grey matter is strong; it can be followed into the base of the posterior horn where it shows with a moderate intensity and to the central grey matter with a slight to moderate intensity. At the other side there is only some very slight degeneration in the intermediate grey matter and some slight degeneration along the dorsal part of the medial anterior horn margin and near the central canal.

Upper thoracic segments. In the grey matter at one side a moderate degree of degeneration is seen in the intermediate grey matter, extending somewhat centrally, encroaching upon the central grey matter. At the other side the degeneration is only slight in intensity and shows the

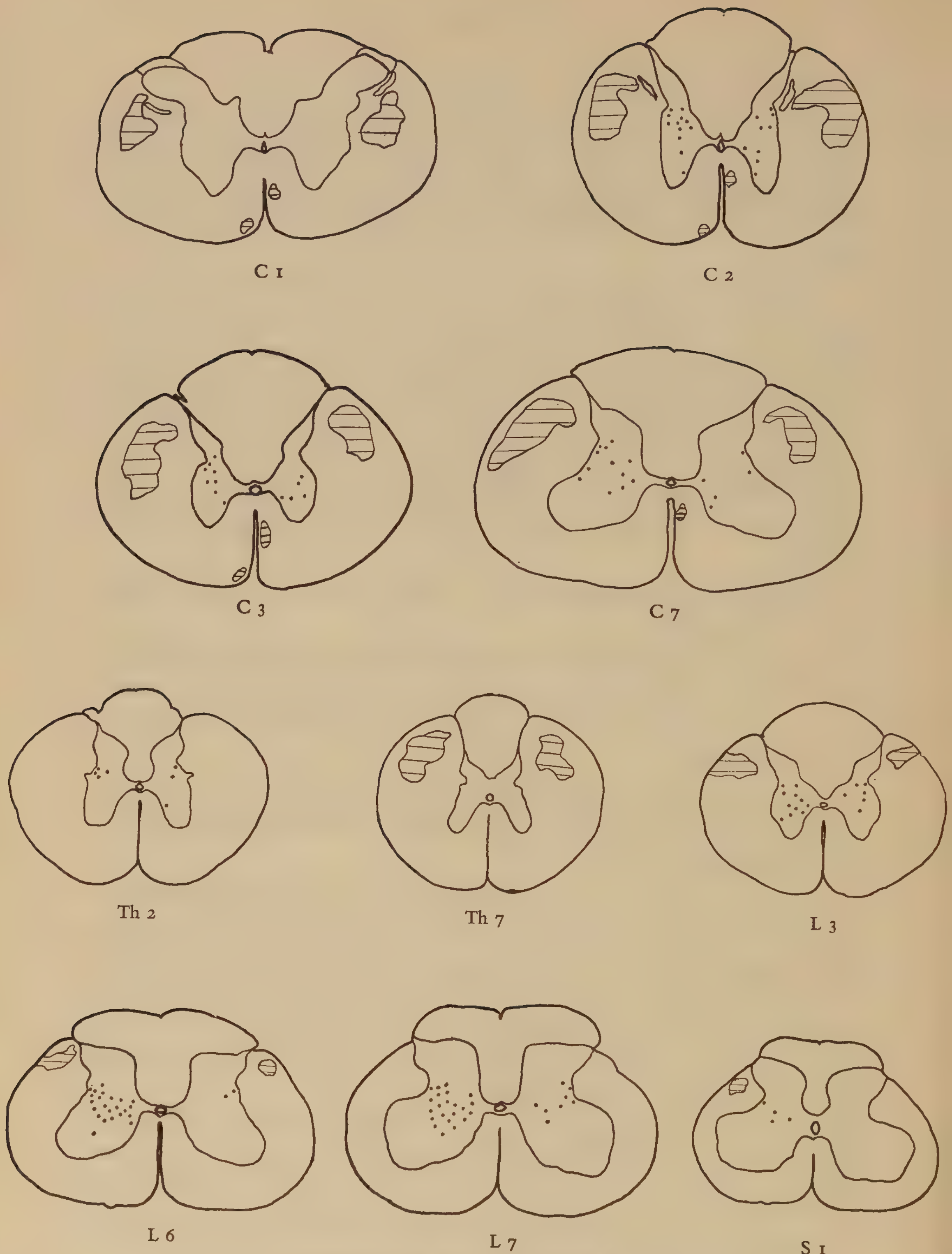

Degeneration in the cord of Cat H 3610

same localization. Pericellular degeneration is seen at the first mentioned side in Rexed's 7th lamina.

Degeneration along the medial anterior horn margin is becoming very slight.

Th 7 segment. The degeneration in both posterolateral funiculi is still marked, though not equal in intensity. In the sulcomarginal zones degeneration is no longer seen and therefore more caudally the degeneration may be attributed to the rubrospinal system mostly.

L 1 segment. No changes when compared to Th 7.

L 3 segment. Degeneration in the posterolateral funiculus at both sides has shifted somewhat to the periphery.

In the grey matter at one side it is strong in the intermediate grey matter, and it irradiates over the grey matter to the base of the posterior horn, the central part of the intermediate grey matter and the dorsomedial part of the anterior horn. At the other side degeneration is slight to moderate, it irradiates to the central part of the intermediate grey matter and the dorsomedial part of the anterior horn.

The L 5 segment. In the white matter the area of degeneration has diminished in size bilaterally; at the left side it is still more conspicuous than at the other side. It lies somewhat more peripheral than in the previous level.

At the side of the stronger degeneration in the grey matter, degeneration is equal to that in the L 3 level; pericellular degeneration is seen all over the area. At the other side degeneration is only sporadic and restricted to the intermediate grey matter.

The L 6 segment. In the white matter no changes are apparent. Impregnation at this level has been very successful and shows magnificent preterminal degeneration. At the side of stronger degeneration a severe degeneration is found in the intermediate grey matter from where it radiates to the base of the posterior horn, to the central grey matter, and the dorsal part of the anterior horn.

In the ventral part of the anterior horn only some slight degeneration is distinguishable. At the other side some very slight degeneration is visible in the intermediate grey matter.

The L 7 segment shows the degeneration at the side of the weaker intensity somewhat more distinctly, it irradiates from the intermediate

grey matter to the central grey matter and the base of the posterior horn.

The Sa 1 segment. Within the white matter, only at one side some degeneration is present in the posterolateral funiculus. Within the grey matter at the left side the intermediate grey matter contains degenerated fibres that run out to the central grey matter but not to the dorsomedial part of the anterior horn. At the other side only in one preparation some slight degeneration is found in the intermediate grey matter.

The Sa 3 segment. Bilaterally there is some degeneration present in the intermediate grey matter, and at the left side some in the central grey matter near the intermediate one.

The Co segments. Only at one side in the white matter a few degenerated fibres are present in the dorsolateral funiculus, whereas the grey matter is totally devoid of degeneration (Sa 3 and Co degeneration was not depicted in the scheme).

SUMMARY

White matter degeneration was found to decrease caudally in both dorsolateral funiculi down to the upper sacral segments; at the left side it was more severe than at the right.

In the lumbar segments it shifted somewhat peripherally and in the sacral segments it was present only at one side. Besides this, some degeneration was present at the right side of the cervical cord in the dorsal part of the sulcomarginal zone, and at the left side in its ventral part. The grey matter displayed degeneration in Rexed's laminae 5, 6, 7 and 8; but in the upper thoracic segments only in the laminae 5 and 7 and in the sacral segments in the laminae 6 and 7.

At all levels, within the areas of degeneration, preterminals were present, whereas in the intermediate grey matter disintegrating passing axons were prevalent.

As already pointed out, from the absence of interstitial and tectal fibres-degeneration below the low cervical levels it was concluded that from this level caudally, the degeneration consisted mostly of severed rubro-spinal fibres.

Cat H 3710

In this animal the mesencephalon was sectioned parasagittaly from the thalamus to the level of Forel's decussation, the section lying in close proximity of the midline. The animal was killed eighteen days after the operation.
On microscopic examination of the mesencephalon and the upper pons it appeared that the rubro-and the tectospinal systems had been interrupted totally at both sides, and the interstitiospinal system at the side of the section.

In the white matter degeneration in the dorsolateral funiculus of the cord is equal at both sides and resembles much that is seen at the left side of the previous animal. Tecto- and interstitiospinal fibre-degeneration can be seen in the areas of the sulcomarginal zone as described in the chapters concerned with these fibre systems.
The C 2 segment displays bilateral degeneration of equal intensity, which should be qualified as severe; in the intermediate grey matter the degeneration fans out to the base of the posterior horn, the central part of the intermediate grey matter and ventromedially to the anterior horn. Besides this along the medial margins of the anterior horns degenerated fibres enter it as well; its ventrolateral part, however, is free from degeneration. Lamina 6 of Rexed at both sides exhibits pericellular degeneration.
The C 7 segment similarly in the grey matter displays a severe bilateral degeneration entering the intermediate grey matter and fanning out to the base of the posterior horn and to the central grey matter and the dorsolateral parts of the anterior horn.
Along the medial margin of the anterior horns moderate numbers of degenerated axons enter the anterior horn at both sides of the cord.
In the thoracic segments only a moderate degree of degeneration is present in the intermediate grey matter; at the left side some slight degeneration is present in the dorsal part of the medial anterior horn margin.
In the L 2 segment the already well-known spreading of degeneration from the intermediate grey matter to the base of the posterior horn and the dorsal part of the medial anterior horn margin is seen. The central



1

2

3

Lesion in Cat H 3710. This lesion was not made by electro-coagulation but was performed by a longitudinal incision along the midline of the mesencephalon. It proved to extend from the level of the mamillary bodies to the rostral border of the pons, (cat M 8 of Busch, 1961).

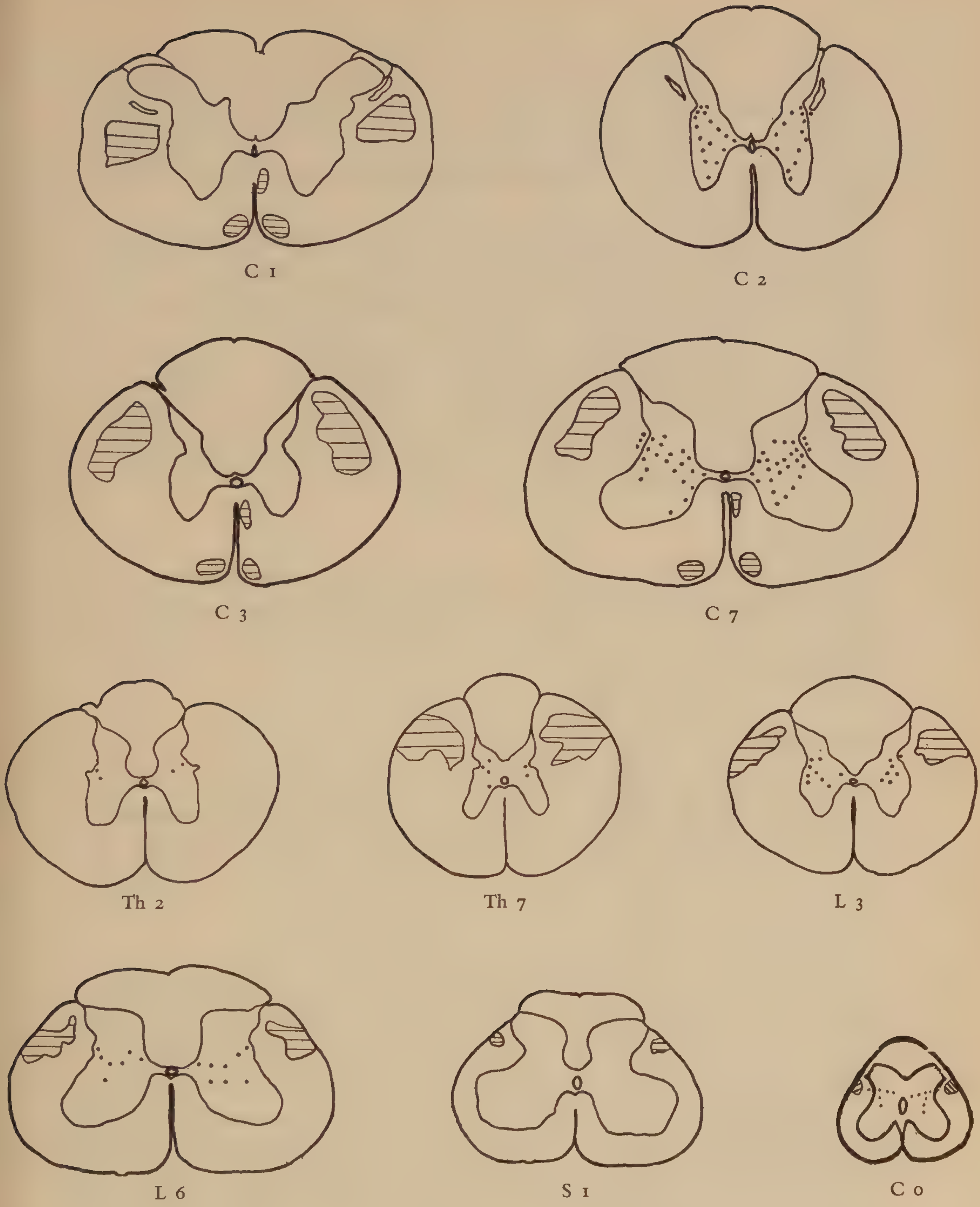

Degeneration in the cord of Cat H 3710.

grey matter is mostly free from degeneration. Possibly the degeneration at one side is somewhat more extensive than at the other, at both sides it is moderate in intensity. In the L 3 segment the extension of the degeneration is equal to that in the previous level; it is somewhat increased in intensity.

In the L 6 segment the intensity of the degeneration has decreased considerably, its extension is equal, and there is no difference between both sides. The central parts of the intermediate grey matter are somewhat more involved than those at the previous level.

At the Co segments the degeneration is still slight to moderate in intensity at both sides. It fans out from the intermediate grey matter to the central grey matter in the vicinity of the central canal and the dorsal part of the lateral half of the anterior horn.

SUMMARY

The degeneration in the white matter was essentially the same as in the previous animal. In the grey matter the degeneration fanning out from the intermediate grey matter likewise showed an extension comparable to that in the previous cat.

Cat H 4864

In this animal the rubrospinal tract was partly severed unilaterally at the level of the motor trigeminal nucleus. No other descending systems to the spinal cord were damaged. The animal was killed ten days after the operation.

Degeneration in the cord:

In the C 1 and C 2 segment at the side of the lesion an area of degeneration in the white matter is found in the posterolateral funiculus. In the C 2 segment in the intermediate grey matter at one side a moderate degree of degeneration is found, in which pericellular degeneration can be distinguished. From the intermediate grey matter it can be followed somewhat medioventrally as well as to the base of the posterior horn. Ventrally it does not get beyond the level of the central canal, and both the central grey matter and the medial part of the anterior horn are free from degeneration.

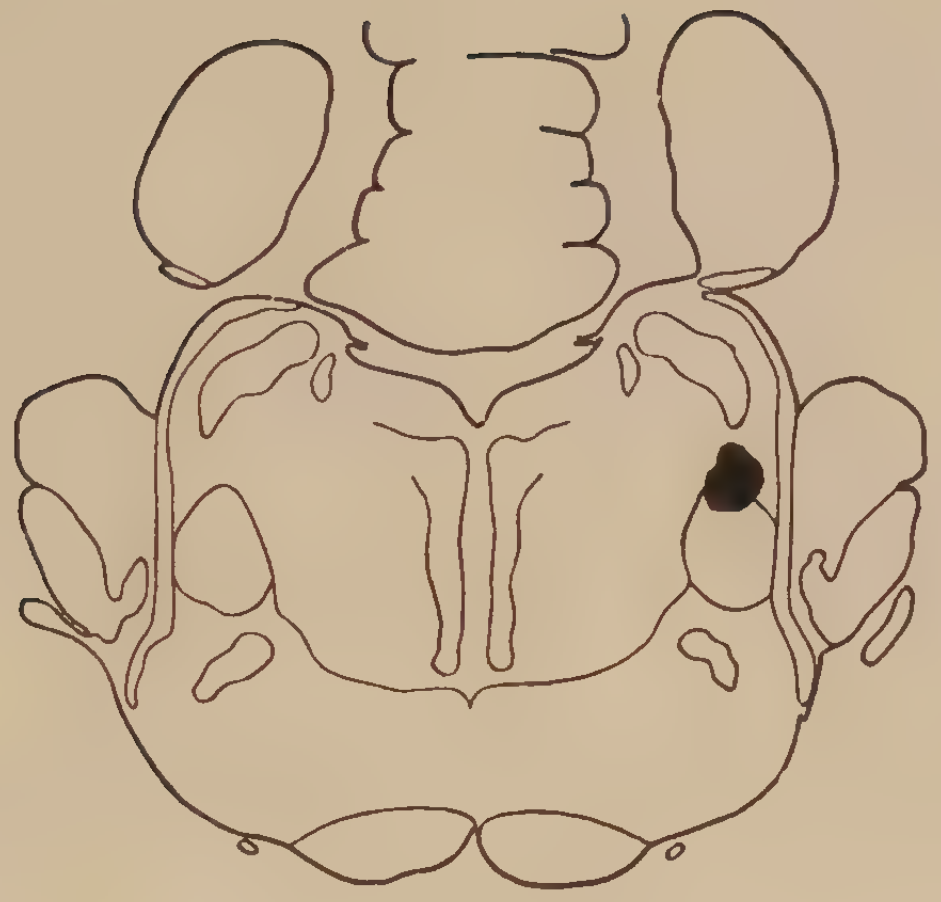

P 3

P 4

Lesion in Cat H 4864.

In the C 5 and 8 segments the degeneration in the white matter has not changed appreciably. In the intermediate grey matter some slight degeneration is visible.
In the Th 2 segment the degeneration in the white matter has diminished somewhat in quantity; it occupies the same site as in the higher segments. In the intermediate grey matter some degeneration is visible.
The L 3 segment similarly shows some degeneration in the intermediate grey matter, varying in intensity from slight to moderate.
In the L 6 segment the degeneration in the grey matter is somewhat more marked, it is located in the intermediate grey matter and extends somewhat medially.
In the Sa segments the white matter degeneration is no longer found, whereas in the intermediate grey matter there is still some of slight intensity.

SUMMARY

In the white matter in the preparations available degeneration was visible in the posterolateral funiculus down to the seventh thoracic segment.
In the grey matter it was localized in the laminae 5, 6 and 7. At the different levels its site was as follows:
C 2 segment, in the laminae 5, 6 and 7; in the C 5 segment in lamina 6.
L3 and L6 segment, at the border of the laminae 5 and 6.
In the Sa segments at the border of the laminae 6 and 7.
Compared to the animals in which the system was totally interrupted, the degeneration was less in intensity.
At the high cervical segments preterminal degeneration was more widely spread than at the other segments; it was also somewhat more intense than in the lumbar segments.

Cat H 3856

In this animal the rubrospinal system was interrupted caudal of its decussation; no other descending system was severed or damaged. The ventrolateral part of the main sensory nucleus was included in this lesion, which medially extends into the masticator nucleus and ventrally into the dorsomedial tip of the rubrospinal tract. Rostrally it comprises

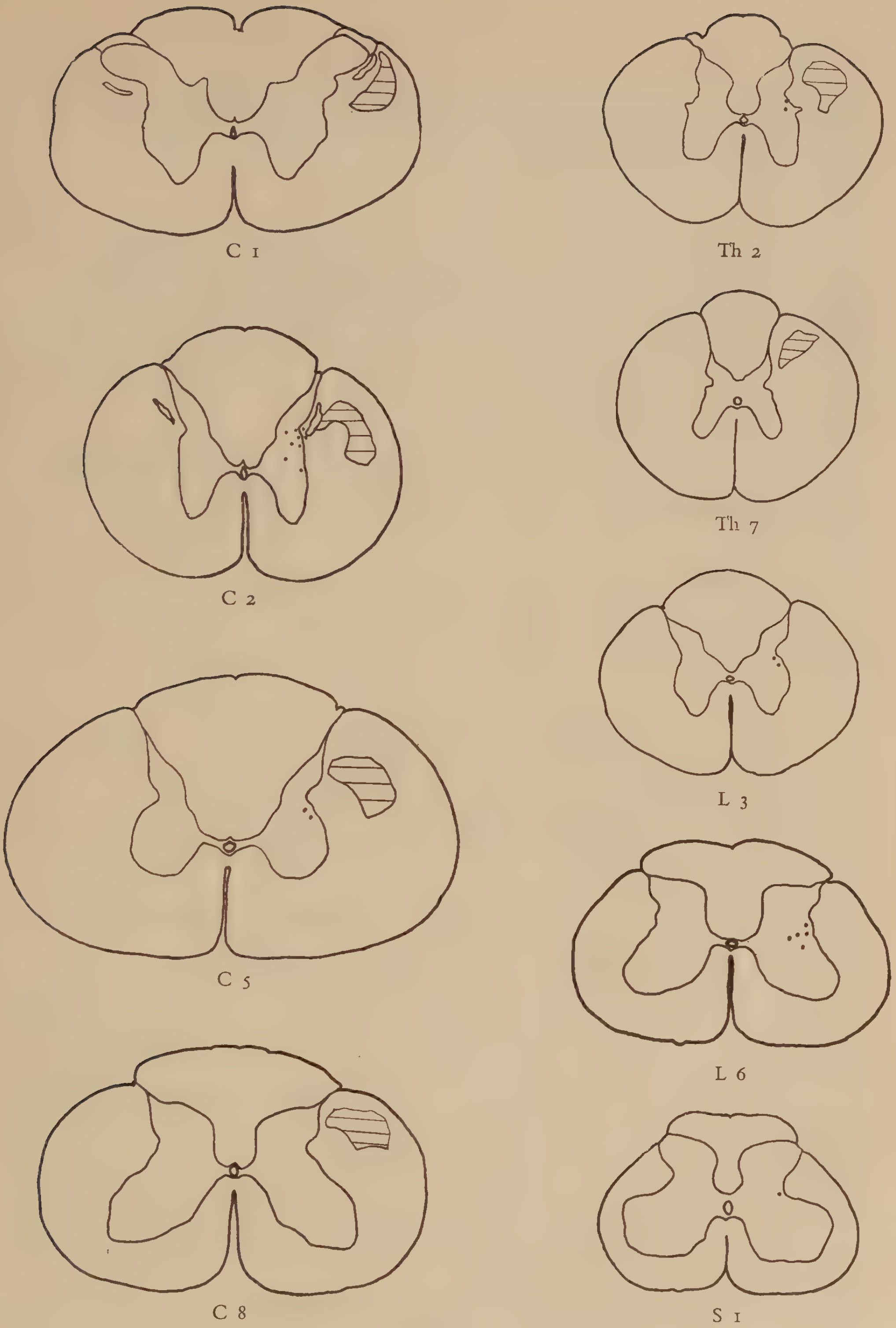

Degeneration in the cord of Cat H 4864.

the ventralmost part of the brachium conjunctivum and a small part of the lateral lemniscus (Cat P 4 of Busch). The animal was killed eleven days after the operation.

In the C 3 segment there is a strong degeneration in the dorsolateral funiculus at one side. At the same side the intermediate grey matter shows a strong degeneration, affected fibres spread from it to the medial part of the intermediate grey matter, the base of the posterior horn, and to the mediodorsal part of the anterior horn. Within lamina 6 pericellular degeneration is evident.
The intensity is strong to moderate. Nowhere in the cord is degeneration visible around the central canal and in the contralateral half of the grey matter.
In the C 7 segment the degeneration within the white matter has not changed, the grey matter degeneration shows the same localization as in the C 3 segment, but it is less in intensity, whereas the mediodorsal part of the anterior horn exhibits pericellular degeneration.
In the upper thoracic segments degeneration is present in the intermediate grey matter and the central part of the anterior horn; pericellular degeneration is found in the lamina 7. The intensity varies from slight to moderate. In the lower thoracic segments the degenerated fibres in the white matter have decreased in quantity; in the grey matter no change can be seen.
In the L 2 segment degenerated fibres in the white matter have shifted somewhat to the periphery of the posterolateral funiculus.
In the L 3 segment degenerated axons entering the intermediate grey matter fan out in a ventromedial direction and can be followed to the dorsomedial part of the anterior horn. Besides this some degeneration is seen along the lateral anterior horn margin, whereas pericellular degeneration occurs in the ventral part of the anterior horn. The intensity of the degeneration is slight to moderate.
In the L 6 segment besides the degeneration of the grey matter described above, some degeneration occurs in the base of the posterior horn; it is moderate to strong in intensity.
In the L 7 segment a tiny area of degenerated fibres lies at the periphery

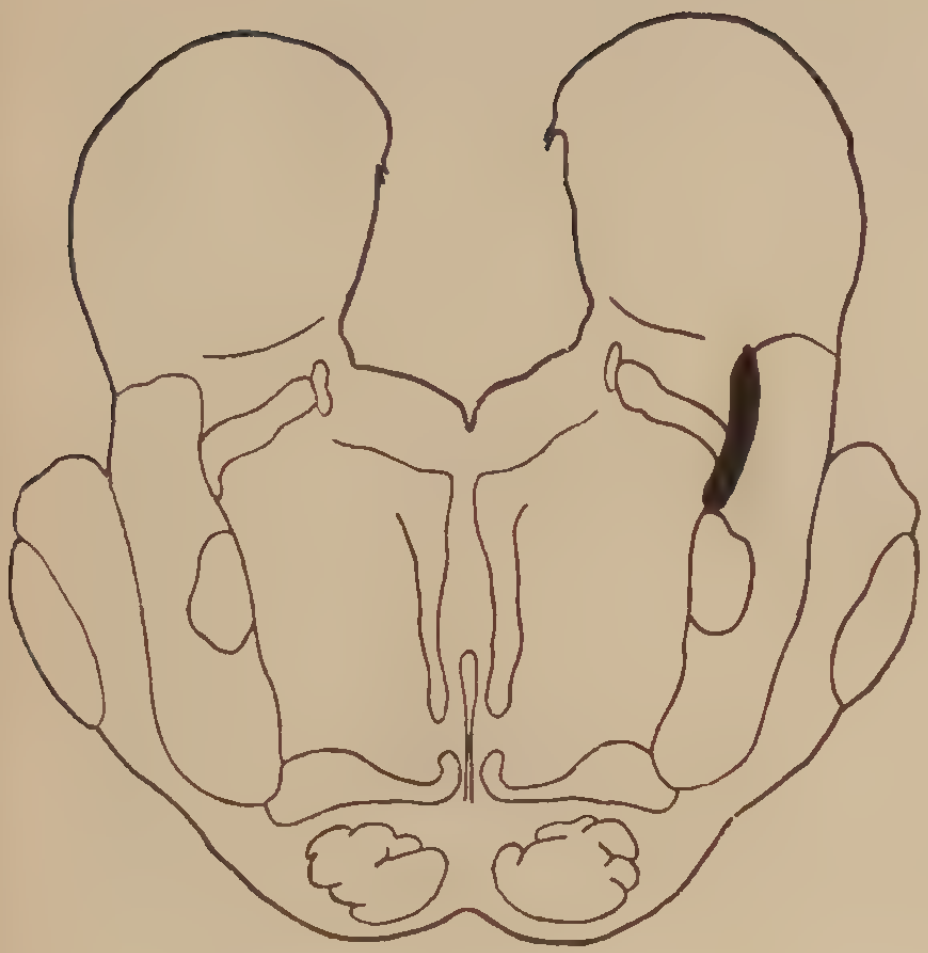

P 2

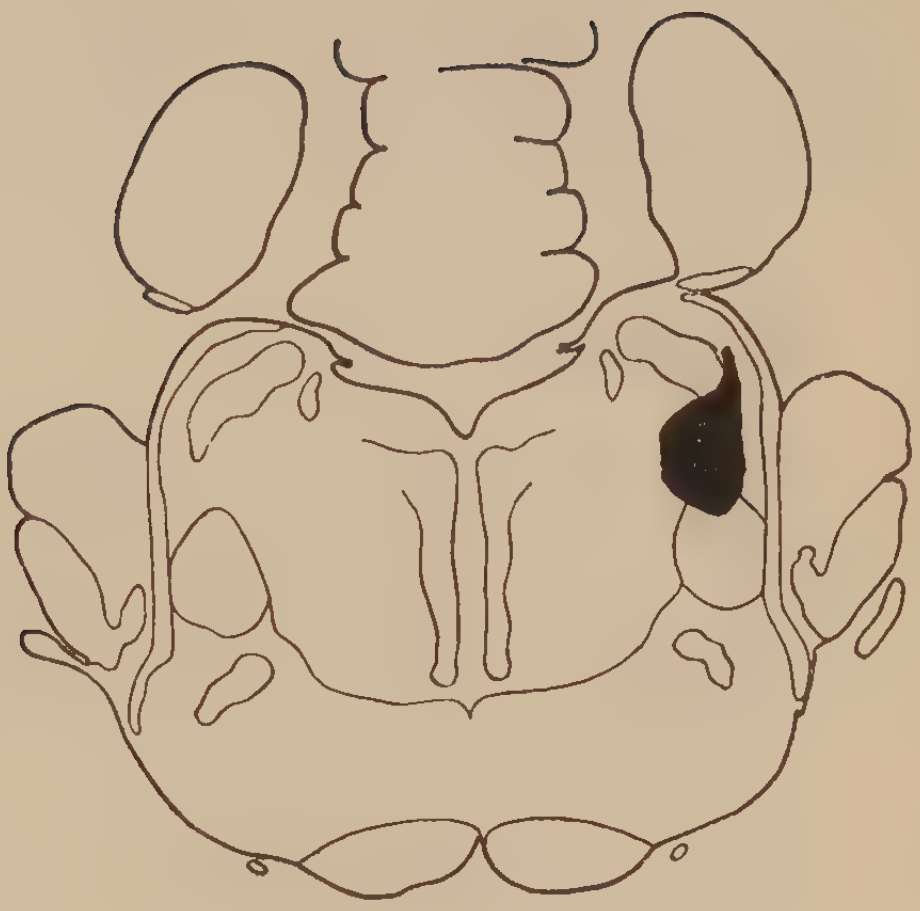

P 3

P 4

Lesion in Cat H 3856.

of the posterolateral funiculus. Degenerated axons entering the intermediate grey matter fan out to the base of the posterior horn and the central part of the anterior horn. The intensity of the degeneration is moderate. The sacral and coccygeal segments were not available for examination.

SUMMARY

In the white matter at all levels a unilateral area of degeneration was found in the dorsolateral funiculus; caudally it decreased in size and shifted somewhat to the periphery.
Similarly, in the grey matter the degeneration was confined to one side; over the whole lenght of the cord the near vicinity of the central canal and Clarke's column were free from it. The intensity of the degeneration was slight to moderate and only occasionally strong, decreasing towards the anterior horn.
According to Rexed's scheme the preterminal degeneration occurred in the cervical and lumbar levels within the laminae 5, 6, 7 and 8, in the thoracic levels within the laminae 5 and 7.

DISCUSSION

The rubrospinal tract was more or less completely severed in two experiments: in one in the mesencephalon near the lateral lemniscus and in the other at the level of the motor trigeminal nucleus (H 3856 and 4864). In two other experiments the rubrospinal system was severed bilaterally but the interstitio- and tectospinal systems were simultaneously severed, in one only very partially (H 3610) in the other more or less completely (H 3710).
The degenerated fibres in the white matter of the spinal cord in all of the cases were localized in the posterolateral funiculus, caudally they shifted somewhat to the periphery, and degenerated fibres could be followed into the sacro-coccygeal transitional segments. Preterminal degeneration in the grey matter was found exclusively contralateral to the nucleus of origin, it was located in Rexed's laminae 5, 6, 7 and 8. At cervical levels in Cat H 3610 preterminal degeneration in lamina 8 may have to be attributed to the interstitial and tectal fibres as well, and

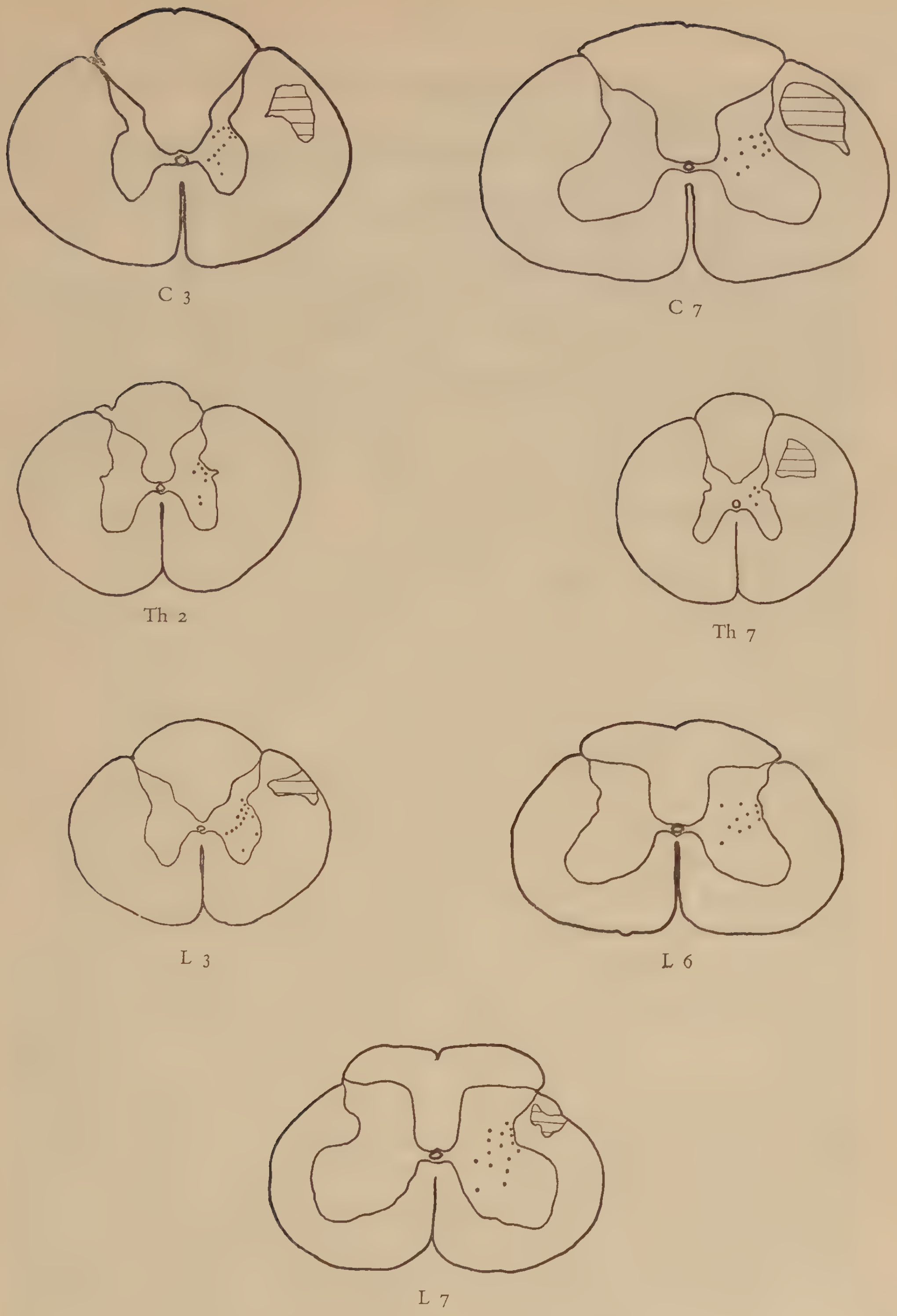

Degeneration in the cord of Cat H 3856.

from cat H 3710 information about the localization in the white matter only could be obtained.
In cat H 4864 in which the dorsomedial part of the rubrospinal fibres was severed, preterminal degeneration was most marked in upper cervical segments. One experiment only, however, does not allow conclusions about the lamination of the rubrospinal tract.

In comparison to the data from the literature it has to be emphasized that preterminal degeneration in the nucleus intermediomedialis was not found, contrary to the opinion of Szentágothai-Schimert. Neither was it found in Clarke's column as reported by Hinman and Carpenter (1959). In this last study, however, as already alluded to, the lesions were less selective with regard to the rubrospinal fibresystem than in the present experiments.

CHAPTER VI

THE VESTIBULOSPINAL FIBRESYSTEMS

REVIEW OF THE LITERATURE

Similar to the previous chapters, when not especially mentioned, the method used is that of Marchi.

I. *Vestibulo-spinal fibres travelling in the medial longitudinal fascicle and in the sulcomarginal fascicle of the cord*

Origin and course

Russell in 1897 after lesion of the area of Deiters' nucleus in macaca and the dog, found a bilateral strong degeneration in the sulcomarginal zone at both sides of the fissura mediana anterior. He could not trace this degeneration beyond the thoracic segments. Probst in 1899 found exactly the same in the cat and the dog. Contrarily, Thomas in 1897 after a similar lesion in the dog, in the anterior funiculus of the cord found ipsilateral degeneration only. Apparently in most of these cases also other vestibular nuclei were damaged besides Deiters' nucleus. Van Gehuchten in 1904 experimented with rabbits but from his descriptions it is not clear which vestibular nuclei were involved in his lesions. He described degenerating fibres in the contralateral anterior funiculus of the cord, lying along the ventral half of the fissure, which he could follow to a midcervical level. At the ipsilateral side in a high cervical level he found degenerating fibres along the anterior white commissure and near the medial margin of the anterior horn; the latter fibres lying lateral to the crossed fibres within the sulco-marginal fascicle.

Lewandowsky in 1904, in the cat and the dog, found in the first cervical segment uncrossed vestibular fibres lying in the anterior funiculus along the anterior horn. They surrounded the anterior horn, almost from the anterior commissure onwards and nearly reached the area of the fibres from Deiters' nucleus at the transition of the anterior and the anterolateral funiculus. He also found crossed fibres in the sulcomarginal zone, but he gave them an other site than Van Gehuchten did.

Van der Schueren in 1912 came to the conclusion that in the rabbit fibres arise from the ventral part of the triangular nucleus and from the whole descendens nucleus, which descend in the sulcomarginal fascicle at both sides of the cord. Besides the Marchi method he also made use of Van Guddens' retrograde neuronal degeneration technique.
Yoshida in 1924 came to the same conclusion as to the crossed vestibular fibres in the rabbit. He found retrograde neuronal degeneration in the triangular nucleus and the most ventral portion of the nucleus descendens following a lesion at the first cervical segment. Muskens (1914), in the cat, found crossed fibres to be derived exclusively from the triangular nucleus and not from Deiters' nucleus. Uncrossed fibres he described originating from the triangular and Bechterew's nuclei, the latter mixing partly with those from Deiters' nucleus although the majority of the latter lies dorsolateral to them.
Van Gehuchten in 1927 could not find crossed fibres in the sulcomarginal fascicle after lesion of Deiters' nucleus, only a few uncrossed ones being visible.
Buchanan in 1937 in the cat found crossed fibres from the medial (triangular) nucleus, which he could follow to the thoracic cord, and from Deiters' and the descendens nucleus, which however apparently did not descend beyond the cervical segments. Unfortunately, the exact localization of these fibres is not mentioned. Uncrossed fibres from the nucleus medialis he could follow into the thoracic segments, from Deiters' nucleus all down the spinal cord and from the descendens nucleus only in the cervical segments, all of them located in the dorsal- and the lateral parts of the sulcomarginal fascicle.
Ferraro in 1940 gave an elaborate description of the vestibulospinal fibresystem in macaca, which proved to consist of both direct and crossed fibres. The crossed fibres originate from the rostral part of the medial nucleus, in the cervical segments they lie along the medial side of the anterior horn. Caudally, they shift medially to the sulcomarginal fascicle and the majority terminated in the cervical segments. The direct uncrossed fibres, according to Ferraro, in the high cervical cord lie in the centre of the anterior funiculus; they are thinly myelinated. Some can be followed to a high thoracic level, where they lie in the dorsomedial tip of the sulcomarginal fascicle.

Pompeiano, although he could not find any retrograde neuronal degeneration in the nucleus medianus and descendens cells after an anterolateral chordotomy, still came to the conclusion that possibly these nuclei send fibres in the cord by way of the sulcomarginal fascicle. He was of the opinion that the technique used did not preclude this (1957).
Busch (1961), in the cat, with Häggqvist stained series came to the conclusion that besides the tract from Deiters' nucleus which he calls the LATERAL VESTIBULOSPINAL TRACT, there are a small UNCROSSED MEDIAL VESTIBULOSPINAL TRACT lying at the medial side of the anterior horn and a larger CROSSED VESTIBULOSPINAL TRACT lying in the medial parts of the anterior funiculus. He did not study them caudally beyond the first cervical segment. In the present study the terminology as used by Busch will be employed.

Termination of the vestibulospinal fibres

Rasdolsky (1923) gave his opinion about the termination of the vestibulospinal fibres in the grey matter of the cord, together with that of the other extraspinally originating fibresystems. However these conclusions alike are based on highly unspecific lesions. Gray (1926), in the cat, stated that severance of fibres from the nucleus descendens, caused degeneration in the contralateral anterior horn all over the cord. His lesions however cannot be considered as restricted to this nucleus. Szentágothai-Schimert (1938, 1942) studied the cord of the cat in vestibular nuclei lesions with Gross' modification of Bielschowsky's technique. Unfortunately the lesions are not described in detail and it is not clear either which vestibular nucleus is involved or whether the author includes Deiters' nucleus. Terminations are localized "an medialen Vorderhornzellen", at medially located anterior horn cells.
Massopust (1957), in cats, studied terminations of vestibulospinal fibres in the grey matter of the cord with Nauta-Gygax' method of impregnation. His statement is as follows: "Medial spinal vestibular fibres and fibres originating from the medial and spinal vestibular nuclei give rise to bilateral terminal degeneration about medial- and ventral parts of laminae 7 and 8 throughout the entire cord. Segmental fibres to the contralateral side, also decussate in the anterior white commissure". The studies of Szentágothai and of Massopust apparently are the only

ones in which the technique used, allowed the visualization of unmyelinated (pre)-terminal fibres in the grey matter.

II. Vestibulo-spinal fibres travelling in the *antero-lateral funiculus*

THE DEITERO-SPINAL SYSTEM

REVIEW OF THE LITERATURE

Similar to the other chapters, when not especially reported, the experiments were performed with the help of Marchi's osmic acid impregnation technique.

The origin of the Deitero-spinal fibres

Held (1891), in a study about the myelogenesis in the brainstem of the cat using Weigert–Pal stained preparations, observed a "Seitenstrangbahn aus dem Deitersschen Kern", a lateral funiculus tract originating in Deiters' nucleus. Russell (1897), in macaca and the dog, Klimoff (1899) and Van Gehuchten (1904), in the rabbit, following lesion of Deiters' nucleus, found degenerating fibres in the anterolateral funiculus of the cord. Lloyd (1900) and Fraser (1901), in the cat and the monkey, could confirm this statement. Russell could not find such degenerating fibres in cases of lesions restricted to the cerebellum, but Thomas (1897) and Probst (1899) contrarily, concluded from their experiments, that part of the fibres originate in the cerebellum. Thomas in this respect mentioned the nuclei interpositus and dentatus, and reported about a "faisceau cerebelleux descendant" a descending cerebellar tract, whereas Probst gave it the name "Kleinhirnvorderstrangbahn" cerebellar anterior funiculus tract. About the presence of cerebellar fibres in the Deiterospinal tract much has been said in the older papers, but a definite conclusion was not reached (Tschermak 1898).
Buchanan (1937) was of the opinion that fibres from Von Bechterew's nucleus also travelled in it. Pompeiano (1957), after section of the anterolateral funiculus in the cervical cord in kittens, found retrograde cell changes confined to Deiters' nucleus, which according to him,

however, does not exclude that other nuclei contribute fibres to the tract.

It seems important to mention the work of Walberg, Bowsher and Brodal (1958). After sectioning the nervus vestibularis in seven adult cats, they found that certain regions of the four vestibular nuclei (superior, median, descending and lateral) were "free from vestibular afferents." The lateral nucleus of Deiters showed degeneration only in its rostroventral part and practically all its giant cells were devoid of degenerating terminalia.

However, these findings did not lead the authors to an alteration of the till now accepted nomenclature of the "vestibular" nuclear complex.

Thus, when writing about vestibulospinal pathways, we must recognize the fact that it is possible that a number of these so-called secondary vestibular fibres have no vestibular origin at all.

The techniques used in this investigation were those of Nauta-Gygax and Glees.

Experimental investigations in the cat in Häggqvist stained preparations confirm the exclusive origin of the Deiterospinal tract from Deiters' nucleus (Busch, 1961).

Course of the Deiterospinal fibres

Thomas and Tschermak, in their studies already referred to, located the fibres at the ipsilateral side of the cervical cord. According to Thomas they have already considerably decreased in number in the thoracic levels, though in the lumbar cord they can still be distinghuished. Probst localized the fibres at the ventral periphery of the ipsilateral anterior funiculus, the lateral part of its area deviating somewhat from the pia mater and approaching the ventral part of the lateral funiculus.

In the thoracic cord he found them only at the marginal zone, somewhat shifted medially because of the disappearance of the tectospinal fibres. He could follow them into the sacral segments. These topographic data are more or less in accordance with those of Van Gehuchten in the rabbit.

Probst (1902) distinguished the "Kleinhirnvorderseitenstrangbahn" the anterolateral funiculus cerebellar tract, (the Deitersopinal tract proper),

in which no cerebellar fibres occur, as part of the formerly mentioned "Kleinhirnvorderstrangbahn" anterior funiculus cerebellar tract.
Winkler in 1920, in the rabbit, described fibres originating from the lateral portion of Deiters' nucleus, which cross and can be followed into the cervical cord. Rasmussen (1932), in the cat, similarly could recognize the presence of crossed fibres originating from Deiters' nucleus.
Van Beusekom (1955), in an experimental study in the cat using Häggqvist's technique, came to the conclusion that only the thick fibres in the area of the tract originate in Deiters' nucleus. He found them to be located in the lateroventral part of the anterior funiculus, at the transition of the antero- and lateral funiculus. Verhaart in a similar investigation came to the same conclusion (1958). Pompeiano (1957) found a somatotopic pattern in Deiters' nucleus, the neurons of its rostroventral portion sending their fibres to the cervical cord, those in the dorsocaudal portion to the lumbosacral, and those in between to the thoracic cord. He based his statement on the location of retrograde neuronal changes in modified Von Gudden experiments.

Termination of the Deiterospinal fibres

Thomas (1897) described the fibres terminating around the anterior horn cells of the cord and Probst stated that they fall apart in small fibres in the anterior horn. According to Held they end in the motor anterior horn neurons and in the accessory nerve nucleus. Investigation on this subject with the modern and more appropriate silverimpregnation methods seem not to have been reported.
After this review of the literature it is justified to conclude that the Deiterospinal fibres originate in Deiters' nucleus, descend in the ipsilateral anterior funiculus where they are localized at the periphery, and can be followed in caudal direction into the lumbosacral segments. Investigations employing Marchi's osmic acid impregnation demonstrated them to proceed to the anterior horns of the cord.

EXPERIMENTS

Cat H 3884, killed 19 days after the operation. The lesion extends in rostrocaudal direction between the planes P 6 and P 8, similar with the

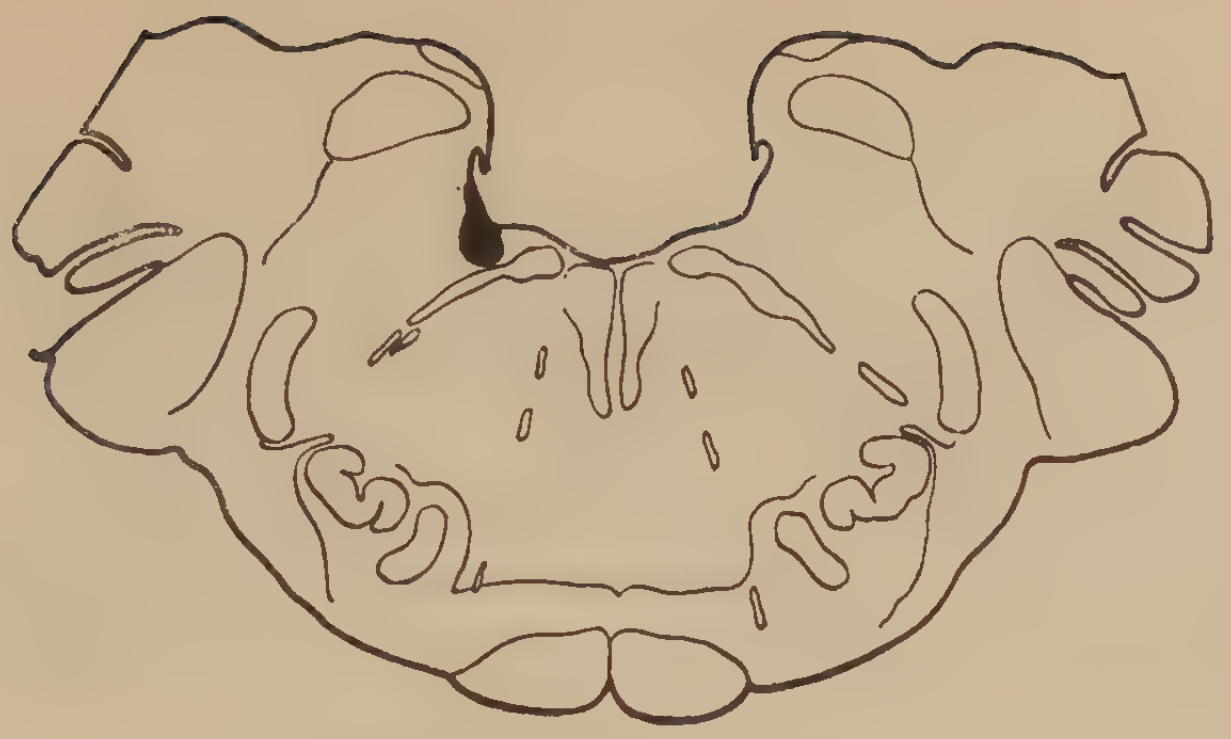

P 6

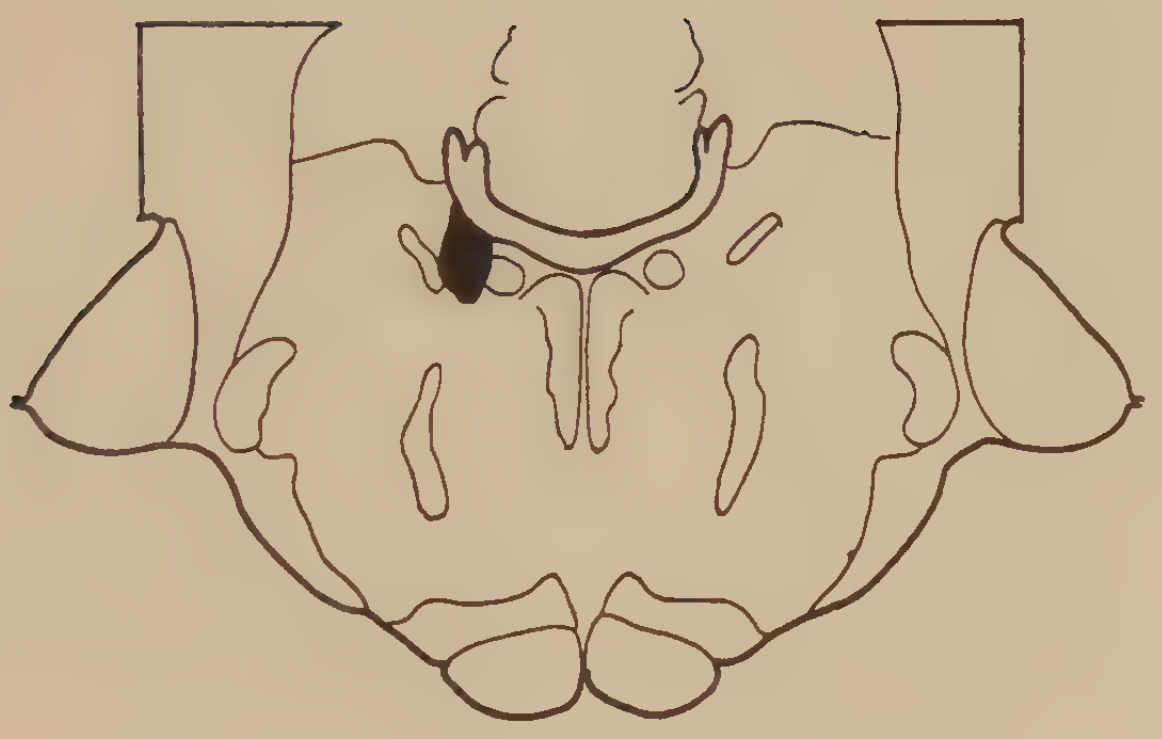

P 7

P 8

Lesion in Cat H 3884.

rostrocaudal extension of the genu N. facialis. It embraces the rostral part of the medial vestibular nucleus and its immediate vicinity. The electrode track passes dorsally through the brachium conjunctivum and the overlying fasciculus uncinatus (Cat V 4 of Busch).
On microscopical examination of the brain stem, the lesion proved to severe both the direct and the crossed vestibular fibres in the medial longitudinal fascicle at the level of the facial nerve knee. The fibres from Deiters' nucleus were severed only very slightly.

Degeneration in the spinal cord

C 1 segment. In the white matter contralateral to the lesion, degenerated fibres are seen in the sulcomarginal zone near the wall of the fissure. Ipsilateral to the lesion degenerated fibres are present along the medial margin of the anterior horn. Along the lateral margin of the anterior horn a few degenerated (reticulospinal) fibres are visible.
Grey matter degeneration at this level is different at both sides. Ipsilateral to the lesion degenerated axons are chiefly seen along the medial margin of the anterior horn, however, they spread laterally to about halfway across the horn. Within the lateral half of the anterior horn also some affected fibres can be distinguished; however, they are much fewer in number than those in the medial half.
Contralateral to the lesion also some degenerated axons are located along the medial margin of the anterior horn; they do not spread so far laterally as in the ipsilateral horn. At both sides some pericellular degeneration can be recognized along the medial border of the anterior horn; the intensity is moderate.
C 3 segment. In the white matter the degenerated fibres are found at essentially the same sites as in the C 1 segment, the areas are somewhat less distinctly circumscribed and the numbers of affected fibres have considerably decreased. Besides this at the lateral side of the ipsilateral anterior horn degenerated reticulospinal fibres are no longer found. Within the grey matter the localization is also essentially the same as in the C 1 segment; however, the difference between both sides is even less marked. Pericellular degeneration along the medial border of both anterior horns is discernable. The degeneration in general is slight to moderate in intensity.

C 1

C 3

C 7

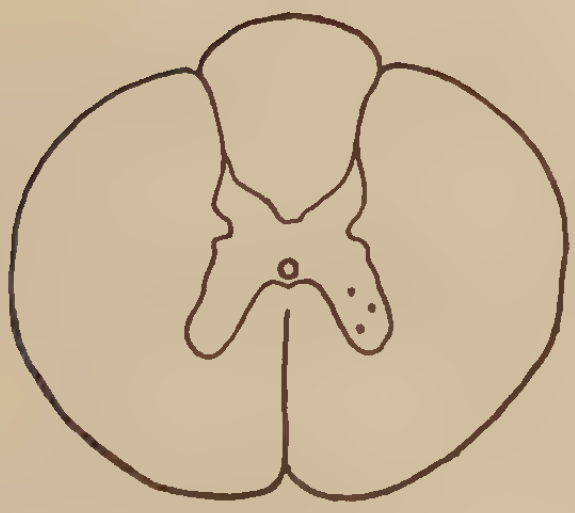

Th 7

Degeneration in the cord of Cat H 3884.

C 7 segment. In the white matter at one side a few degenerated fibres are still present. In the grey matter in some preparations only some slight degeneration can be seen.
The 7 segment. Within the white matter degeneration can no more be distinguished. Within the grey matter some degeneration is present in the ventral part of the anterior horn; in one preparation some pericellular degeneration also is found.

SUMMARY

White matter. Contralateral to the lesion, an area of degenerated fibres was present in the sulcomarginal fascicle along the wall of the fissura mediana anterior, which could be followed to the caudal cervical segments (crossed vestibulospinal fibres). Ipsilateral to the lesion the area of degenerated fibres lay along the medial margin of the anterior horn; degenerated fibres could not be followed beyond the third cervical segment (uncrossed vestibulospinal fibres).
Grey matter. Contralateral to the lesion preterminal degeneration was seen in lamina 8. It was of moderate intensity at high and middle cervical levels, but at a low thoracic level it was only very slight. In the segments C 1 and 3 pericellular degeneration could be distinguished, but at a low thoracic level this was only very rare. Ipsilateral to the lesion preterminal degeneration was similarly located in lamina 8. It was of moderate intensity and could be traced into the third cervical segment. A few reticulospinal fibres along the lateral margin of the ipsilateral anterior horn excepted (not depicted in the scheme), the degenerated fibres were exclusively of vestibular origin.

Cat H 3518

Lesion of the caudal parts of the medial and descending vestibular nuclei. The lesion extends from the level of the caudal border of the genu N. VII to the rostral pole of the nucleus cuneatus; the lesion slightly encroaches upon the medial tip of the restiform body (Cat V 5 of Busch).
The animal was killed 20 days after the operation. Microscopic study of the brainstem showed a large number of degenerated vestibular

P 9

P 10

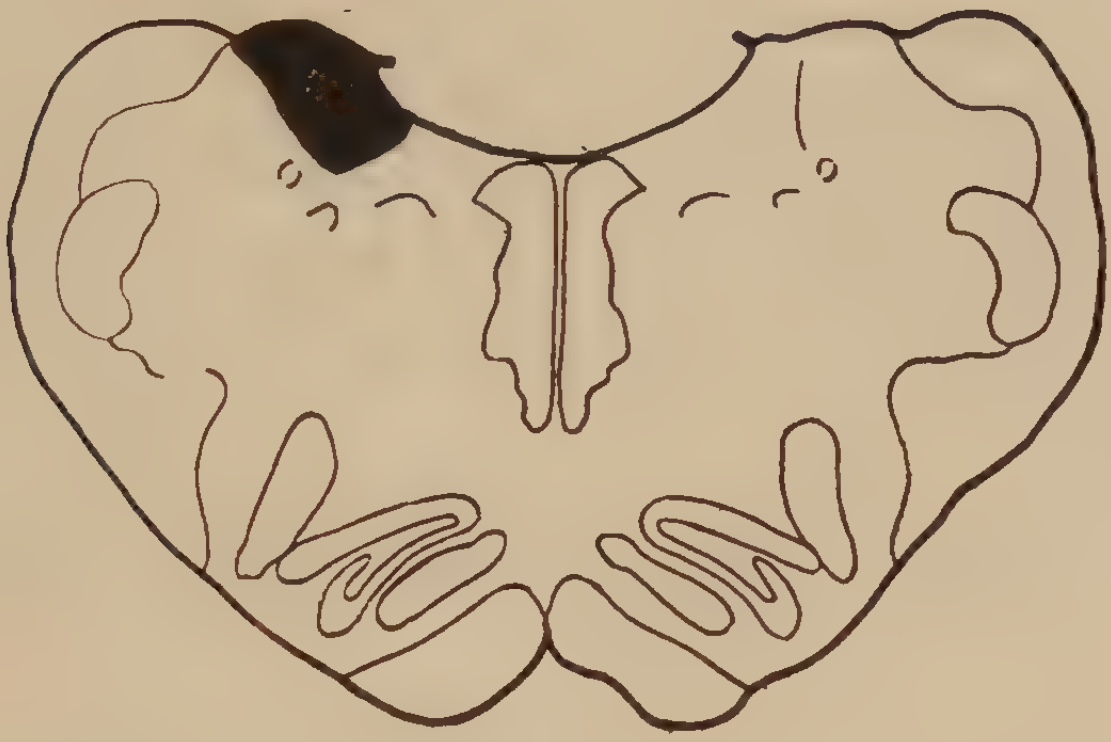

P 11

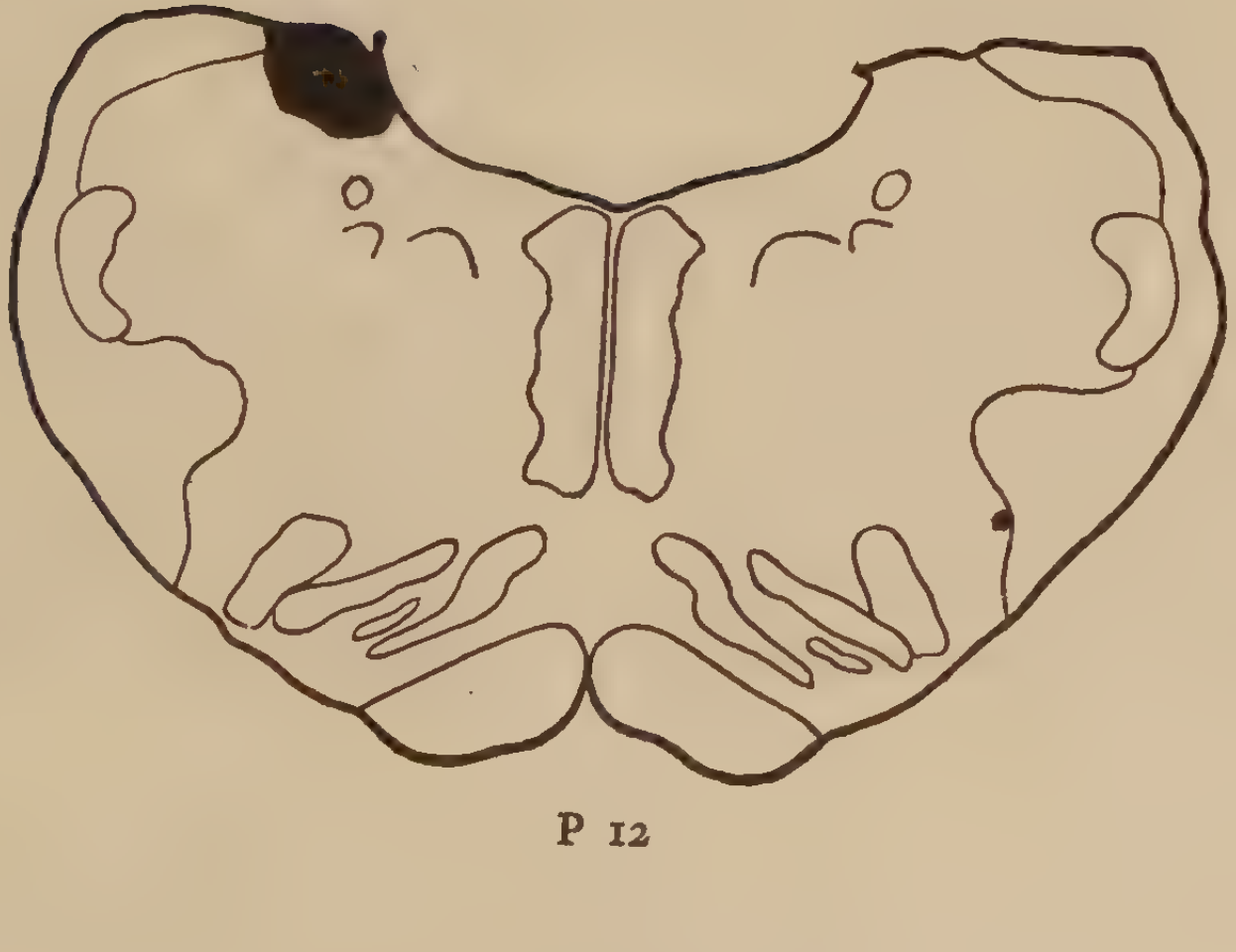

P 12

Lesion in Cat H 3518.

fibres. The lesion extends in rostrocaudal direction between the planes P 9 and P 12.

In the cord the degeneration is found as follows:

The C 1 segment. In the white matter ipsilateral to the lesion an area along the medial margin of the anterior horn contains a large number of degenerated fibres: these are the uncrossed vestibular spinal fibres. Contralateral to the lesion a small number of degenerated fibres is located along the fissura mediana anterior. As will appear later, this is only part of the crossed vestibulospinal fibres.

The C 5 segment. In the white matter at both sides the number of affected fibres is much less, but their location is the same as in the C 1 segment.

In the grey matter degeneration is located in the medial half of both anterior horns and somewhat also in the central grey matter. Ipsilateral to the lesion the lateral half of the anterior horn also contains degenerated fibres and even in the intermediate grey matter some degeneration is located. In the lateral part of this anterior horn some pericellular degeneration occurs.

The C 8 segment. In the Häggqvist slides, which were not very well stained, the white matter does not exhibit degenerated fibres, the same being the case in more caudal levels.

In the grey matter degeneration bilaterally is confined to an area along the medial margin of the anterior horns, it is only slight in intensity.

The low thoracic segments. Again some degeneration is found in the medial half of both anterior horns, in the ipsilateral somewhat more marked than in the other.

The L 6 segment. In the ipsilateral anterior horn a moderate degree of degeneration can be detected, which from the medial margin spreads far laterally. In the contralateral anterior horn degeneration of slight degree only occurs; it is confined to the medial half.

The Sa 1 segment. A slight degree of degeneration is apparent in the medial half of the ipsilateral anterior horn, whereas in the contralateral one some slight degeneration is found confined to the medial margin.

SUMMARY

The degeneration in the white matter was confined to the upper half

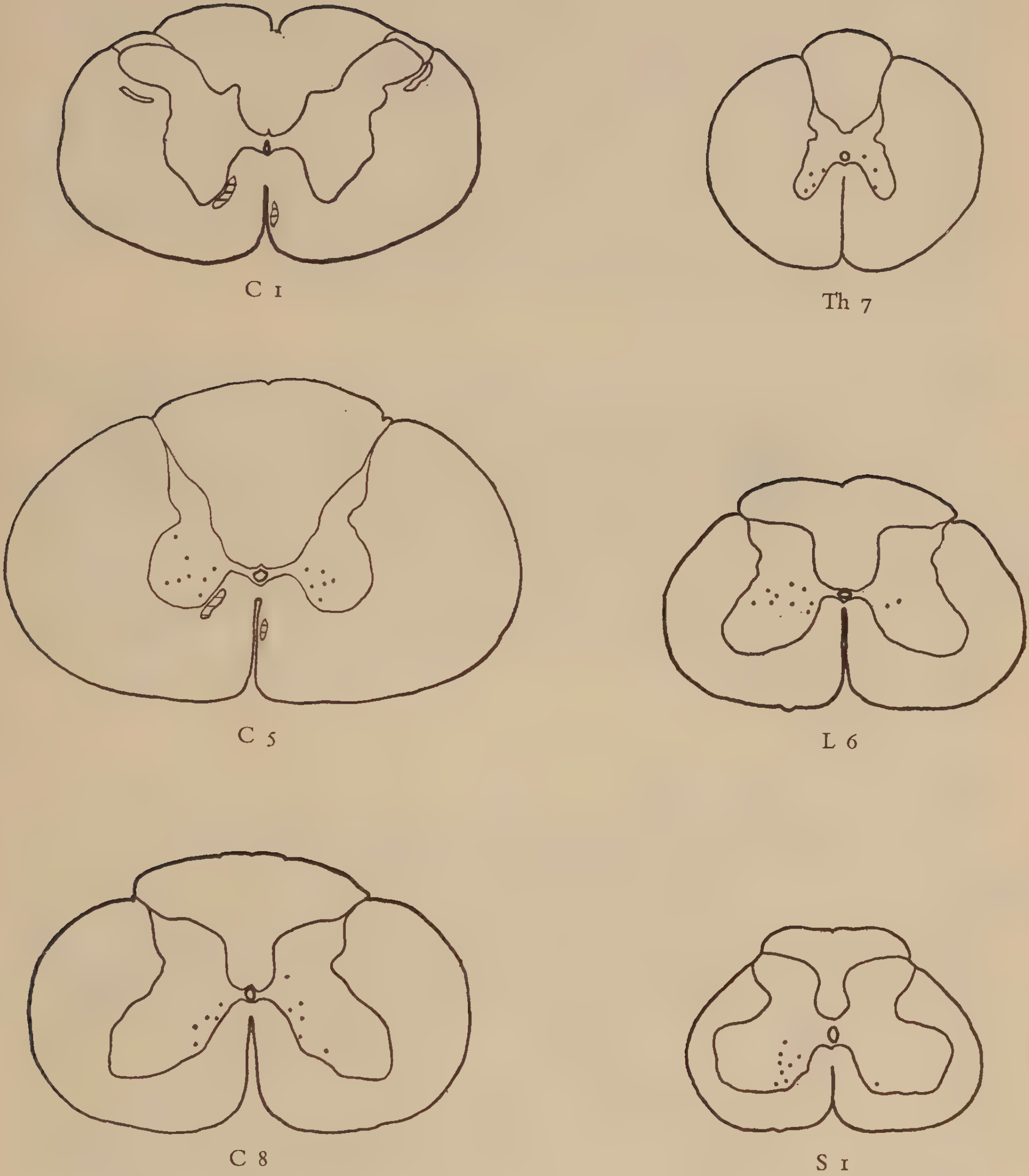

Degeneration in the cord of Cat H 3518.

of the cervical cord, where ipsilateral to the lesion degeneration was found along the medial side of the anterior horn. Contralateral to the lesion, a partial degeneration of the crossed vestibulospinal fibres within the sulcomarginal fascicle along the fissure could be distinguished.
In the grey matter degenerated fibres could be followed into the sacral cord; the degeneration lay chiefly in lamina 8, but ipsilateral to the lesion at some levels it encroached upon lamina 7. In the cervical cord degeneration was equal at both sides but lumbosacrally contralateral to the lesion it was less in intensity than ipsilaterally.

Cat H 3514

The lesion in this animal comprises the entire nucleus vestibularis superior and the rostral part of the nucleus medialis and a large medioventral part of the lateral vestibular nucleus, but it does not damage the reticular formation (Cat V 2 of Busch). In rostro-caudal direction the lesion extends between the planes P 5 and P 9. The animal was killed 20 days after the operation. At inspection it was proved that direct- and crossed vestibulospinal fibres and those from Deiters' nucleus were degenerated alike.

Degeneration in the cord

The C 2 segment. Ipsilateral to the lesion there are in the white matter of the cord two areas containing a considerable number of degenerated fibres, one along the medial side of the anterior horn, the other at the transition of the anterior and the anterolateral funiculi along the periphery and distending dorsolaterally. Contralateral to the lesion degenerated fibres are restricted to an area along the fissura mediana anterior. Within the grey matter degenerated fibres are found in both halves of the cord, ipsilaterally they occupy a much larger area than contralateral to the lesion. The area contralateral to the lesion is confined to the medial half of the anterior horn, whereas ipsilaterally also the ventrolateral part of the horn contains affected fibres. Pericellular degeneration of slight intensity is found occasionally in the ipsilateral lamina 8.
The C 5 segment. Within the white matter the number of degenerated

P 5

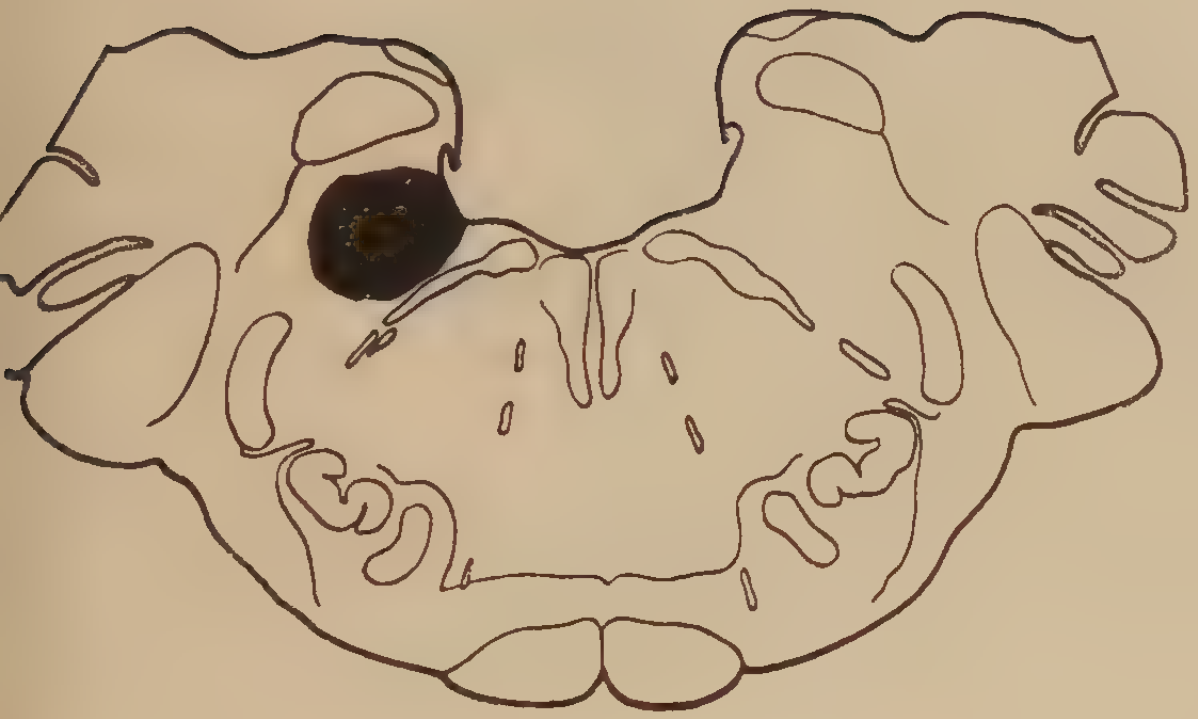

P 6

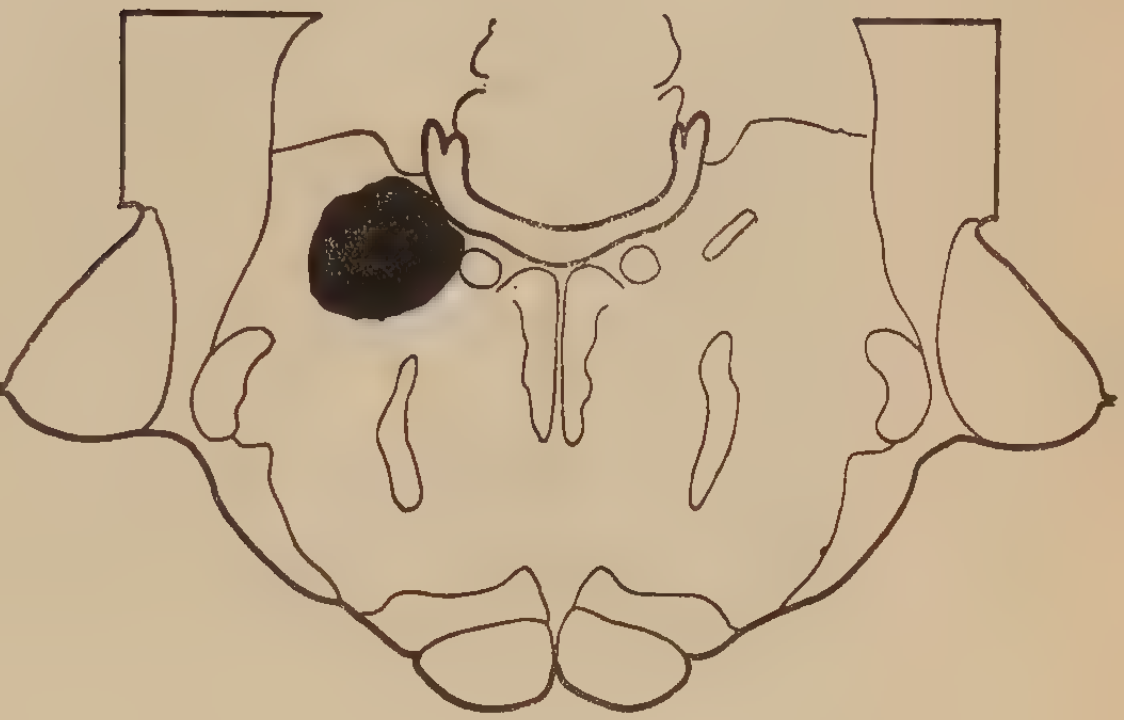

P 7

P 8

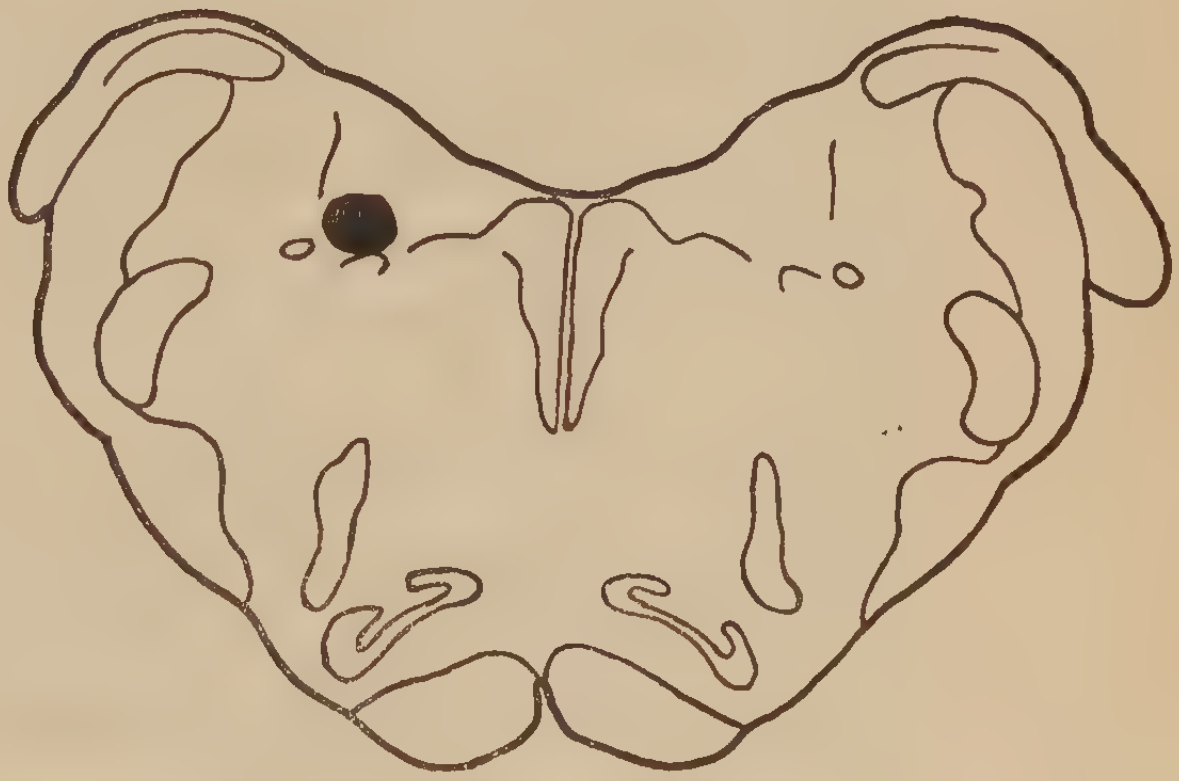

P 9

Lesion in Cat H 3514.

fibres has decreased much, however, they occupy the same sites as in the C 2 segment.

Within the grey matter only ipsilaterally some slight degeneration is present, located in the medial part of the anterior horn. In view of the other results the discrepancy between the degeneration in the white and the grey matter may be attributed to some failure of the impregnation technique.

The C 7 segment. Within the white matter ipsilaterally a few degenerated fibres can be distinguished along the medial side of the anterior horn.

In the area of the Deiters' nucleus fibres a large number of anterior root fibres makes observation of degenerated fibres unfeasible. In the grey matter at this level no degeneration can be seen.

The high thoracic segment. Degeneration detectable in this segment is very slight, it is confined to the medial half of the ipsilateral anterior horn.

The L 3 segment: degeneration similarly is confined to the medial half of the ipsilateral anterior horn, it is of slight intensity.

The L 6 segment. Degeneration is identical with that in the L 3 segment, pericellular degeneration can be seen around one cell only.

SUMMARY

Within the white matter ipsilateral to the lesion degenerated fibres, caudally decreasing in quantity, could be followed into the seventh cervical segment; they were located along the medial side of the anterior horn and along the periphery at the transition of the anterior and the anterolateral funiculi, spreading in a dorsolateral direction. Contralateral to the lesion fibres similarly could be followed over the cervical cord. However, they were located in the sulcomarginal fascicle, along the fissura mediana anterior.

The grey matter in a high cervical level showed degeneration at both sides located in lamina 8, ipsilaterally it was somewhat more extensive than contralaterally. In the lower segments degeneration was restricted to the ipsolateral half; it was located in lamina 8, and in the L 3 segment it encroached upon lamina 7.

Pericellular degeneration was seen only occasionally, the intensity everywhere was slight. Degeneration of vestibulospinal fibres in the

C 2

Th 2

L 3

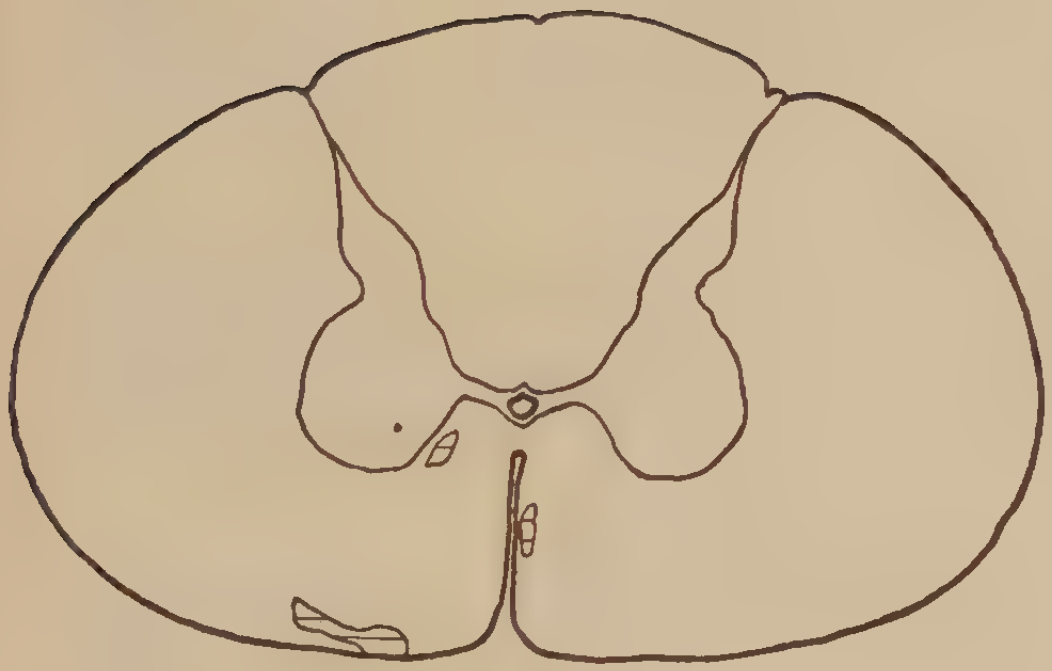

C 5

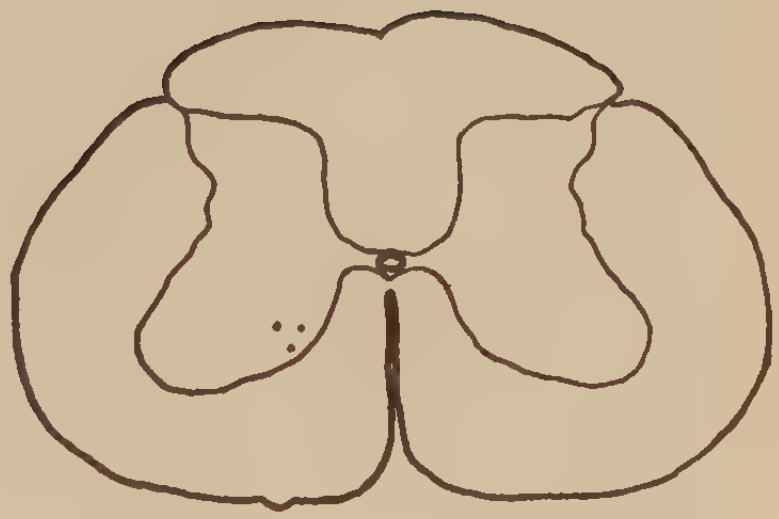

L 6

Degeneration in the cord of Cat H 3514.

grey matter ipsilaterally could be followed much further caudally than contralateral to the lesion.

Cat H 4867

The lesion in this animal comprises the dorsocaudal part of Deiters' nucleus, at the level of the planes P 8 and P 9. Its greatest extension is located in the plane P 8. The lesion does not encroach upon the other vestibular nuclei. The animal was killed 10 days after the operation. On microscopical examination of the medulla it was proved that unilaterally only a number of descending fibres from Deiters' nucleus was severed.

Degeneration in the cord

The C 1 segment. In the ipsilateral white matter the area of the Deiters' nucleus fibres proves to contain degenerated fibres nearly all over its surface. They are mostly thick fibres, which are especially numerous in the dorsal part of the area. Unfortunately Nauta-Gygax preparations of this segment all proved to be unsatisfactorily impregnated.
The C 2 segment. From the area of degeneration, fibres are seen to enter the ventrolateral part of the anterior horn and proceed over some distance dorsally in it. Pericellular degeneration is visible in the dorsal part of lamina 8; its intensity is moderate.
The C 3 segment. Within the white matter the number of degenerated fibres is much less than in the higher segments, a small number of fibres being present only in the dorsal part of the area. In the dorsal part of the anterior horn some slight degeneration is present.
The C 7 segment. In the white matter only very few degenerated fibres can be distinguished in the area analogous to that of Deiters' nucleus fibres in the upper cord. In more caudal segments they can no more be seen, but it must be kept in mind that solitary degenerated fibres among the normal escape detection easily.
Within the grey matter only along the medial margin of the anterior horn some slight degree of degeneration is visible. In caudal thoracic segments at the base of the anterior horn some slight degeneration is located, in segment L 3, however, it cannot be found. In segments L 6 and L 7 only occasionally some slight degeneration can be located at the base of the anterior horn.

P 8

P 9

Lesion in Cat H 4867.

C 1

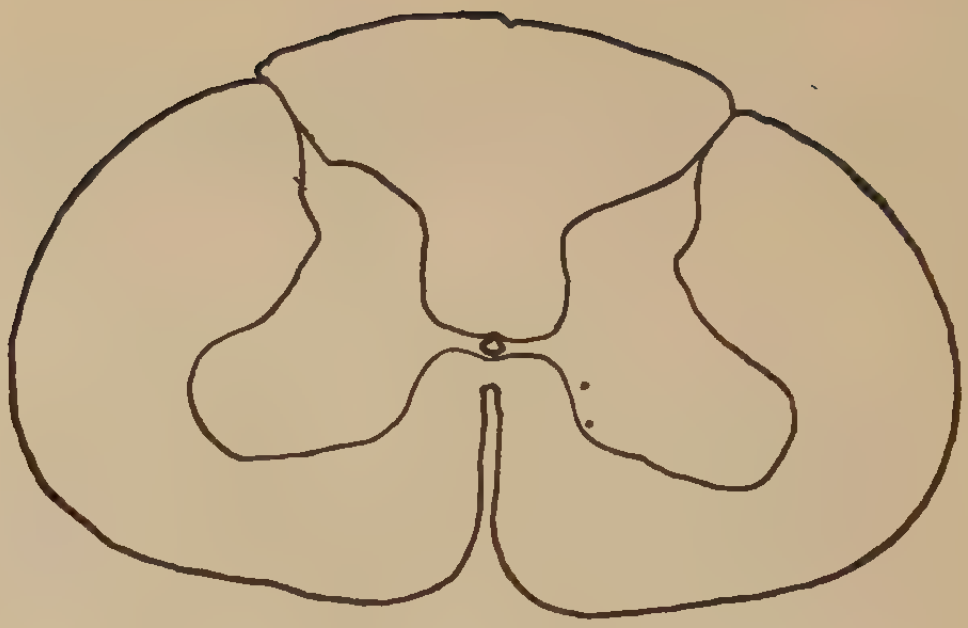

C 7

C 2

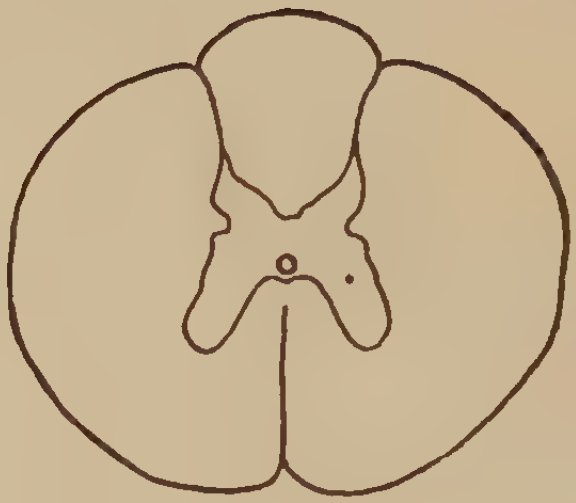

Th 7

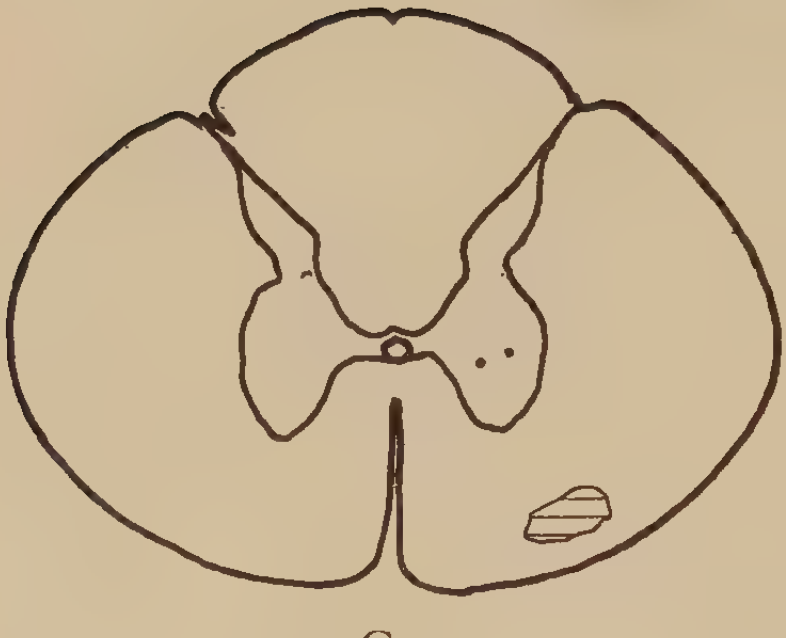

C 3

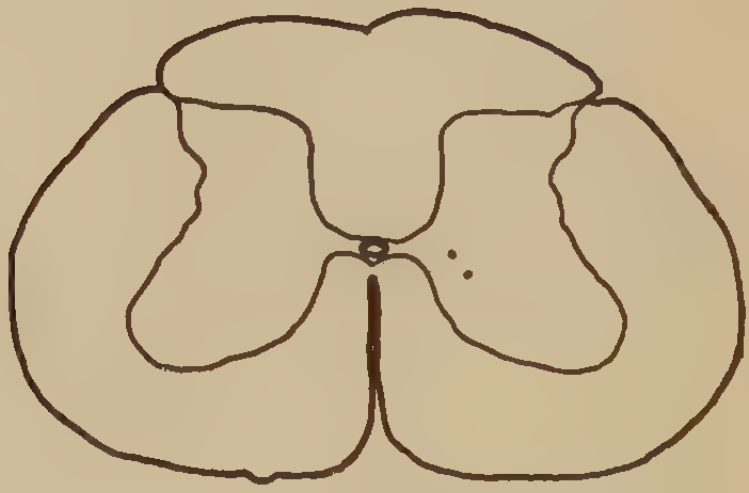

L 6

L 7

Degeneration in the cord of Cat H 4867.

Preterminal degeneration along one side of a ganglioncell and one of its dendrites is present at the transition of laminae 7 and 8 in the L 6 segment. In the sacral segments degeneration is no longer demonstrable.

SUMMARY

Within the white matter a number of degenerated fibres were present in the area of Deiters' nucleus fibres. They could be followed to the 7th cervical segment; in the first cervical segments they were especially numerous in the dorsal part of the area.

The grey matter. Following partial severance of Deiters' nucleus, degeneration proved to be most marked in the C 2 segment, where it was moderate in intensity. At lower levels degeneration was only slight. It was confined to the lamina 8 of the anterior horn.

Both in the white and the grey matter degeneration was confined to the side of the lesion.

Cat H 4521

In this cat similar to the previous animal part of Deiters' nucleus was lesioned. The animal was killed 14 days after the operation. On microscopical examination of the medulla the lesion appeared to comprise the dorsocaudal part of Deiters' nucleus and to encroach upon neither the other vestibular nuclei nor the reticular formation. However, a small electrode track passes through the caudal pole of the superior vestibular nucleus (Cat V 3 of Busch).

The lesion extends in rostrocaudal direction between the planes P 6 and P 8. Unfortunately only the upper cervical cord was available for study.

Degeneration in the cord

The C 1 segment. In the white matter in the area of Deiters' nucleus fibres a large number of coarse degenerated fibres is present.

In the grey matter degenerated fibres are seen to radiate into the anterior horn from its most ventral tip onwards; they fan out all over it up to the ventral border of the central grey matter. The degeneration is moderate in intensity.

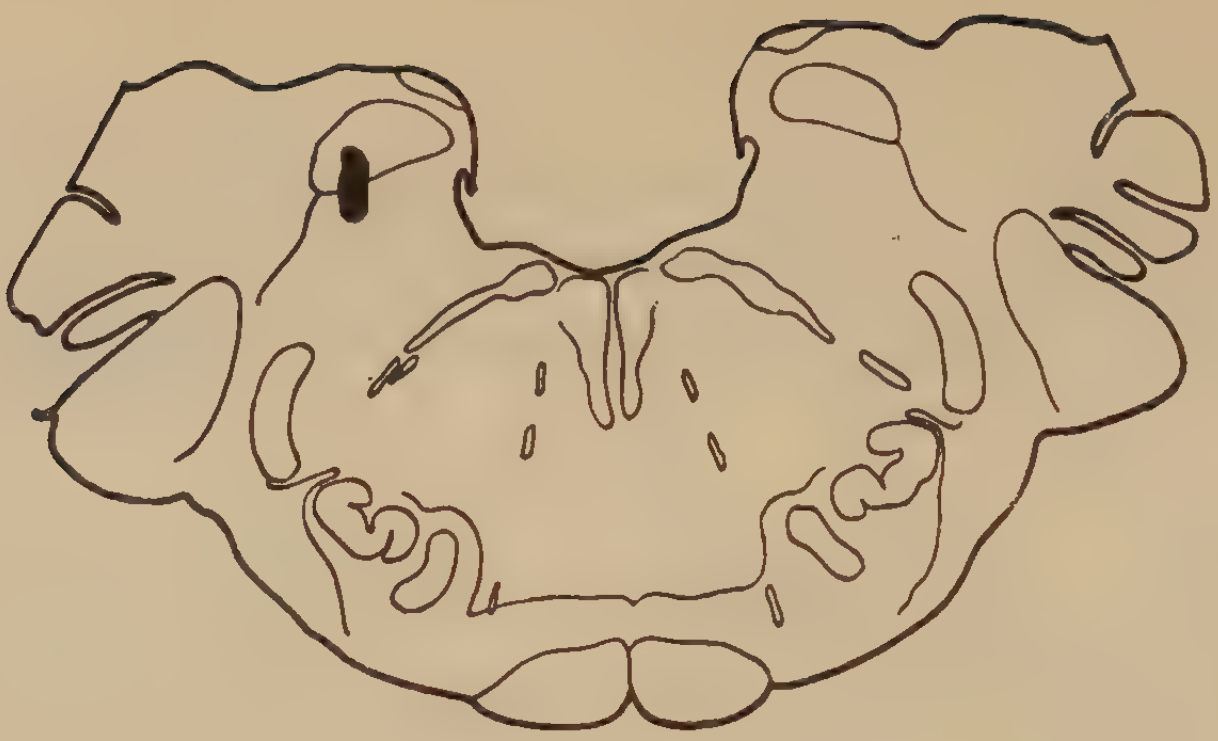

P 6

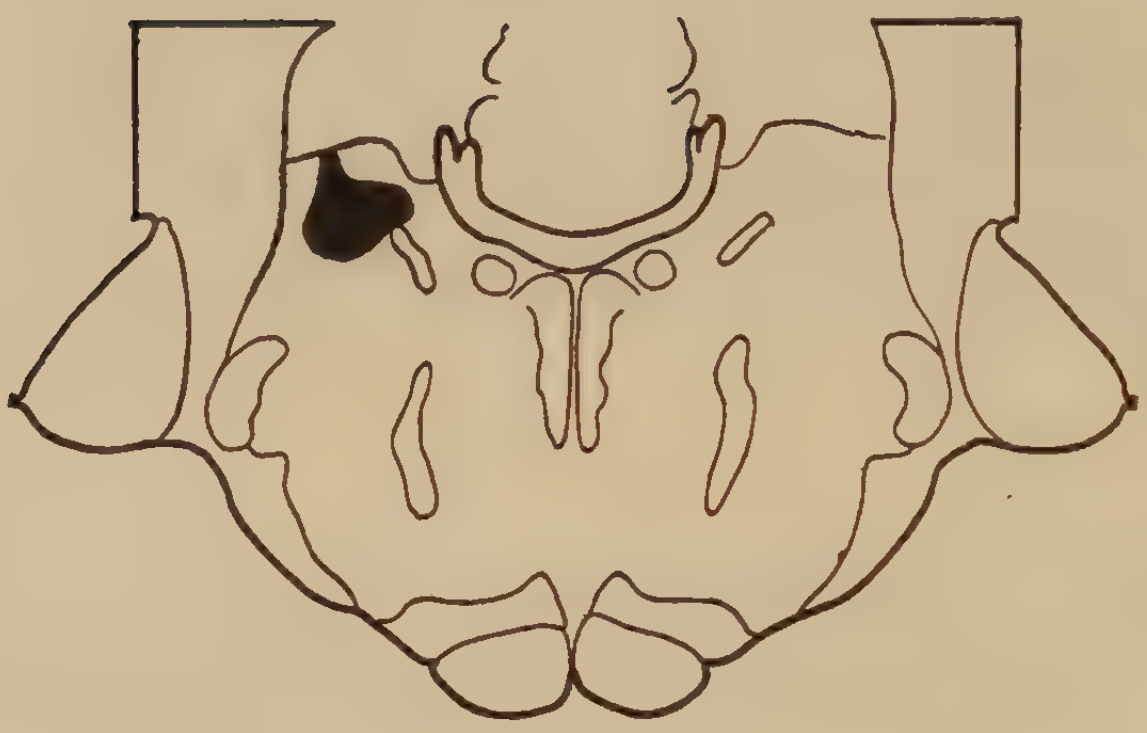

P 7

P 8

Lesion in Cat H 4521.

C 1

C 2

Degeneration in the cord of Cat H 4521.

In the C 2 segment degeneration both in the white and the grey matter is identical with that in the C 1 segment.

SUMMARY

In the area of the lateral vestibulospinal tract ipsilateral to the lesion at high cervical levels a large number of coarse degenerated fibres was located. In the ipsilateral grey matter a moderate degree of degeneration was seen in laminae 8 and 9 of the anterior horn.

Cat H 5267

The lesion in this animal extends in rostrocaudal direction between the planes P 8 and P 9. It embraces the dorsocaudal part of the lateral vestibular nucleus and encroaches only upon a very small part of the descending vestibular nucleus.
The animal was killed 10 days after the operation.
Microscopical examination of the brainstem showed severance of part of the Deiterospinal fibres and of only a few vestibulospinal fibres descending in the sulcomarginal fascicle.

Degeneration in the cord

The degeneration in the white matter of the cord will be described in the summary of this experiment.
The C 1 segment: over nearly the whole ipsilateral anterior horn degeneration is seen of a moderate degree.
The C 2 segment: from the most ventral tip of the ipsilateral grey matter, degeneration is found over the ventral two third of the anterior horn. Pericellular degeneration is repeatedly seen in lamina 8. The intensity of the degeneration is still of moderate degree.
The C 3 segment: the degeneration at this level, which is of slight to moderate intensity, remains confined to the ventromedial part of the ipsilateral anterior horn. Occasionally, pericellular degeneration is seen in this area.
The C 7 segment: the degeneration has become much less pronounced, it is of slight intensity. From the point where the medial border of the anterior horn bends laterally, it spreads over a cuneated area.

P 8

P 9

Lesion in Cat H 5267.

C 1

C 2

C 3

C 7

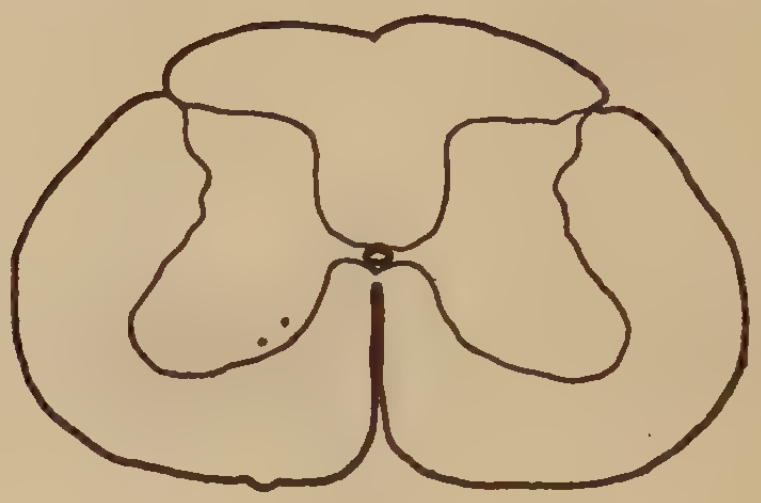

L 6

L 7

Degeneration in the cord of Cat H 5267.

The low Thoracic segments: at this levels no degeneration in the grey matter is found. The same is the case in the L 3 segment.
The L 6 and L 7 segment: degeneration of slight intensity is seen in both these segments. It is located along the medial border of the anterior horn, just where it bends laterally.
The Sa. segments: only in a very few preparations some degeneration is seen in the medial part of the anterior horn (not depicted in the scheme).

SUMMARY

White matter degeneration: in the homolateral anterolateral funiculus of the C 1 segment, degeneration was seen in an area that spreads from the periphery in dorsolateral direction. In the dorsal tip of this area the greatest number of degenerated fibres was found. In the C 3 segment this number was considerably diminished. In the C 7 segment, in the Häggqvist slides, no degenerated fibres could be found anymore.
Grey matter degeneration: as caudal as the lumbar intumescence degenerated preterminals could be found. From the C 7 segment downwards the degeneration was of slight intensity; rostral of the C 7 segment the intensity was moderate. Pericellular degeneration was repeatedly found at high cervical levels.
In all the studied segments the degeneration was localized in lamina 8; except in the C 1 segment where it extended somewhat in lamina 9. No degeneration was found in the low thoracic- and the high lumbar levels.

DISCUSSION

In two cats (H 3884 and 3518) both the crossed and the direct vestibulospinal fibres within the sulcomarginal fascicle could be severed almost exclusively. In these animals preterminal degeneration was largely confined to lamina 8. With regard to the white matter the statement of Busch about the direct and the crossed vestibular fibres both descending within the sulcomarginal fascicle could be fully confirmed. They lay along the medial side of the anterior horn and the fissura mediana anterior respectively.
In an other experiment (cat H 3514), both the vestibulospinal fibres within the medial longitudinal fascicle and the fibres from the lateral

vestibulospinal tract were severed. In this case preterminal degeneration was located bilaterally in lamina 8; ipsilaterally to the lesion it was more extensive than contralaterally and encroached upon lamina 7 occasionally, while it could be followed into the lumbar cord.
The localization within the grey matter was essentially identical to that found by Szentágothai-Schimert and by Massopust. The latter's statement about fibres crossing in the cord could not be substantiated.

In three cats (H 5267, 4867 and 4521) the spinal fibres from Deiters' nucleus could be partly but selectively interrupted at their origin. This resulted in a white matter degeneration localized at the transition of the anterior and the anterolateral funiculus of the cord, which in Häggqvist preparations could be followed into the seventh cervical segment. The same was found in cat H 3514, in which the other vestibulospinal fibres also were severed.
Preterminal degeneration in the grey matter of the cord in the partial, lateral vestibulospinal tract lesions could be followed to the low lumbar cord, it was localized in lamina 8 ipsilateral to the lesion. In one animal the destruction of Deiters' nucleus was subtotal, unfortunately in this case only the upper cervical cord could be studied; the degeneration extended over the laminae 8 and 9.
The observations about the terminations of Deiters' nucleus fibres were in accordance with those made in Marchi impregnated preparations by André Thomas and Probst. As far as could be ascertained, studies with the recent silverimpregnation methods on this subject have not yet been performed. The localization of the fibres from Deiters' nucleus in the white matter of the cord as demonstrated in the present material agrees with that reported in the literature.

CHAPTER VII

THE RETICULOSPINAL FIBRESYSTEMS

REVIEW OF THE LITERATURE

When not stated otherwise, in the investigations to be reviewed Marchi's technique has been employed. As discussing the origin and course of these systems separately proved to make a review confusing, in contrast with the other chapters both will be dealt with together.

Von Bechterew in 1855, in human embryo's only a few weeks old, described fibresystems that originated from the tegmentum pontis and could be followed into the "aussersten Abschnitte", the most caudal part, of the anterolateral funiculus of the cord.

Held (1893) studied the myelinisation in kittens one to five days old and came to the conclusion that fibres from the whole reticular formation enter the medial longitudinal fascicle. They arise chiefly in 2 areas of the lower brain stem. One of these comprises the rostral third of the medulla between the rostral part of the vagus nerve nucleus and the inner knee of the nervus facialis. Ipsilaterally descending fibres arising from it, travel in the ventral part of the medial longitudinal fascicle, whereas other fibres decussate in the "Fountain" decussation and take their site in the dorsal part of the medial longitudinal fascicle. The other area lies in the pons, especially at the transition of its most rostral and intermediate third; chiefly uncrossed fibres descend from it in the medial longitudinal fascicle.

Probst (1899) found degenerated fibres in the ipsilateral anterior funiculus of the cord in a cat following a lesion in the lateral part of the reticular formation at a rostral pontine level. The affected fibres were localized along the fissura mediana anterior as well as spread over the medio-ventral corner of the anterior funiculus. Tschermak (1898) reported about direct and crossed reticulospinal fibres in the cat, localized within the cord near the fissura mediana anterior and in the dorsolateral part of the lateral pyramidal tract area respectively.

Thomas (1903), in the human brain stem, studying cases of local softenings in the pontine tegmentum, found a tractus mesencephalo-spinalis,

arising from the medial part of the pontine tegmentum. In his Weigert-Pal stained preparations he could follow it in the anterior funiculus of the cord.

Lewandowsky (1904), in the dog and the cat, found that from the "nucleus reticularis tegmenti" of the ventral reticular formation of the pons, fibres arise that, "fast bündelartig zusammen gedrängt" assembled almost to a bundle, run in the most medial part of the rubrospinal tract with which they enter the cord. Besides these fibres he found also fibres originating from the lateral part of the reticular formation of the caudal medulla which could be followed into the anterior funiculus of the cervical cord. He gave them the name of "Fasciculus Thomasi". Finally he described fibres originating from large neurons situated medial to the motor trigeminal nucleus, that in all probability descend to the ipsilateral half of the cord.

Pfeiffer (1916), in human anencephali, demonstrated fibres originating in the reticular formation, which cross in a high cervical level and subsequently descend in the anterior funiculus of the cord.

Papez (1926) in experiments in the cat, in which he made relatively large lesions, could distinguish three reticulospinal tracts.

1. The medial reticulospinal tract, containing the largest number of reticulospinal fibres; the majority of these fibres he assumed to originate from the large reticular neurons in the rostral part of the medulla, the other fibres from the reticular formation cells in the pons and the isthmus. Most of the fibres from the medulla descend ipsilaterally, some of the medial fibres, however, do cross. Within the cord they are located in "the intermediate stratum between the medial longitudinal bundle and the ventral fasciculus proprius".

2. The lateral reticulospinal tract, which predominantly originates from neurons located medial to the masticator nucleus in the pons; its fibres cross and in the cord descend in the posterolateral funiculus between the lateral pyramidal and the rubrospinal tract.

3. The ventral reticulospinal tract which originates "somewhere" in the rostral pons or the isthmus, lateral to Von Bechterew's reticular nucleus. Within the cord it lies in the anterior funiculus between

the fasciculus proprius and the more peripherally located lateral vestibulospinal tract.

Pitts (1940), from a study predominantly based on experimental material in cats, accepted that the reticulospinal fibres descend ipsilaterally, spread all over the anterior and the lateral funiculi of the cord.

Verhaart (1953), in the cat in Häggqvist stained slides, could follow reticulospinal fibres down to the first lumbar segment of the cord. Van Beusekom (1955), in his thesis pointed out that in the cat the reticulospinal system is not assembled in more or less compact bundles. According to him, there is some degree of concentration of such fibres in the medial longitudinal fascicle, and between this bundle and the direct lateral vestibulospinal tract. Otherwise these fibres are spread in the anterior and the lateral funiculi of the cord, especially in the areas of the rubro- and the vestibulospinal tracts. The fibres located between the medial longitudinal fascicle and the latter tract, according to this author, can be followed through the cervical intumescence, whereas the other fibres lying outside Papez' areas, do not descend beyond the second cervical segment.

Sie (1956), also from a study of Häggqvist-stained preparations, in man, found the reticulospinal systems within the cervical cord, spread all over the anterior funiculus.

Torvik (1957) who used Von Gudden's modified method as initiated by Brodal, found descending reticular fibres from the pons and the medulla. Those from the pons did not cross, whereas part of the medullary fibres did. In the cervical cord the fibres of the pons were found in the anterior funiculus, whereas those from the medulla lay more lateral and ventral in the anterolateral funiculus. According to Torvik none of these fibres reached the lumbar intumescence. Verhaart and Van Beusekom (1958), in the cat, were not able to localize the reticular fibres in the cord precisely; they favor the idea that their majority lie within the rubro- and vestibulospinal (Deiterospinal) tracts.

Busch (1961) from an experimental study with Häggqvist stained preparations distinguished 4 reticulospinal systems in the cat, two of which were crossed.

1. An uncrossed thick fibred system, THE MEDIAL RETICULOSPINAL TRACT, in the anterior and partly in the anterolateral funiculus of the

cord, which has its origin in the reticular formation from the level of Von Gudden's nucleus in the upper pons to that of the rostral and caudal parts of the medulla.

2. THE LATERAL BULBOSPINAL TRACT, uncrossed, which is the same as Lewandowsky's "fasciculus Thomasi" (1904). It originates in the lateral bulbar reticular formation. Its origin may, according to Busch "extend rostrally as far as the level of the facial nucleus". In the spinal cord its fibres do not form a well-defined bundle.

3. THE CROSSED PONTOSPINAL TRACT, the origin of which was traced by Busch to scattered cells at the level of the rostral half of the masticator nucleus. Other reticular cells in this area give their fibres by way of the uncrossed medial reticulospinal tract. This tract shows an intimate topographical relationship to the rubrospinal tract.

4. THE CROSSED BULBOSPINAL TRACT, originating "at the level of the facial nucleus and further caudally". This system is found by Busch to proceed as a compact coarsefibred bundle in the dorsomedial part of the bulbar fasciculus longitudinalis medialis.

Termination of the reticulospinal fibres

According to Probst, the reticulospinal fibres which he described end in the cervical segments of the cord. Both Tschermak and Redlich (1899), from study of experimental material in the cat, reported to have seen collaterals of reticulospinal fibres radiating into the anterior horn. Redlich saw some of these fibres terminate around neurons in the medial part of the anterior horn, whereas others traversed the anterior commissure and could be followed into the contralateral horn. According to him, in both the dog and the cat, the reticular fibres project on the ganglioncells of the cervical and lumbar intumescences. As fas as could be ascertained, studies on this subject with the modern silver impregnation methods have not yet been reported.

It proved to be awkward to give a summary of the facts from the literature as reviewed, because the conclusions of the different authors deviate considerably.

When describing the material of the present investigation the classification of the reticulospinal systems as given by Busch will be used.

Cat H 4426

The lesion lies between the planes P 2 and P 5. It comprises the medial portion of the medial reticular formation, leaving both the medial longitudinal fascicle and the predorsal area intact. In the plane P 5 the electrode track reaches the ependym of the fourth ventricle, however, leaving the vestibular nuclei undamaged. The animal was killed 21 days after the operation. Within the medulla the uncrossed medial reticulospinal tract proved to show degeneration as well as the crossed pontospinal tract, of which some laterally situated fibres were severed caudal to their crossing. No fibres of this crossed pontospinal system were severed near their origin, because this origin lies much more dorsally i.e. near the nucleus masticatorius (Cat P 2 of Busch).

Degeneration within the cord

The C 1 segment. Degeneration in the white matter is entirely ipsilateral, it is very marked in the ventral part of the anterior funiculus and reaches its periphery. Within the lateral funiculus a much smaller number of degenerated fibres is found.
The C 2 segment. Within the grey matter at both sides of the cord slight to moderate degeneration is seen; ipsilateral to the lesion its area is much more extensive than at the other side. It extends from the medial border of the anterior horn to its base and somewhat into the intermediate grey matter. At the contralateral side it is located in the central and the intermediate grey matter.
The C 3 segment. Degeneration in the white matter is essentially identical with that in the C 1 segment.
Within the grey matter at both sides again degeneration of slight to moderate intensity is present, the difference between both sides apparently is somewhat less than in the previous segment. It is located bilaterally within the medial half of the anterior horn, and at one side also along the medial anterior horn border. The anterior commissural area, however, does not show any degeneration. At the side contralateral to the lesion, in lamina 8 pronounced pericellular degeneration occurs, and in lamina 9 fine preterminal degeneration lies along some processus,

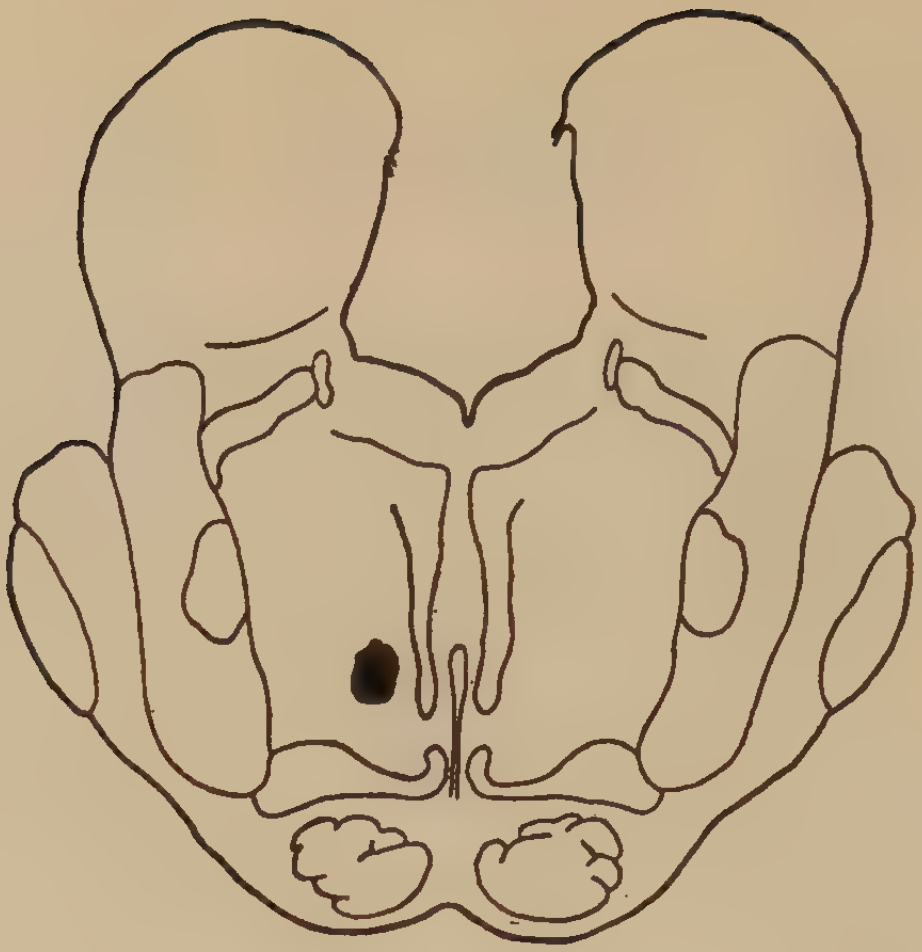

P 2

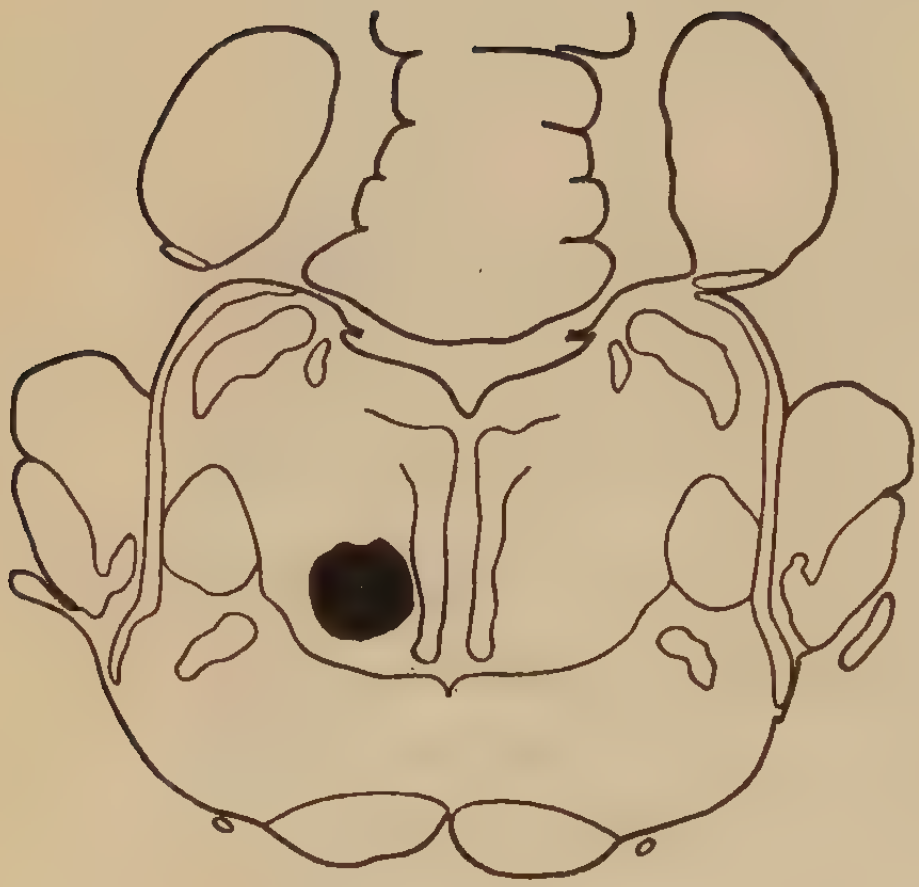

P 3

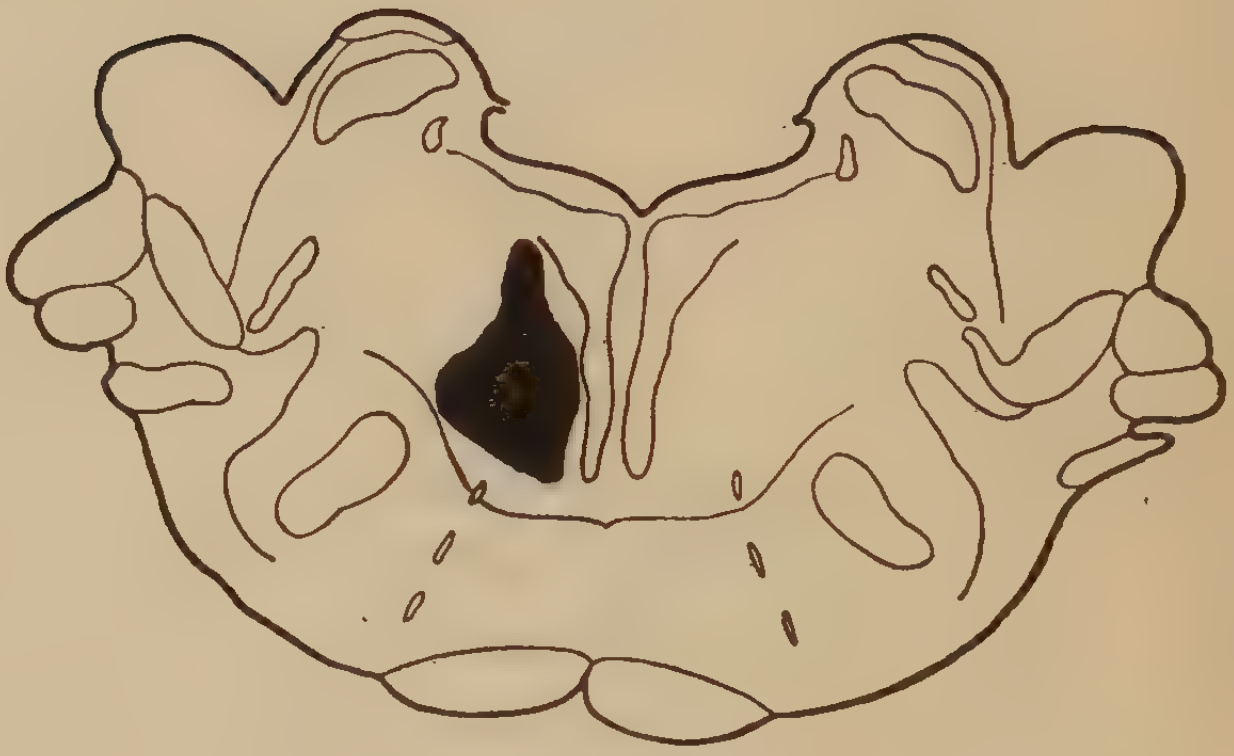

P 4

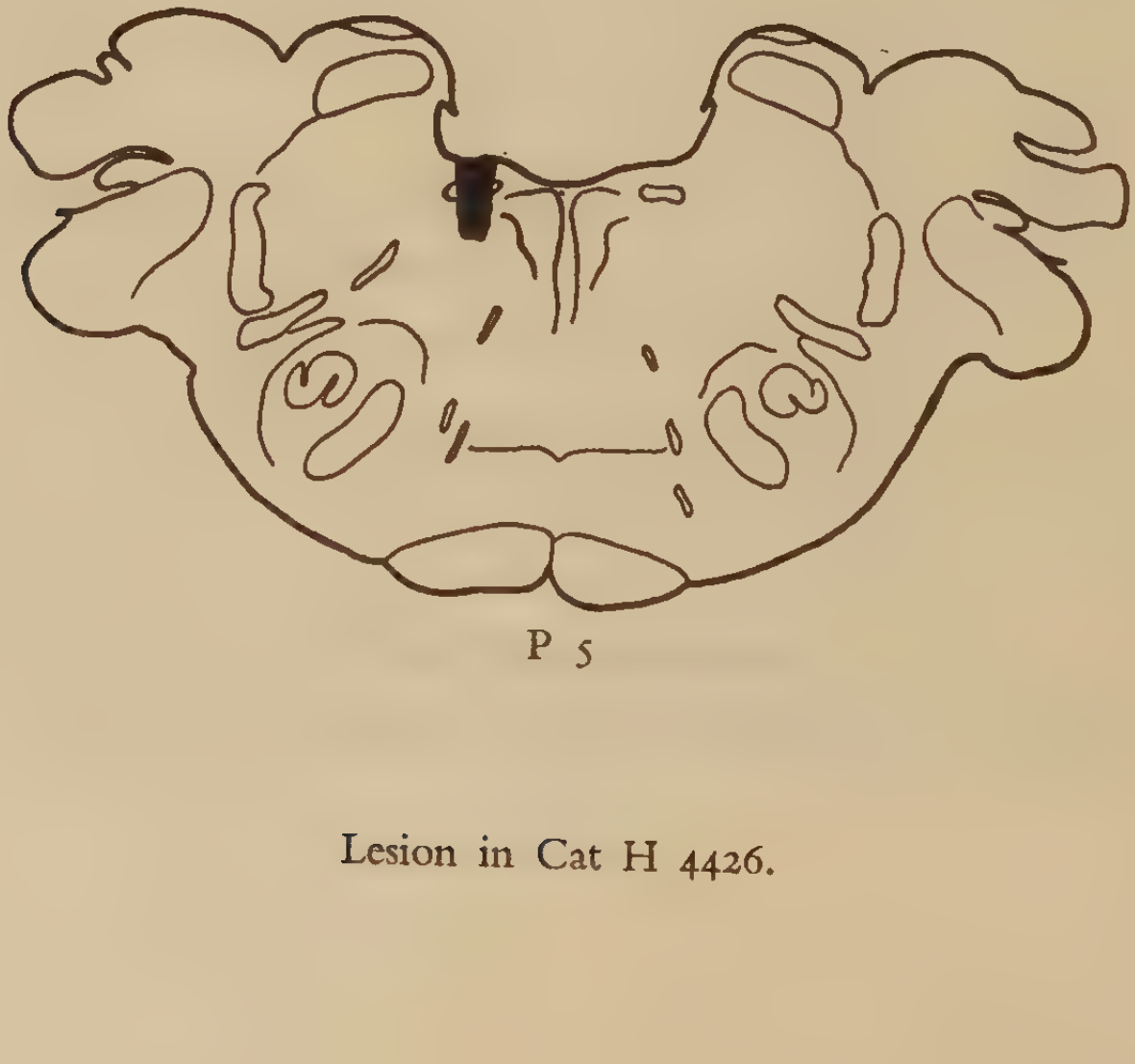

P 5

Lesion in Cat H 4426.

presumably a dendrite of an anterior horn motor neurone. It is located in the most ventral part of lamina 9, the nucleus of the phrenic nerve according to Elliot (1942).

A similar picture can be seen bilaterally in lamina 8; occasionally a preterminal fibre lies at the side of a ganglioncell and can be followed along a vaguely stained processus of this cell.

The C 7 segment. The white matter degeneration of the lateral funiculus comprises a much smaller quantity of fibres than at higher levels; that of the anterior funiculus is about equal to that at those levels.

The grey matter. Degeneration at this level is slight to moderate in intensity. Ipsilateral to the lesion it lies along the dorsomedial border of the anterior horn and can be followed over the adjacent third of the horn. At this side some degeneration can be found within the intermediate grey matter. At the other side the degeneration is restricted to the area along the medial anterior horn border. Besides this, in this segment some degeneration is located at both sides of the central canal.

The low thoracic segment. Degeneration in the white matter is the same as that in the C 7 segment.

Within the grey matter only ipsilateral to the lesion degeneration is visible. It is slight in intensity, and from the medial anterior horn border spreads into the central grey matter.

The L 1 segment. Within the grey matter bilaterally degeneration of slight to moderate intensity is present. Ipsilateral to the lesion it is found from the most ventral part of the anterior horn to very near the central canal. Pericellular degeneration can be seen in lamina 8. At the other side degeneration is seen in the dorsomedial part of the anterior horn; it is of slight intensity.

The L 3 segment. Only in the anterior funiculus degeneration can be seen, it is still fairly distinct.

Within the grey matter bilateral degeneration of slight to moderate intensity is discernable, ipsilaterally it enters the ventralmost tip of the anterior horn and penetrates as far as its base. Occasionally some degeneration is even seen in the intermediate grey matter. At the other side some degeneration proves to occur in the centre of the anterior horn. Besides this some degeneration occurs also in this segment around the central canal bilaterally.

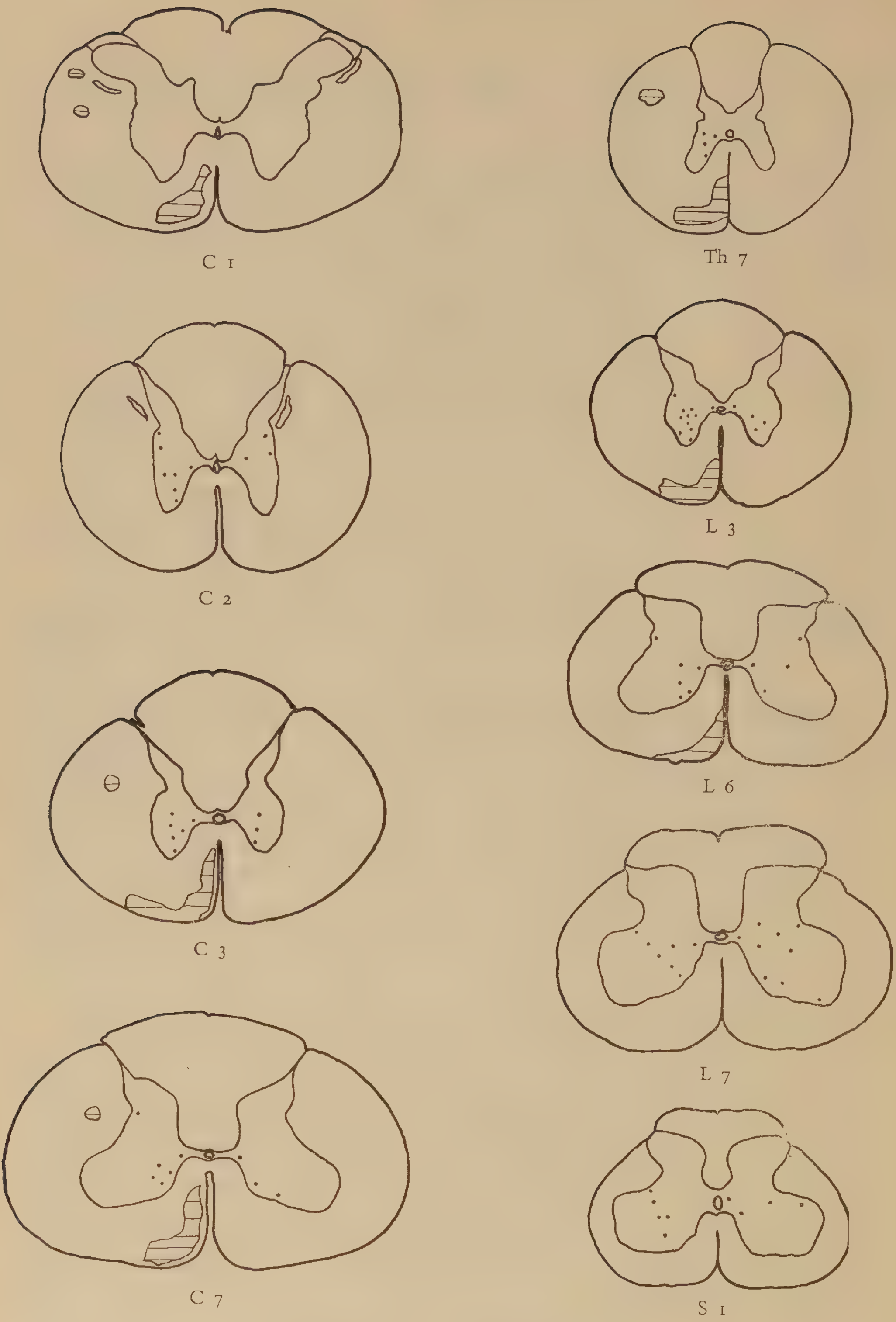

Degeneration in the cord of Cat H 4426.

The L 6 segment. The white matter still contains degenerated fibres in the sulcomarginal fascicle.
Within the grey matter degeneration at both sides is slight in intensity. Ipsilateral to the lesion some degeneration lies along the medial anterior horn border and in its dorsomedial part, whereas also the intermediate grey matter contains some of it. At the other side some degeneration is located both along the medial border of the anterior horn and in its centre. At both sides it spreads to the vicinity of the central canal.
The L 7 segment. Within the grey matter at both sides some degeneration of slight intensity is present. Ipsilaterally it can be followed from the medial anterior horn border to the intermediate and the central grey matter, almost reaching the central canal. At the other side it spreads from the central grey matter over the base of the anterior horn laterally into most of the intermediate grey matter.
Sa segments. The white matter, after careful examination, proves to contain still a few degenerated fibres within the sulcomarginal fascicle. Within the grey matter degeneration still occurs at both sides; it is mostly of slight and only occasionally of moderate intensity.
Ipsilateral to the lesion it is most conspicuous in the centre of the anterior horn, from which it spreads far dorsally into the intermediate grey matter, but ventrally only over a very short distance. Similar to the more rostral segments this one shows some degeneration near the central canal. At the other side the degeneration is spread all over the base of the anterior horn.

SUMMARY

The white matter. Ipsilateral to the lesion moderate degeneration could be followed into the low lumbar segments and slight degeneration into the sacral segments, in the ventral part of the anterior funiculus. Slight degeneration of the lateral funiculus could be followed into the low thoracic cord. Degeneration was confined to the side ipsilateral to the lesion.
The grey matter. All over the length of the cord bilateral praeterminal degeneration due to reticulospinal fibres proved to occur; its intensity varied from moderate to slight. Ipsilateral to the lesion it extended

over a larger area than contralaterally. At the former side it was located as follows:

C 2 segment within the laminae 8, 7 (Nc. cervicalis centralis), 6 and 5.
C 3 segment within the laminae 9 (ventral part, phrenic nerve nucleus), 8 and 7.
C 7 segment and low thoracic cord within the laminae 8 and 10.
L 1 and 3 segments within the laminae 8, 9 (ventral part) and 6.
Sa cord, within the laminae 8 and 7.

Contralateral to the lesion the degeneration was spread diffusely over the laminae 10, 7 and 8, occasionally extending into lamina 6. From the fact that within the white matter degeneration was confined to the side ipsilateral to the lesion whereas in the grey matter it did occur bilaterally, it was concluded that the fibres severed in this experiment, partly, either cross in the cord or give off collaterals which pass the medial line to terminate in the contralateral grey matter. Possibly the degenerated fibres found repeatedly in the vicinity of the central canal can substantiate this supposition.

Cat H 5254

The lesion lies between the planes P 3 and 6, it comprises a large part of the medial reticular formation and only a small part of the adjacent lateral reticular formation. It has its largest extent in the plane P 5, but even there the medial longitudinal fascicle and the predorsal fascicle are entirely untouched. In the planes P 3 and 4 some extension of the lesion towards the lateral corner of the ventricle, caused by the electrode track is present. The survival period was 10 days. Microscopic study of the brain stem revealed that the majority of the medial reticulospinal fibres were severed, also a few crossed ponto-spinal fibres caudal to their crossing, (not depicted in the schemes of the cord) and possibly some fibres of the crossed pontospinal system at their origin. However, in the spinal cord only ipsilateral white matter degeneration was found.

Degeneration within the cord

The degeneration within the white matter will be considered in the summary only.

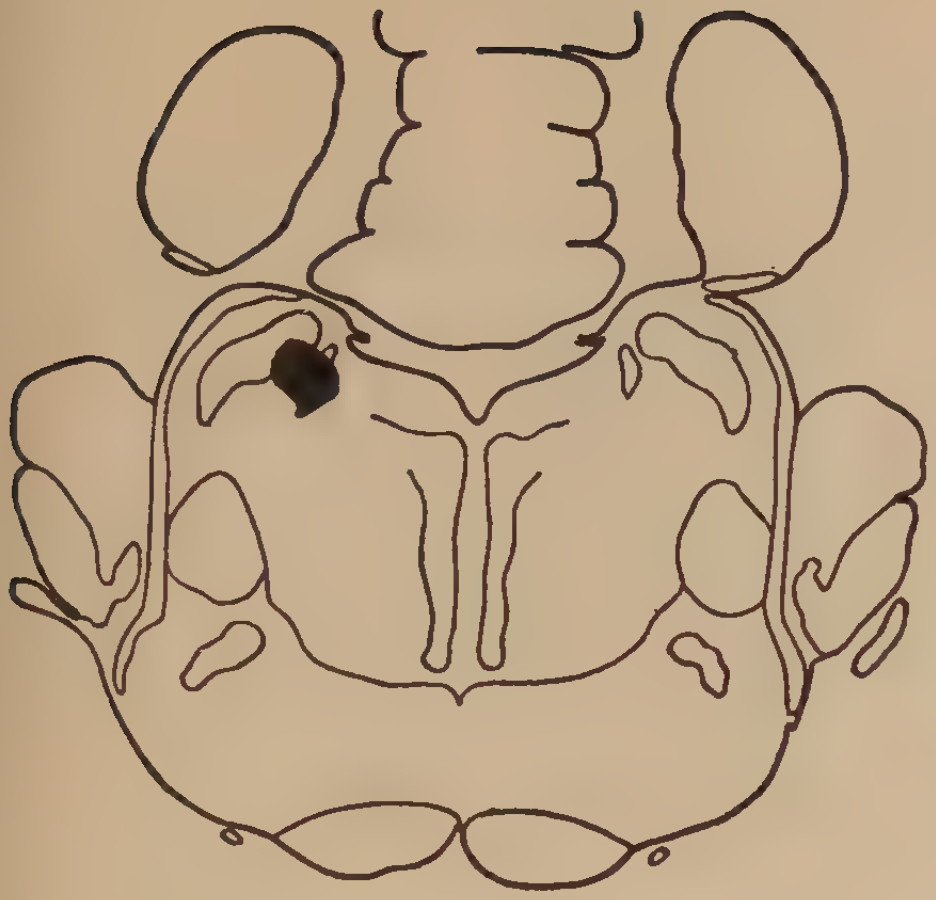

P 3

P 4

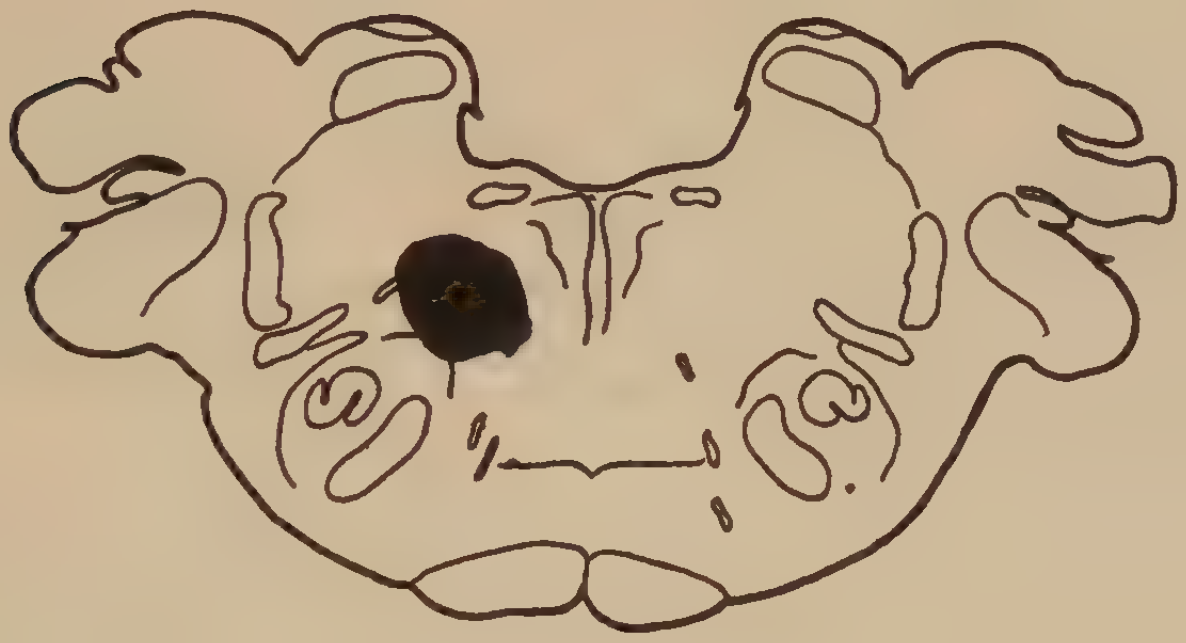

P 5

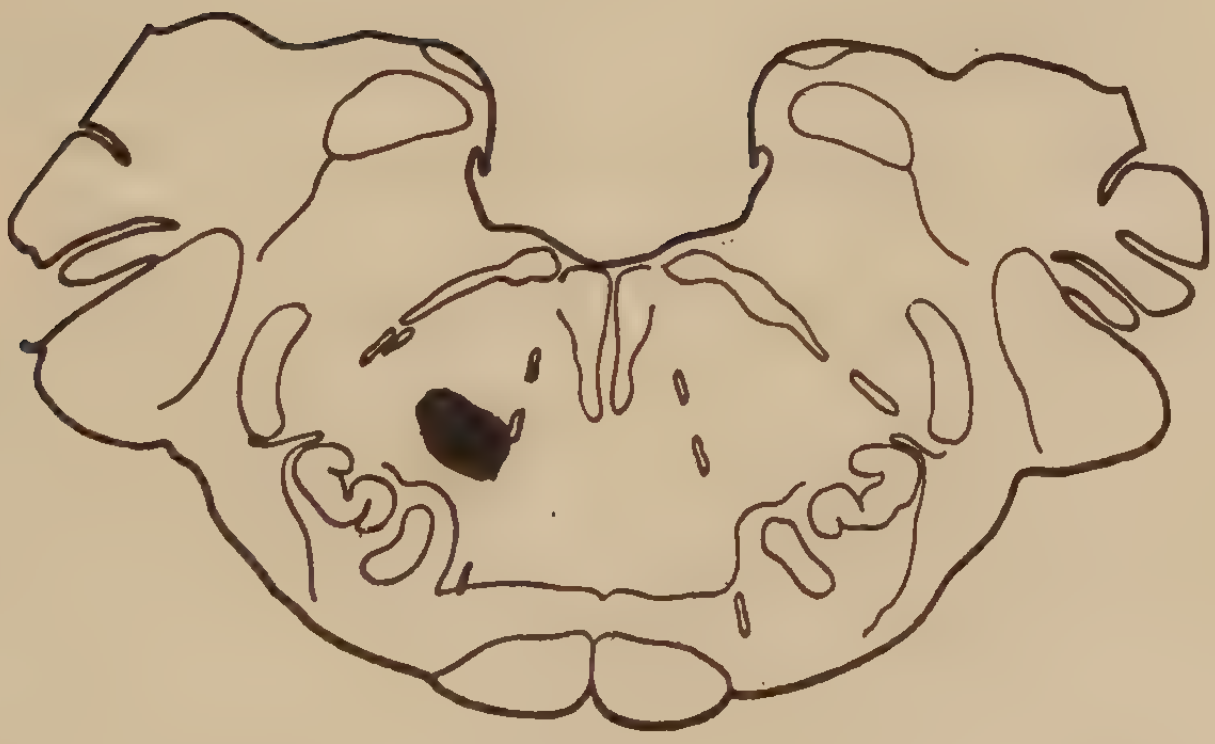

P 6

Lesion in Cat H 5254.

The grey matter

The C 1 segment. Within the grey matter degeneration is exhibited bilaterally, ipsilateral to the lesion it is both more severe and more extensive than contralateral to it. Ipsilaterally degeneration from the ventromedial and ventrolateral sides of the anterior horn invades the whole horn, whereas contralaterally it enters the grey matter along the area of decussation and spreads over the base of the anterior horn only. In many preparations degeneration occurs all around the central canal. Degeneration bilaterally consists of passing disintegrating axons and distinctly impregnated preterminals.

The C 2 segment. As to extension and intensity of the degeneration this segment is similar to the previous one. In the centre of the ipsilateral anterior horn pericellular degeneration is present in a number of preparations.

The C 5 segment. The difference between both halves of the cord is much less marked than in the higher cervical segments, the intensity of the degeneration varies from moderate to strong. It is chiefly confined to the medial half of the anterior horns. Degeneration around the central canal is unchanged.

The C 7 segment. At the ipsilateral side degenerated fibres enter the anterior horn at its ventromedial corner, and spread over a cuneiform area extending over about two thirds of the width of the horn. The intensity of degeneration is moderate to strong, within its area pericellular degeneration is common. Degenerated fibres can be followed through the zone of decussation to the contralateral anterior horn where they occupy the medial half. Degeneration here shows a slight to moderate intensity.

The lower thoracic segments. At this part of the cord the difference between both sides of the cord with regard to the degeneration is marked, as contralateral to the lesion it is confined to the dorsal part of the anterior horn and is only slight in intensity. Ipsilaterally it is very strong in intensity and lies in the base of the anterior horn. In its lateral part pericellular degeneration is distinctly visible.

The L 3 segment. In the ipsilateral anterior horn degeneration is strong in intensity, and pericellular degeneration is fairly common. Contralaterally it is confined to the dorsomedial part of the anterior horn and

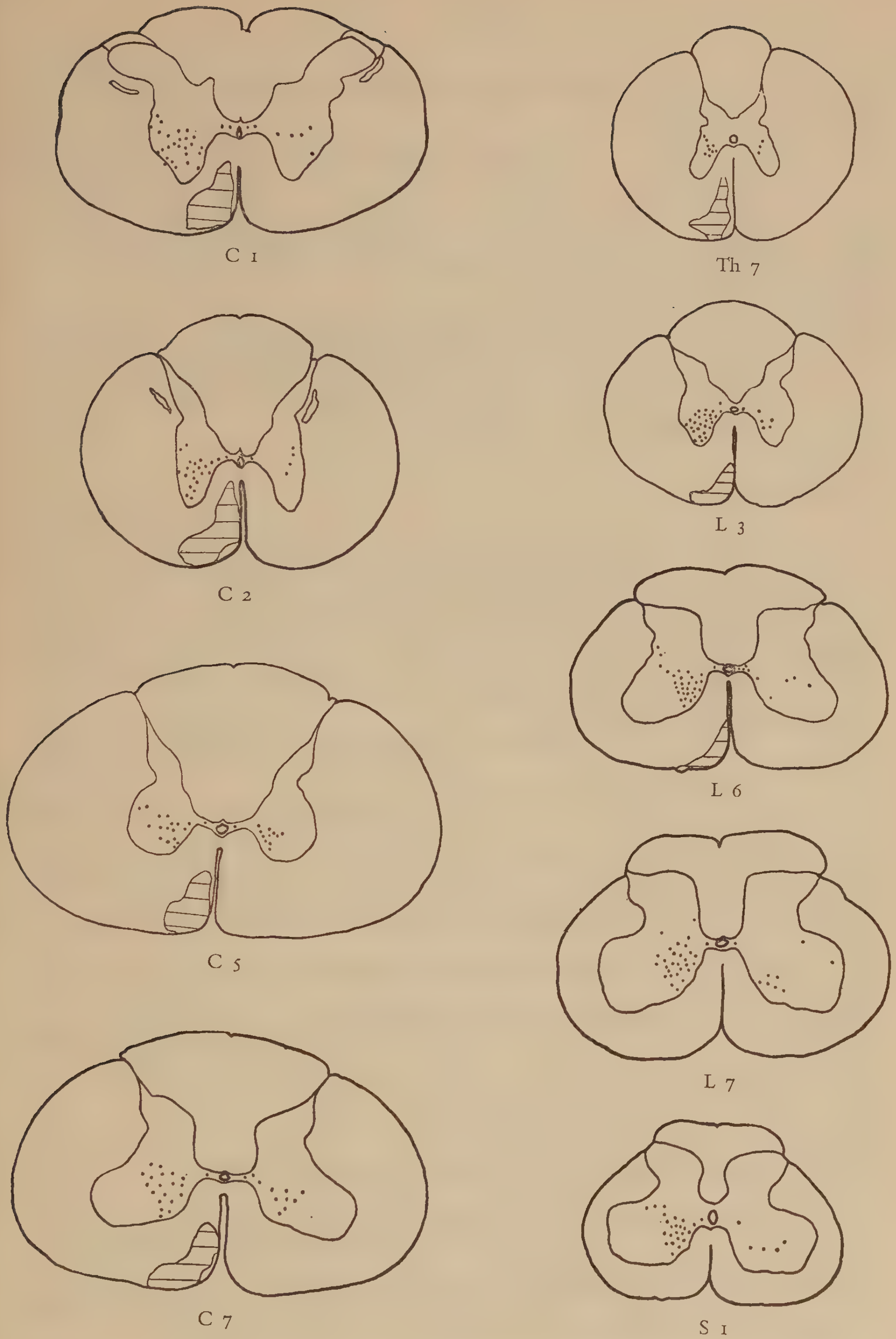

Degeneration in the cord of Cat H 5254.

shows only a slight intensity. Degeneration is also present at both sides of the central canal.
The L 6 segment. Strong intensity degeneration is visible ipsilaterally within a triangular area with the medial anterior horn margin as its base. It extends relatively deeply into the intermediate grey matter. Slight intensity degeneration exists around the central canal and within the contralateral anterior horn.
The L 7 and Sa 1 segments present the same pictures as the L 6 segment.
The Sa 3 segment. Slight to moderate degree of degeneration is visible within the lateral part of the horns (not depicted in the scheme).

SUMMARY

Ventromedial in the ipsilateral anterior fascicle an area could be found in which a great number of fibres was degenerated, the site of which corresponded with that in the former experiment (4426). However, the number of degenerated fibres was greater. The degeneration could be followed into the L 6 segment; below the C 7 segment the degeneration was considerably diminished.
The grey matter showed bilateral degeneration throughout the spinal cord; it was most conspicuous ipsilateral to the lesion. As in Häggqvist stained slides degeneration of the white matter proved to be ipsilateral only, whereas around the central canal and in both anterior horns it was present in all segments, it can be concluded that part of the medial reticulospinal fibres or their collaterals cross at all levels of the cord.

The ipsilateral degeneration of the grey matter was located as follows:

in the C 1, 2 and 5 segments within the laminae 7, 8, 9 and 10;
in the C 7, L 6 and 7 and the Sa 1 segments within the laminae 7, 8 and 10;
in the caudal thoracic segments within the laminae 7 and 8;
and in the L 3 segment in the laminae 8, 9 and 10.

The contralateral degeneration was located as follows:

in the C 1 and 5 and in the L 3 segment within the laminae 8 and 10;
in the C 7, L 6 and 7 segments within the laminae 7, 8 and 10;
in the C 2 segment within the laminae 7 and 10;
in the caudal thoracic cord and the Sa 1 segments within lamina 8.

Within the ipsilateral areas of degeneration pericellular degeneration was repeatedly found.

Cat H 4869

The lesion is confined to plane P 9, and comprises a small area of the medial reticular formation, close to the intermediate third of the medial longitudinal fascicle, without touching it. The electrode tract, however, caused a small lesion just ventral to the ventricular ependym. The animal was killed 10 days after the operation.
Microscopical examination of the medulla in the level of the lesion and caudal to it revealed that ipsilateral to the lesion, the medial reticulo-spinal fibres and a very small number of medial vestibulospinal fibres were degenerated.
Contralateral to the lesion only fibres from the crossed bulbo-spinal tract, originating at the side of the lesion were degenerated. These fibres were damaged before their crossing the midline. Besides the few severed ipsilateral vestibulospinal fibres, degeneration of the white and the grey matter of the spinal cord could be attributed entirely to fibres from the reticular formation of the medulla.

The degeneration within the spinal cord

In a caudal pyramidal crossing level, the ipsilateral grey matter exhibits a strong intensity degeneration which spreads from the medioventral anterior horn portion all over the horn almost to the posterior commissure. Pericellular degeneration is present in the ventral, medial, central and dorsolateral parts of the anterior horn. Contralateral to the lesion only slight intensity degeneration is seen, confined to the dorsomedial part of the anterior horn.
The C 1 segment. Within the white matter ipsilateral to the lesion many degenerated fibres are located in the whole sulcomarginal fascicle and the ventrolateral part of the anterior funiculus; the area of degeneration is extending to the ventral border of the antero-lateral funiculus. Somewhat more laterally also some scattered degenerated fibres are found, not depicted in the scheme. Contralateral to the lesion the area of degenerated fibres reaches less far dorsally within the sulcomarginal

P 9

Lesion in Cat H 4869.

fascicle and less far laterally. Within the grey matter ipsilaterally to the lesion, there is a moderate degree of degeneration entering the anterior horn at both sides of its most ventral tip. It spreads over the whole medial half of the horn and can be followed into the ventral part of the intermediate grey matter. Pericellular degeneration is present in lamina 8 and in the dorsomedial part of lamina 7.

Contralaterally some very slight intensity degeneration is located in the ventrolateral part of the anterior horn.

The C 2 segment. Grey matter degeneration ipsilateral to the lesion, slight to moderate in intensity, is located in the medial half of the anterior horn, extending to the base and also somewhat laterally. Contralaterally some very slight intensity degeneration lies dorsomedially within the anterior horn.

The C 3 segment. Degeneration within the white matter is almost equal to that in the C 1 segment.

Within the grey matter ipsilateral to the lesion degeneration is much more marked than contralaterally. At the former side it shows a moderate to strong intensity over the medial two thirds of the anterior horn. Laterodorsally it extends somewhat into the ventral part of the intermediate grey matter and dorsally to the central grey matter. A degeneration of slight intensity extends into the lateral third of the anterior horn, whereas pericellular degeneration is located in lamina 8. At the contralateral side slight intensity degeneration lies both in the medioventral part of the anterior horn and the intermediate grey matter.

The C 6–7 segments. At this level degeneration in the grey matter is similar in intensity to that in the C 3 segment, however, it is restricted to the medial part of the anterior horns.

The C 7 segment. Within the white matter the ipsilateral degeneration is about unchanged; contralaterally it is restricted to a small area of the medioventral corner of the anterior funiculus.

Within the grey matter the area of degeneration within the anterior horn is much smaller, the difference between both sides is less marked. Ipsilaterally degenerated fibres from the medioventral corner can be followed over some distance into the medial half of the anterior horn. At the other side degeneration is confined to a strip along the dorsal part of the medial anterior horn margin.

The caudal thoracic segments. Within the white matter at both sides degenerated fibres have decreased in number considerably, but their site is unchanged.
Within the grey matter ipsilateral to the lesion, a slight to moderate intensity degeneration is located in the dorsal and central parts of the anterior horn; contralaterally some slight intensity degeneration lies in its dorsal part only.
The L 1 segment. Within the white matter at one side still a few degenerated fibres are present in the ventral part of the anterior funiculus.
The L 3 segment. At this level and similarly at more caudal levels in the Häggqvist preparations of the white matter degenerated fibres cannot be found any more. Within the grey matter ipsilateral to the lesion slight to moderate intensity degeneration lies along the whole base of the anterior horn. At the other side only some very slight intensity degeneration is located in the mediodorsal part of the anterior horn.
The L 6 segment. Within the grey matter degeneration is of slight intensity only; it can be followed from the medial anterior horn margin to its centre and base and at both sides is about equal in extension.
The L 7 segment. At both sides within the grey matter slight intensity degeneration is located in the medial half of the anterior horn; ipsilateral to the lesion its area surpasses that of the other side somewhat in size.
The Sa and Co segments. The grey matter in some of the preparations shows sporadic degenerated fibres in the anterior horn (not depicted in the scheme).

SUMMARY

The white matter down to the low thoracic cord showed degenerated fibres in both anterior funiculi; at all levels the area they were found in, was larger at the side ipsilateral to the lesion than at the other side. In the whole cervical cord the areas were relatively large, comprising nearly the whole anterior funiculus, to the border of the anterolateral funiculus. In the thoracic segments degenerated fibres were much less numerous and in the L 1 segment they were reduced to very few within the ipsilateral anterior funiculus only.
The grey matter ipsilateral to the lesion presented a moderate to strong

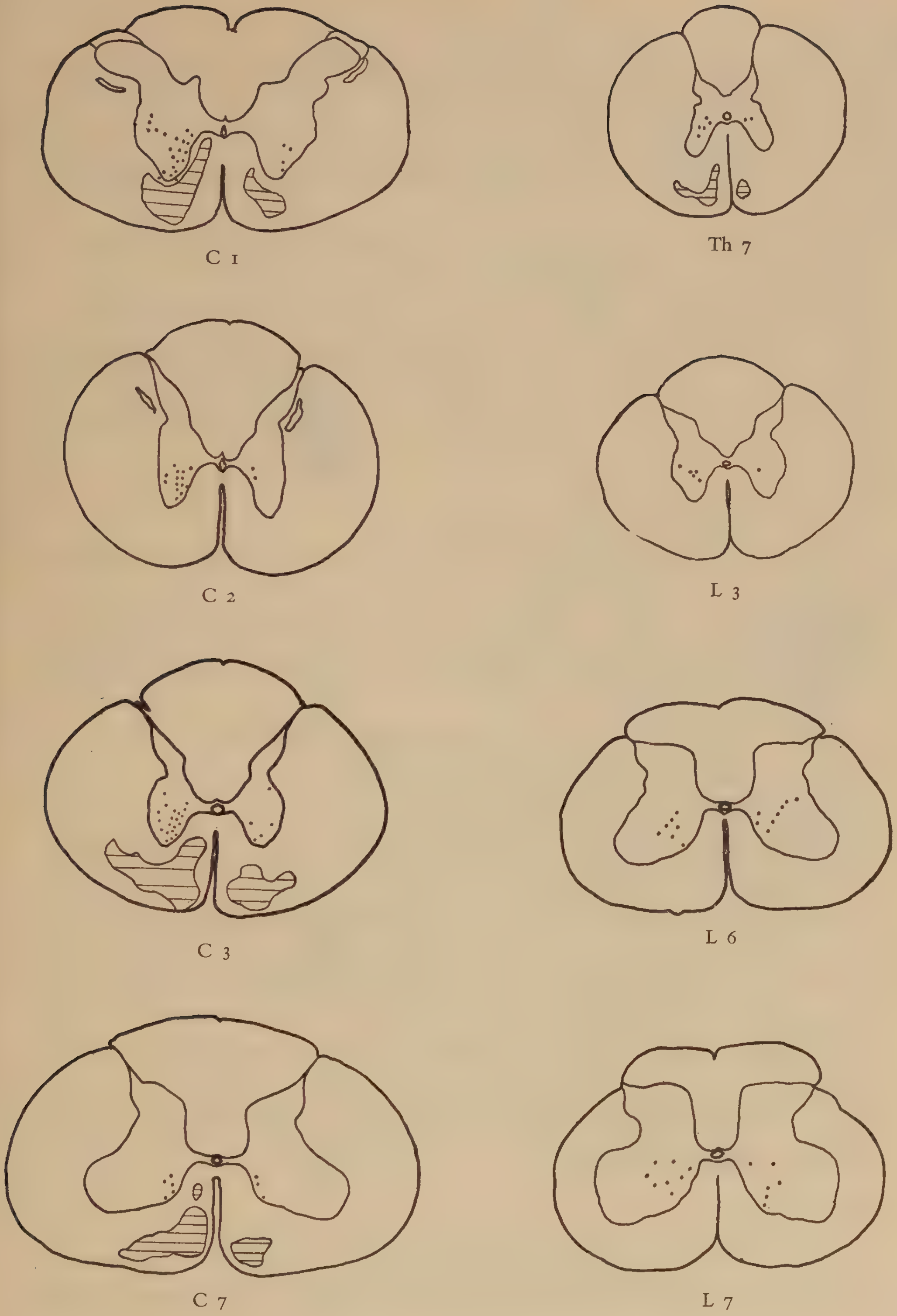

Degeneration in the cord of Cat H 4869.

intensity degeneration in which repeatedly pericellular degeneration was obvious. It was localized as follows:
in the C 1 segment within the laminae 9 and 8 and the ventral part of lamina 7 (a.o. the nuclei ventromedialis, commisuralis and centrodorsalis);
in the C 2 segment within lamina 8 and the ventral part of lamina 7 (a.o. in the nucleus commissuralis);
in the C 3 segment within the laminae 8 and 7 and the ventral part of lamina 6 (a.o. the nucleus ventromedialis). Caudal to this level ipsilateral degeneration was only slight in intensity, the caudal thoracic and the rostral lumbar segments excepted where it was of slight to moderate intensity.
It was localized as follows:
in the C 7 segment within lamina 8;
in the low thoracic segments and the L 3 segment within the laminae 8 and 7;
in the L 6 and 7 segments within lamina 8 and the ventral part of lamina 7.
Contralateral to the lesion degeneration was of slight intensity only, it was located as follows:
in the C 1, 2 and 7 and the L 3 segments within lamina 8;
in the C 3 segment within the laminae 8 and 6;
in the low thoracic cord within lamina 7;
in the L 6 and 7 segments within the laminae 8 and 7. In the sacral and coccygeal segments degeneration was too sporadic to be considered.
It should be kept in mind that the heterolateral degeneration in the grey matter cannot be entirely attributed to fibres derived from the crossed bulbo-spinal tract, because as already reported, the experiments H 4426 and 5254 showed that part of the fibres of the medial reticulo-spinal tract, or their collaterals, cross in the cord before terminating. However, it may be stated that, some vestibular fibres excepted, all degenerated fibres of the cord in this experiment originate in the reticular formation of the brainstem.

Cat H 4871

The lesion lies between the planes P 9 and 12, it is largest in plane P 11. The lesion comprises the dorsal part of the lateral reticular formation,

P 9

P 10

P 11

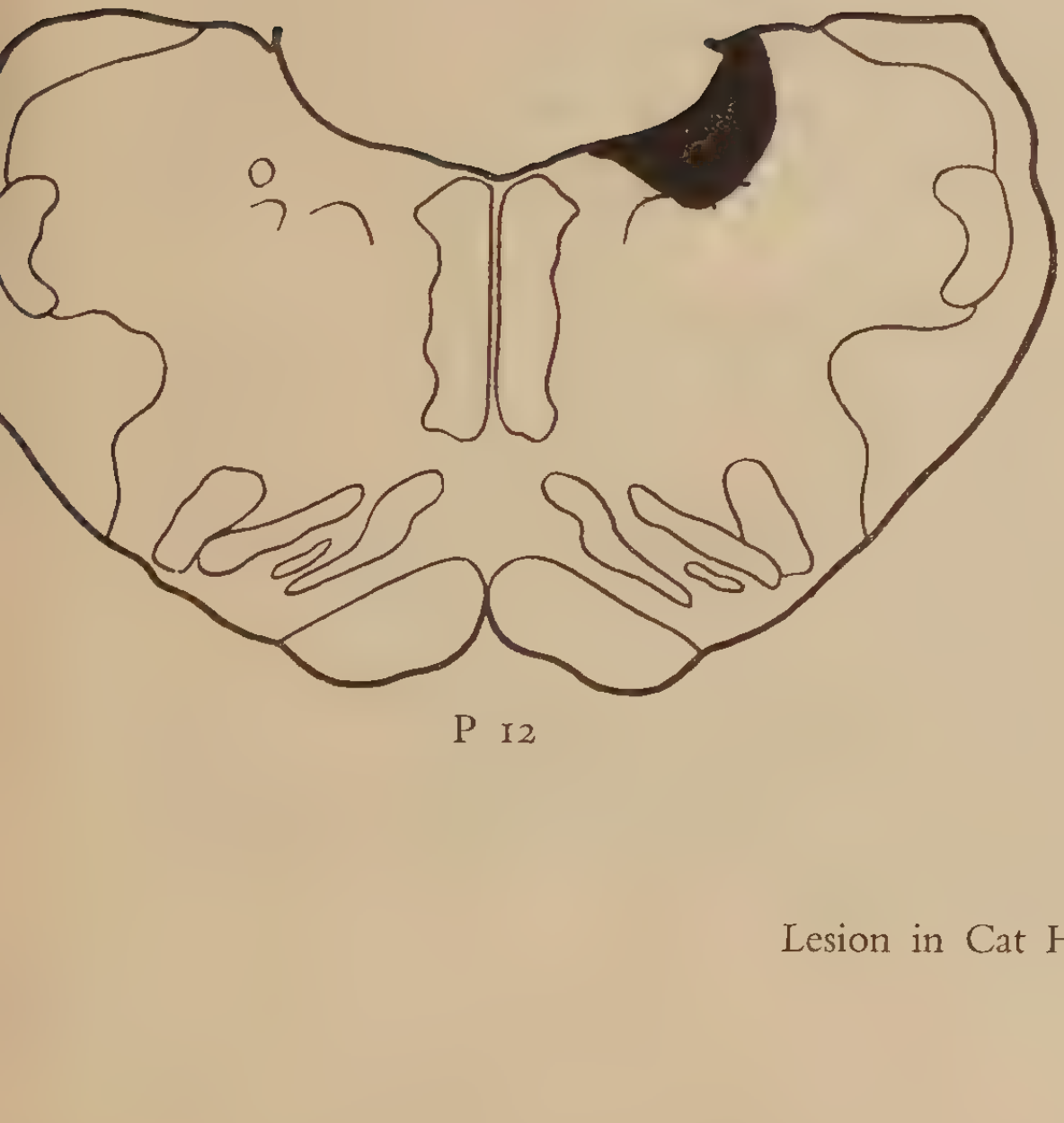

P 12

Lesion in Cat H 4871.

without encroaching upon the medial reticular formation and the medial longitudinal fascicle. The animal was killed 11 days after the operation. On microscopical examination of the medulla it appeared that part of the uncrossed lateral bulbospinal fibres (of Thomas' fascicle) and of the crossed bulbospinal fibres were severed. The latter were severed at their origin or just thereafter, in any case before they crossed the midline. With the exception of a small number of uncrossed vestibulospinal fibres which also were severed, the degeneration of the cord could be attributed to fibres from the reticular formation.

Degeneration within the spinal cord

The C 1 segment. At both sides degenerated fibres are located in the anterior funiculus and in much smaller numbers in the anterolateral funiculus. Contralateral to the lesion fibres in both funiculi are considerably more numerous than ipsilaterally. Contralaterally they lie chiefly along the medial margin of the anterior horn and ipsilaterally they also occur along its lateral margin. The areas they occur in, however, cannot be sharply circumscribed, and outside it, degenerated fibres are also visible though only rarely.

Within the grey matter degeneration lies chiefly contralateral to the lesion, where it is of moderate to strong intensity. It occupies almost the entire anterior horn and extends to the ventral part of the intermediate grey matter; it is strongest in intensity in the ventral anterior horn half. Degenerated fibres can be located along the motor anterior horn cells and their processus, repeatedly. Apparently they enter the anterior horn by its lateroventral- and ventral borders. Ipsilaterally, within the ventral part of the anterior horn some degeneration of slight intensity can be identified.

The C 2 segment. Within the grey matter the picture is about identical with that of the C 1 segment, degeneration in the ipsilateral anterior horn however is somewhat more marked, and lies more laterally. Contralateral to the lesion the ventral half of the anterior horn shows some pronounced pericellular degeneration.

The C 3 segment. Within the white matter degenerated fibres lie at the same sites as in the C 1 segment, but they have diminished markedly in number. Within the grey matter contralateral to the lesion, moderate

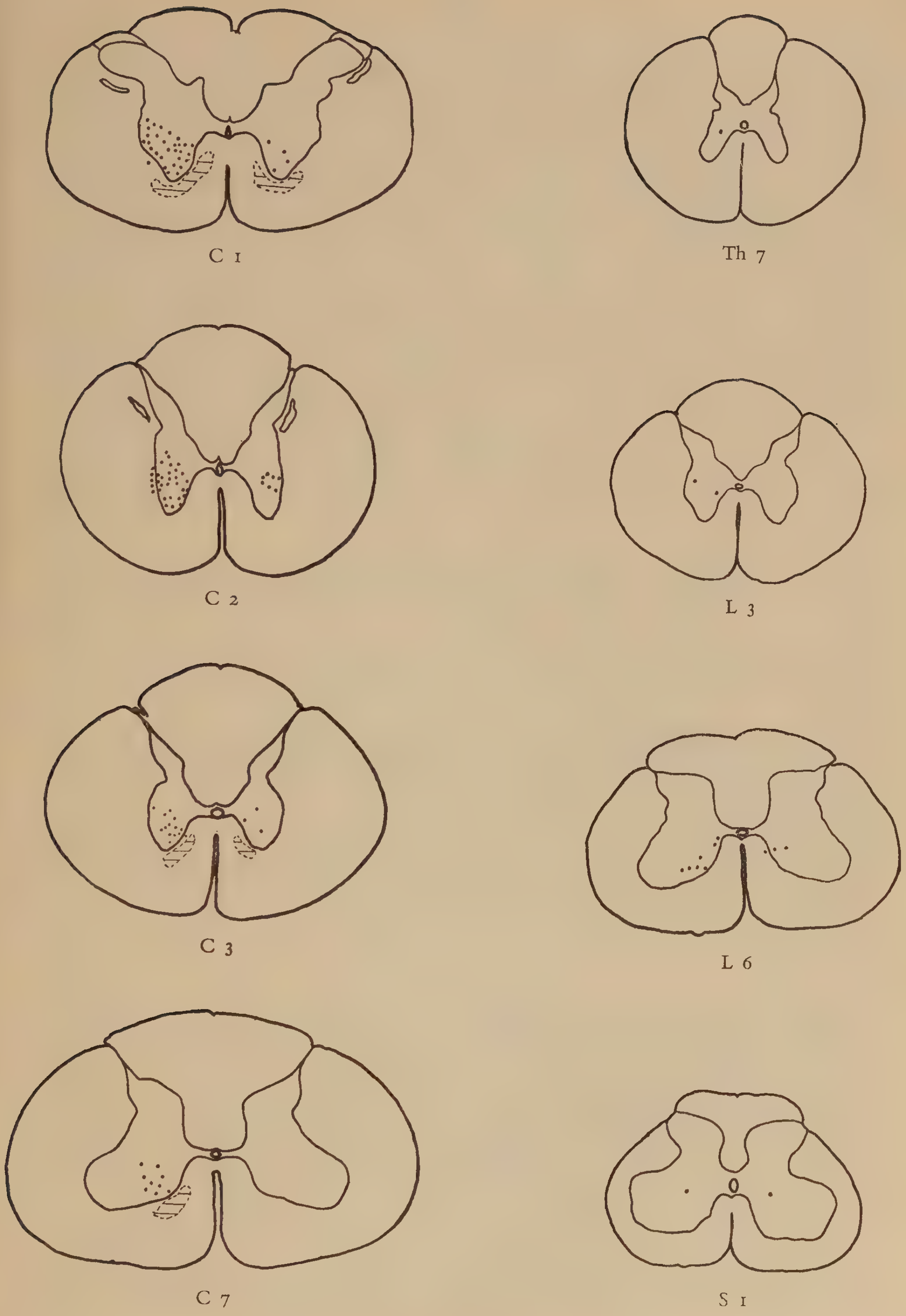

Degeneration in the cord of Cat H 4871.

intensity degeneration is visible in the medial anterior horn half, with some slight extension into the lateral half. At the other side some slight intensity degeneration is located in its medial half only.

The C 7 segment. Within the white matter degenerated fibres can be found only along the contralateral medial anterior horn margin at its transition to the ventral margin. Within the grey matter similarly it is confined to the contralateral side, an occasional preparation excepted, that shows also some degeneration at the other side. It is slight to moderate in intensity and from the site of the white matter degeneration along the margin of the anterior horn, spreads dorsolaterally to its centre.

The low thoracic segments. Within the white matter degenerated fibres can no longer be distinguished. Within the grey matter only contralaterally a slight intensity degeneration is present in the dorsal part of the anterior horn.

The L 3 segment. Within the grey matter only contralaterally some scanty degeneration of slight intensity lies at the base of the anterior horn.

The L 6 segment. Contralaterally and in several preparations bilaterally, some slight intensity degeneration is found in the medial anterior horn half.

The L 7 segment. Within the grey matter occasionally some scanty degeneration is found along the medial margin of the anterior horns (not depicted in the scheme).

The Sa segments. In some preparations the grey matter presents slight intensity degeneration in the medial part of the base of both anterior horns.

SUMMARY

Within the white matter in the high cervical cord bilaterally along the medial anterior horn borders, degenerated fibres were found, with a small number of such fibres along the lateral borders. At the C 7 segment degeneration occurred only contralateral to the lesion and, more caudally within the white matter, degenerated fibres were no more visible in Häggqvist stained preparations. In this particular experiment areas of degenerated fibres could not be demonstrated as the affected fibres were widely spread over a relatively large area, among many normal fibres of other origins. This was indicated in the schemes by a dotted line delinea-

tion. Within the grey matter almost all over the length of the cord preterminal degeneration proved to be present, contralateral to the lesion much more pronounced than at the other side. Its intensity in the high and middle cervical cord amounted to moderate and strong, in lower levels only to slight. As already alluded to, the degenerated fibres, a few vestibular ones excepted, belonged to those originating in the bulbar reticular formation.

Localization of the degeneration was as follows:

in the C 1 and 2 segments within lamina 8, the lateral part of lamina 7 and both parts of lamina 9 (nuclei ventromedialis and spinalis nervi accessorii), in the C 2 segment moreover pericellular degeneration was found in the area of the nucleus ventromedialis;

in the C 3 and 7 segments within lamina 8 and in the ventral part of lamina 7;

in the low thoracic and the L 3 segments, within lamina 7;

in the L 6 and the Sa segments within lamina 8.

Cat H 3519

The lesion is located between plane P 1 and P 4, with its largest extension in plane P 3. It lies mostly in the lateral reticular formation but encroaches upon the medial reticular formation. It involves the entire central reticular fasciculus. Two electrode tracks leave the lesion in a dorsal direction, i.e. through the medial tip of the brachium conjunctivum and the mesencephalic branch of the nervus trigeminus and through the lateral tip of the brachium conjunctivum. Laterally it comprises the lateral lemniscus and the rubrospinal fibres. The animal was killed 20 days after the operation (Cat P 1 of Busch).

On microscopical study of the pons and the medulla it was proved that ipsilateral to the lesion the rubrospinal fibresystem and pontine fibres from the medial reticulospinal tract were degenerated. Contralateral to the lesion only fibres from the crossed pontospinal system showed signs of degeneration. In this animal unfortunately only the cervical cord was available for examination.

Degeneration within the spinal cord

Within the white matter, of the C 2 segment, contralateral to the lesion

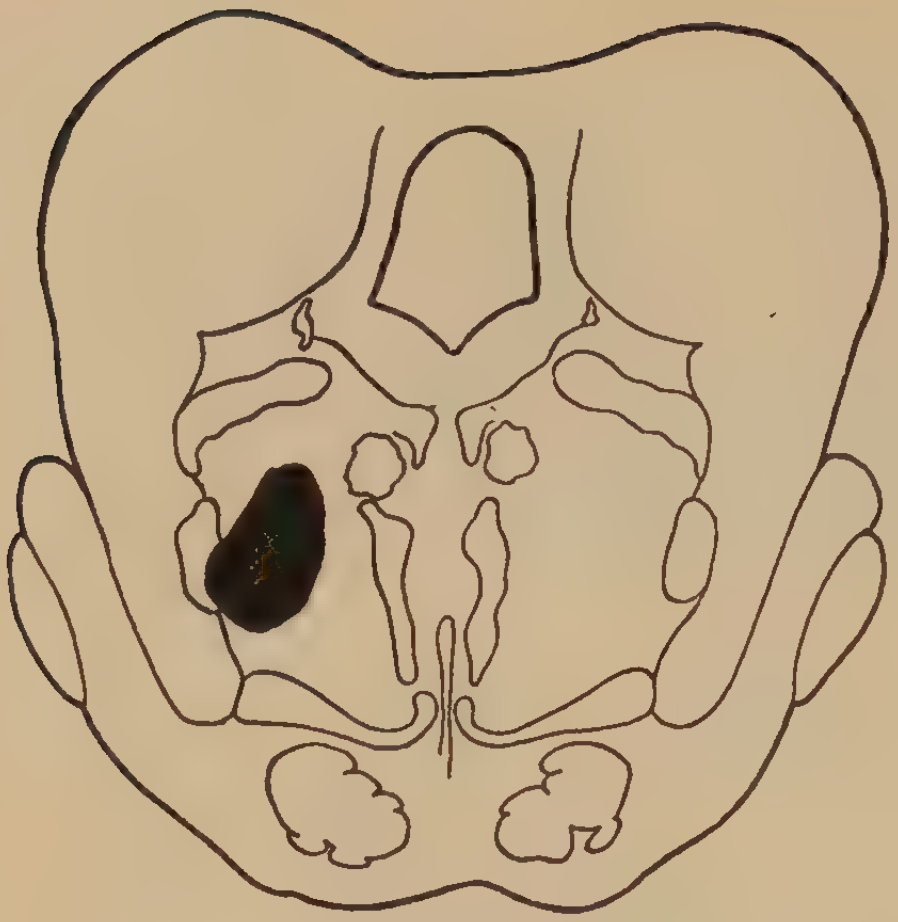

P 1

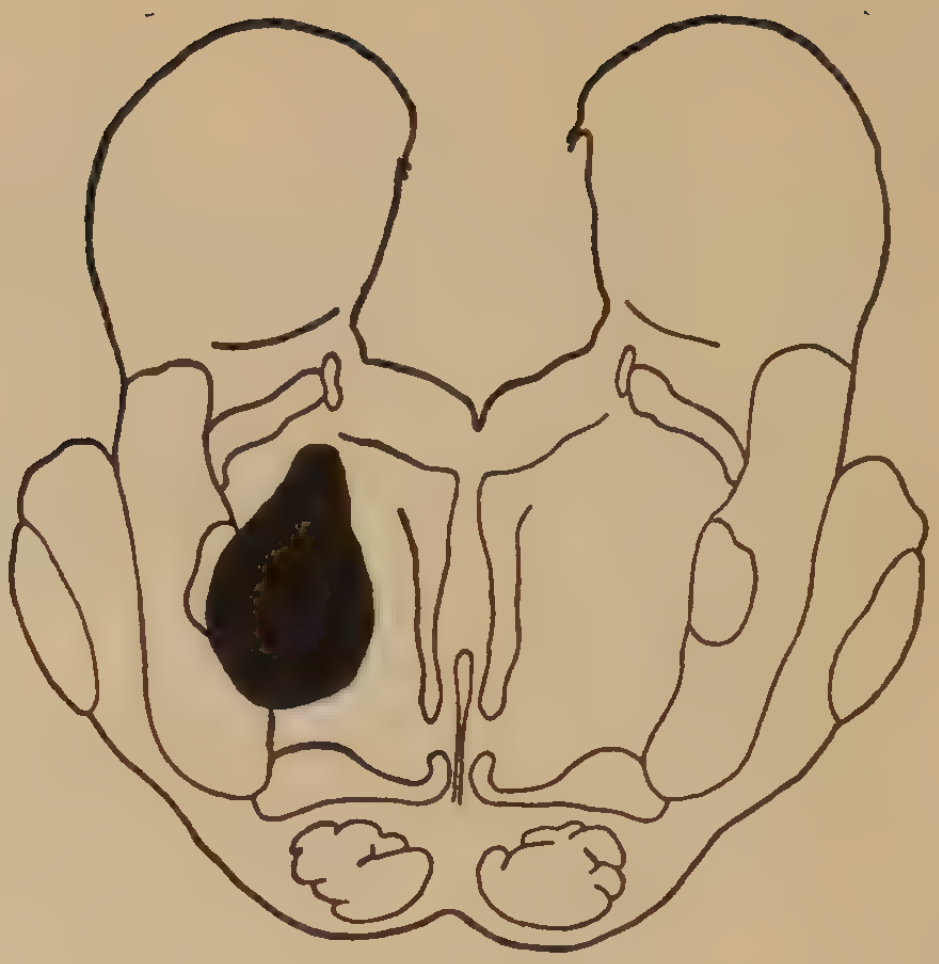

P 2

P 3

P 4

Lesion in Cat H 3519.

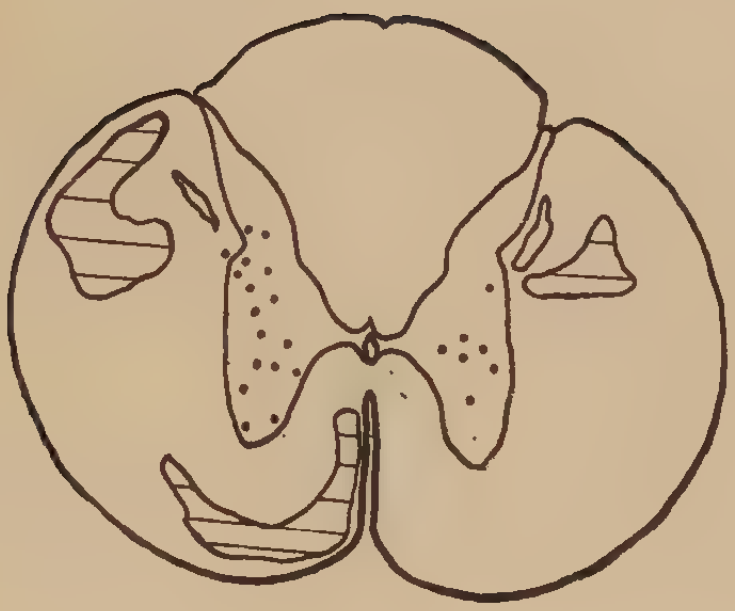

C 2

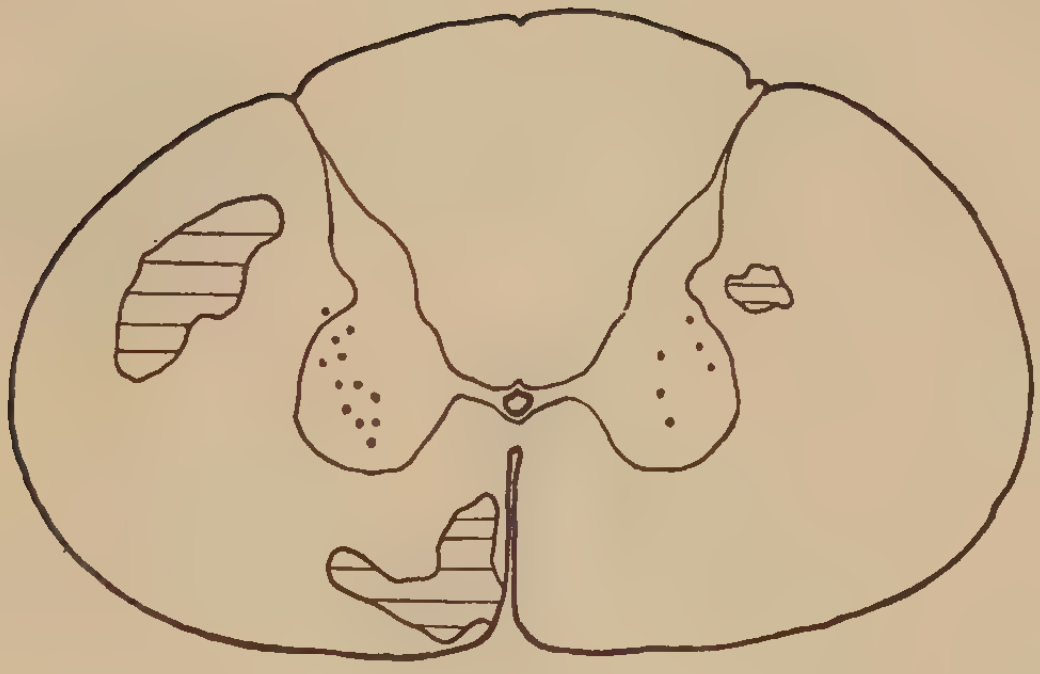

C 5

Degeneration in the cord of Cat H 3519.

a small area of degenerated fibres lies in the dorsal part of the lateral funiculus; at the other side there are two degeneration areas, one in the dorsolateral funiculus and the other in the ventral part of the anterolateral funiculus.

In the C 5 segment contralateral to the lesion degenerated fibres have considerably decreased in number.

Within the grey matter degeneration is only of interest at the side contralateral to the lesion, as at the other side it is of mixed origin. That at the contralateral side is derived exclusively from the pontine reticular formation because, as already demonstrated, rubrospinal fibres, contrary to reticular fibres from the pons, do not cross in the cord. Degenerated crossed lateral pontospinal fibres and medial reticulospinal fibres or their collaterals, in this experiment are located in the laminae 6, 7 and 8.

Cat H 3882

The lesion lies between the planes P 7 and 10, it comprises a large part of the medial reticular formation with the adjacent part of the lateral reticular formation, and does not damage the medial longitudinal fascicle. The electrode track passes through the medial vestibular nucleus, somewhat caudal to the facial genu (Cat B 3 of Busch). The animal was killed 19 days after the operation.

On microscopical study of the medulla, degeneration was found in the following systems descending into the spinal cord:

1. uncrossed reticulospinal fibres in the anterolateral funiculus;
2. uncrossed vestibulospinal fibres in the sulcomarginal fascicle;
3. part of the fibres from Deiters' nucleus (uncrossed);
4. pontine reticulospinal fibres in the lateral funiculus, severed caudal to their crossing;
5. uncrossed bulbospinal fibres of Thomas' fascicle;
6. the crossed bulbar reticulospinal system, representing the only crossed fibresystem. These fibres were severed before their crossing, at their origin and just thereafter.

Degeneration within the spinal cord

Contralateral to the lesion within the white matter, degeneration is

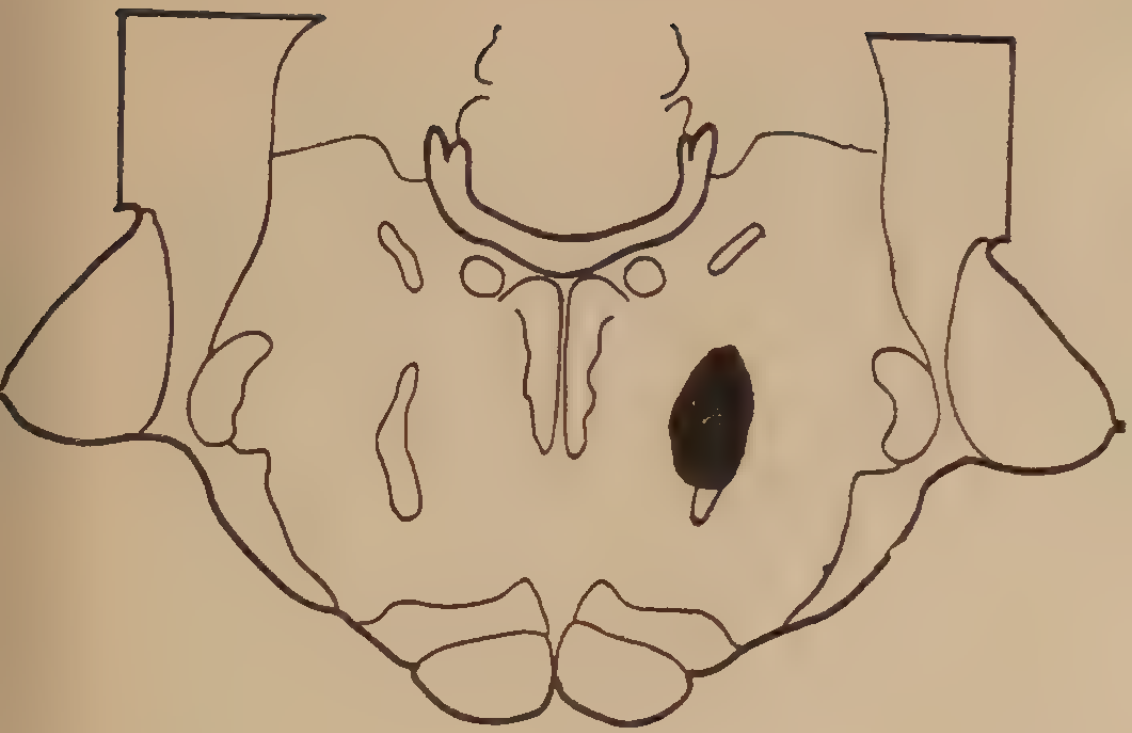

P 7

P 8

P 9

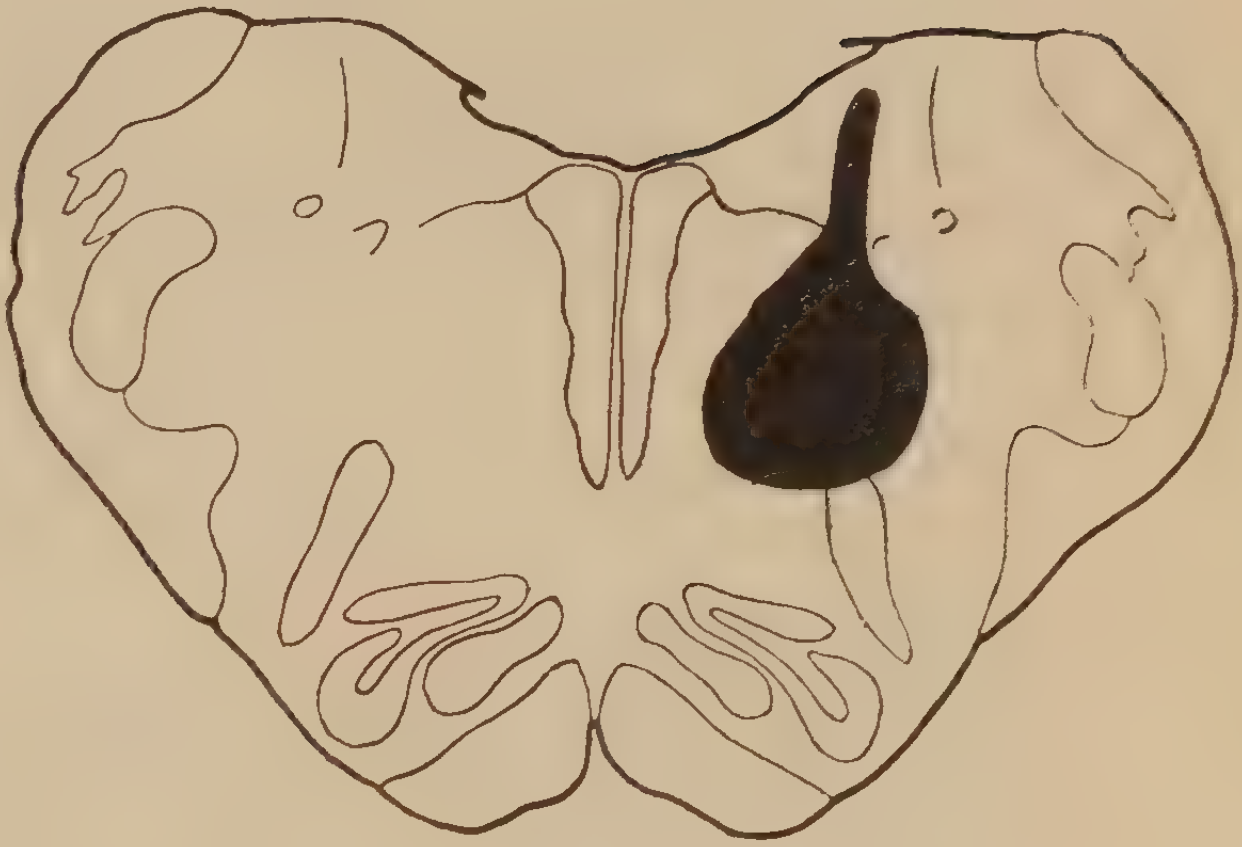

P 10

Lesion in Cat H 3882.

present in the sulcomarginal fascicle, expanding along the ventral border of the anterior horn into the anterolateral funiculus. Ipsilateral degeneration within the white matter in this experiment is of secondary interest. It comprises a large area including the sulcomarginal fascicle, and a relatively large part of the antero- and postero-lateral funiculi. Bilaterally the areas of degeneration are poorly circumscribed because the degenerated fibre-contingent only very gradually diminishes at their periphery and even in the apparently normal white matter several small groups of degenerated fibres occur.

The areas of degeneration can be followed essentially unchanged into the high thoracic segments, but in the low thoracic cord degeneration in the posterolateral funiculus is no longer found. In the high lumbar segments degeneration is still visible in the antero-lateral funiculi but as the preparations were somewhat damaged it is not depicted in the schemes. In the L 6 and 7 segments areas of degeneration are no longer existent but in the anterior funiculi some scattered degenerated fibres still occur.

Degeneration of the grey matter will be considered only at the side contralateral to the lesion, attributable to the crossed bulbar reticulospinal system and partly to ipsilaterally descending reticulospinal fibres that cross at their level of termination (Experiments H 4426 and 5254.) Of the other systems involved it has never been proved that they cross entirely or even partly during their descent through the cord.

In the C 5 segment degeneration of slight to moderate intensity is present all over the anterior horn, the intermediate and the central grey matter, the ventral margin of the anterior horn and the dorsal part of its medial margin. Within lamina 8 (along the medial margin) pericellular degeneration is common, but it is absent in the phrenicus nerve nucleus. In the C 7 segment degeneration of moderate intensity is chiefly found in the medial anterior horn half, as in the intermediate grey matter it is very scanty.

In the low thoracic segments degeneration of slight intensity is found only in the medial anterior horn half, whereas in the L 3 segment it is moderate in intensity and located in the base and the medial half of the anterior horn. In the L 6 segment it is of slight intensity again and restricted to the medial anterior horn half.

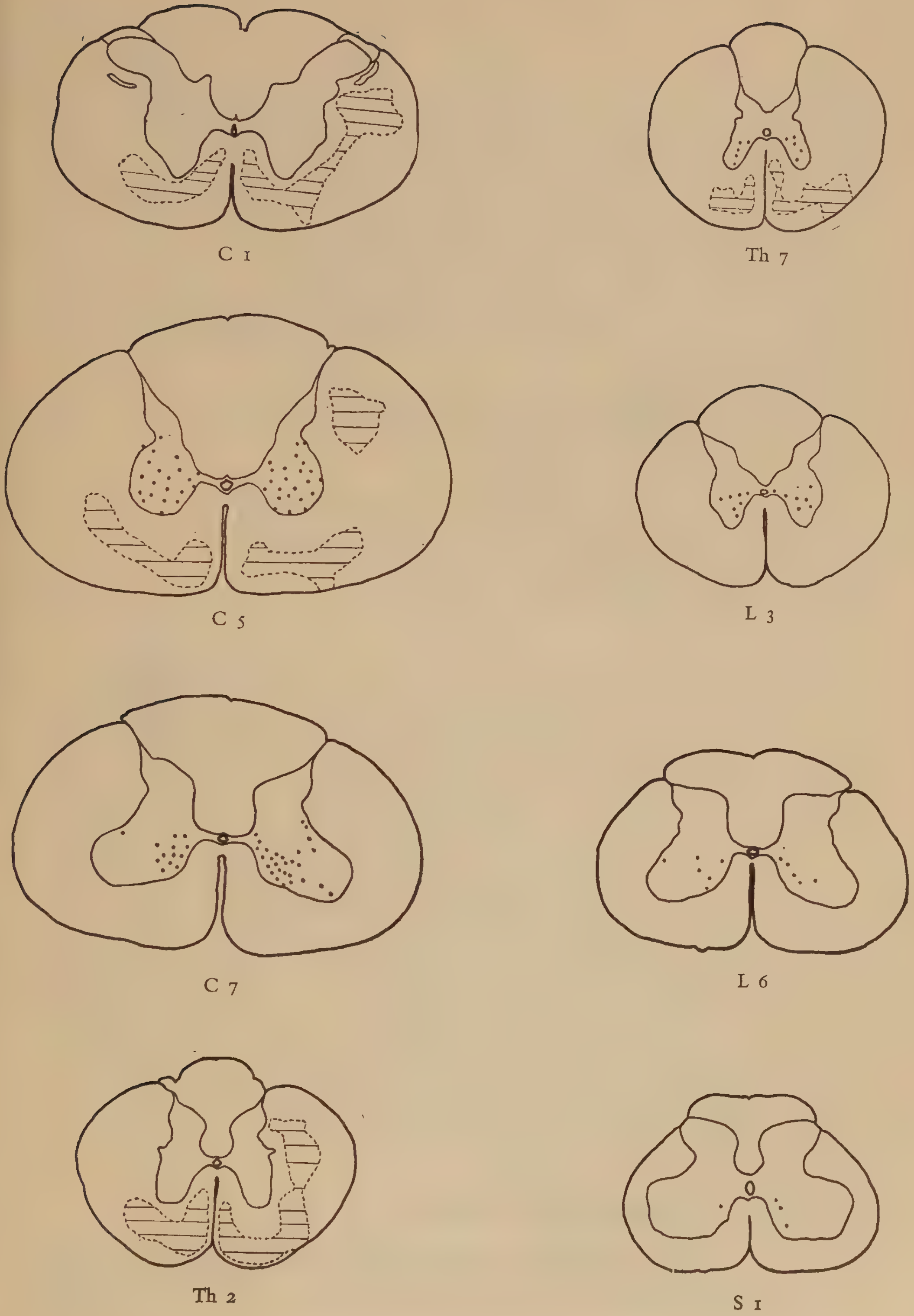

Degeneration in the cord of Cat H 3882.

SUMMARY

In this particular experiment the degeneration of the contralateral half of the cord was studied, because it could be attributed to crossed bulbar reticular fibres only. Degeneration was located in the anterolateral funiculus and could be traced into the lumbar intumescence. However, caudally, the fibres diminished markedly in numbers.

Within the grey matter an addition of small numbers of ipsilaterally descending reticulospinal fibres crossing at their level of termination had to be taken in account.

The localization in the contralateral grey matter was as follows:

in the C 5 segment within the laminae 6, 7, 8 and 9 (in lamina 7 a.o. in the nucleus cervicalis centralis);

in the C 7 and L 3 segments within the laminae 7 and 8;

in the low thoracic segments within the laminae 8 and 9;

in the L 6 segment within lamina 8.

Cat H 5028

The lesion lies between the planes P 10 and 13; it is largest in plane P 12. It extends from the floor of the ventricle into the dorsal part of the lateral reticular formation and over a very tiny area into the medial reticular formation. Thus the medial longitudinal fascicle is not damaged. The animal was killed 10 days after the operation.

Microscopical examination of the medulla showed that crossed bulbospinal and uncrossed lateral bulbospinal fibres (Thomas' fascicle) were severed in relatively large numbers. The fibres belonging to the crossed bulbospinal fibresystem were interrupted in their origin, before their crossing the midline. Besides these, possibly some medial vestibulospinal fibres were interrupted also (not depicted in the scheme). These last fibres excepted, the spinal cord degeneration may be attributed entirely to reticular fibres from the medulla. The degeneration of the white matter will be reported in the summary only.

Degeneration within the grey matter of the cord

In the C 1, 2 and 3 segments degeneration contralateral to the lesion is much more extensive than at the other side. It is moderate to strong

P 10

P 11

P 12

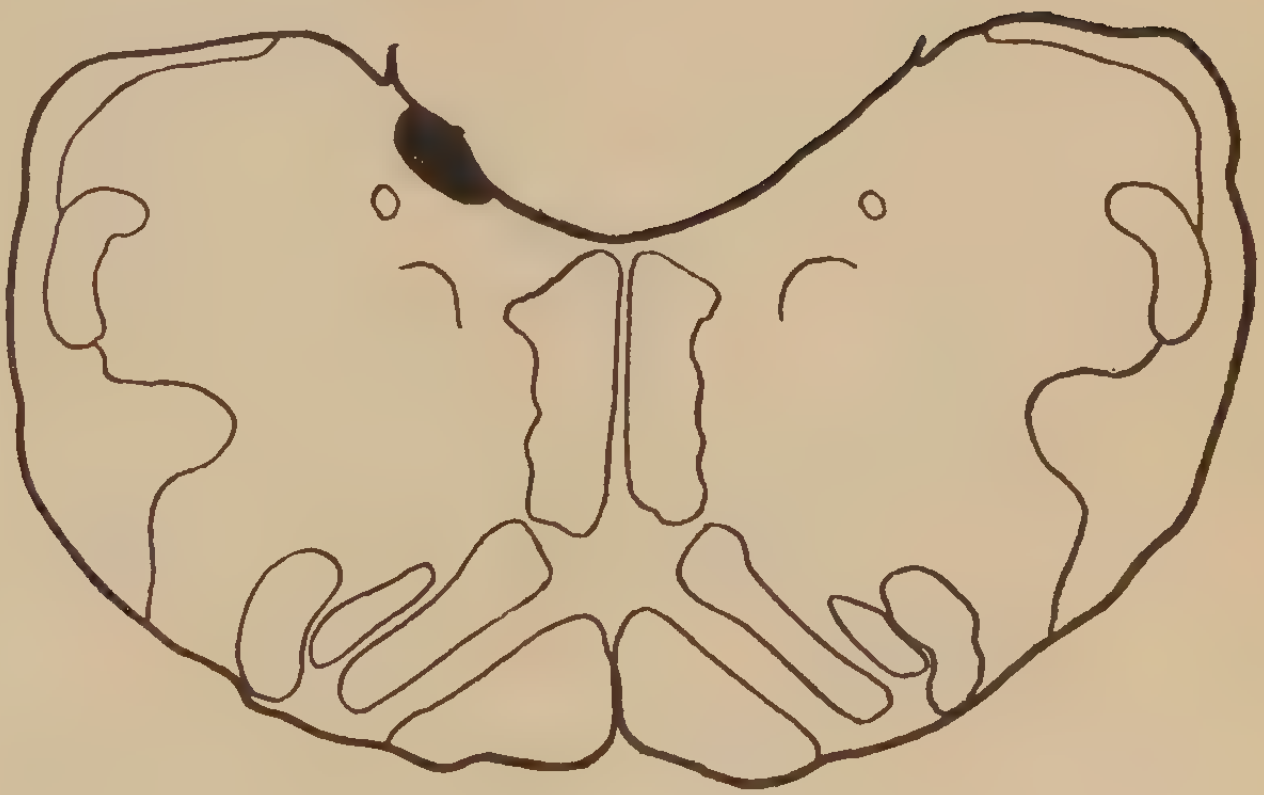

P 13

Lesion in Cat H 5028.

in intensity and occupies the whole anterior horn and the ventral part of the intermediate grey matter. Pericellular degeneration is very common in the anterior horn; degenerated fibres enter it along the medial and the lateral borders.

At the other side degeneration of slight to moderate intensity is chiefly found at the base and within the medial half of the anterior horn. In the C 2 segment it can be traced to the ventral part of the intermediate grey matter. In the C 3 segment differences between both sides are somewhat less marked than in the more rostral segments.

In the C 7 segment the contralateral degeneration is restricted to the dorsomedial part of the anterior horn; it is of moderate intensity. At the other side only some slight intensity degeneration is present in the medial part of the anterior horn. In the low thoracic segments some slight bilateral degeneration can be found in the medial and dorsal parts of the anterior horns, in the L 3 segment this degeneration has grown very scanty (not depicted in the scheme).

In the L 7 segment and the high sacral segments no degeneration can be found anymore.

SUMMARY

The white matter. In the segments C 1, 2 and 3 at both sides a poorly circumscribed area (especially at the ipsilateral side) of degenerated fibres could be found. Ipsilateral to the lesion it was a number of uncrossed lateral bulbospinal fibres (Fasciculus Thomasi), lying at the transition of the anterior and the anterolateral funiculi, lateral to the ventral anterior horn part. Contralateral to the lesion it contained the crossed bulbospinal fibres, situated in an area extending from the dorsal part of the sulcomarginal fascicle along the ventral and lateral margins of the anterior horn into the anterolateral funiculus. The areas which have been indicated in the scheme by a dotted line, were rather poorly circumscribed. At more caudal levels only a few scattered degenerated fibres were seen, without a certain area being attributable to them.

The grey matter: contralateral to the lesion moderate to strong intensity degeneration was exhibited down to the 7th cervical segment, whereas ipsilaterally it was of slight intensity only. In the low thoracic segments

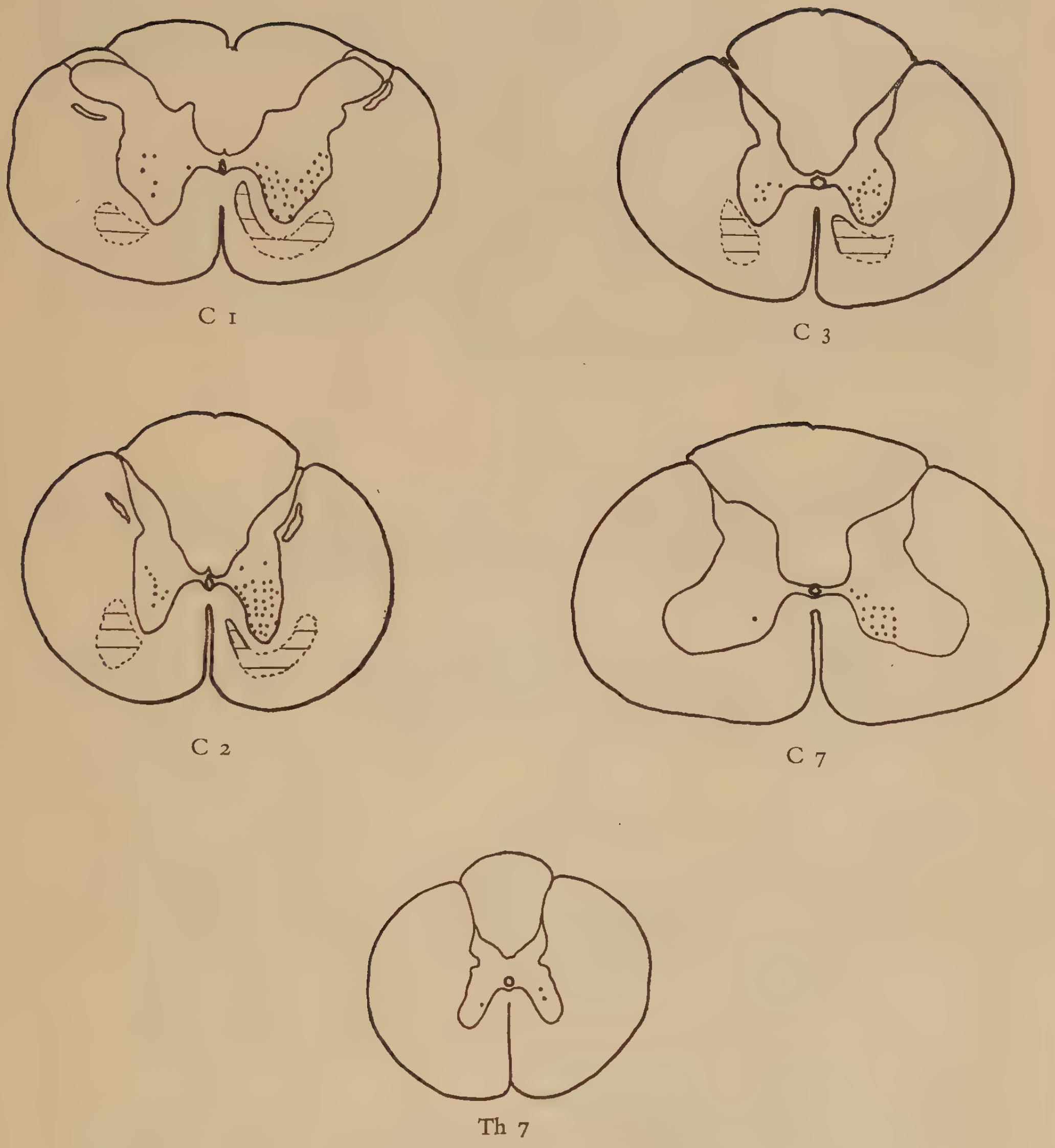

Degeneration in the cord of Cat H 5028.

and more caudally degeneration was only sporadic and of very slight intensity.
Contralateral to the lesion degeneration was localized as follows: in the C 1, 2 and 3 segments within laminae 8 and 7 and both parts of lamina 9; in the C 7 segment within lamina 8 and in the low thoracic cord at the transition of laminae 8 and 7.
Ipsilateral to the lesion its localization was as follows:
in the C 1, 3 and 7 and the caudal thoracic segments within lamina 8; the C 2 segment showed degeneration at the border of laminae 7 and 8. The very slight degeneration of the lumbosacral cord was restricted to lamina 8. Pericellular degeneration was common in the three upper cervical segments at both sides.

Cat H 5169

The lesion lies between the planes P 9 and 12, with its largest extent in P 10, where it encroaches from the ventricular floor upon the dorsal part of the lateral reticular formation. The animal was killed 12 days after the operation.
At microscopical study of the medulla the uncrossed lateral bulbospinal fibres of Thomas' fascicle proved to be partly severed together with some fibres from Deiters' nucleus.

Degeneration within the spinal cord

The degeneration of the white matter will be reported in the summary.
The grey matter. At the pyramidal decussation level ipsilateral to the lesion strong intensity degeneration enters the anterior horn by its medial and ventrolateral margins.
In the C 1 segment at the same side moderate intensity degeneration occupies the whole anterior horn.
In the C 5 segment slight intensity degeneration lies in the ventromedial part of the anterior horn, whereas in the C 7 segment it lies in the dorsomedial part of the anterior horn. In the thoracic cord degeneration cannot be distinguished and in the L 3 and 7 segments some slight intensity degeneration is located along the medial anterior horn margin.

P 9

P 10

P 11

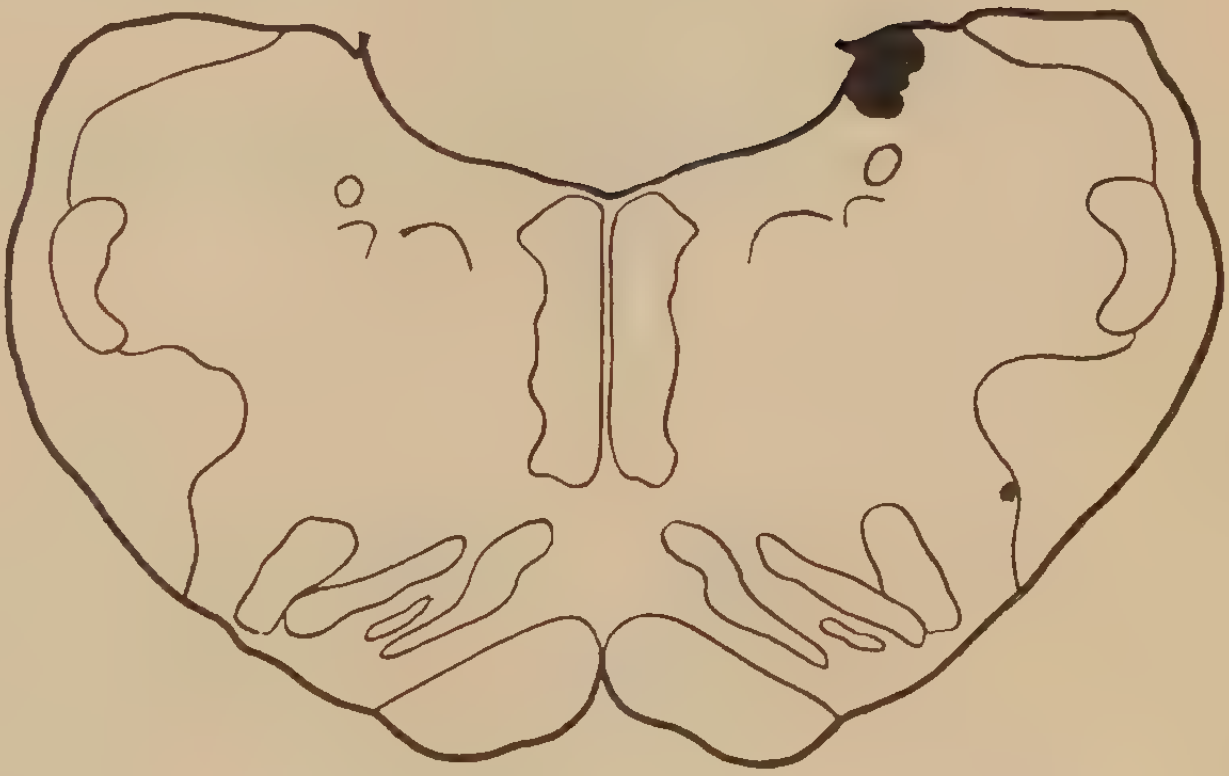

P 12

Lesion in Cat H 5169.

SUMMARY

At the transition of the anterior- and anterolateral fascicle a poorly circumscribed area with degenerated fibres could be found (represented by a dotted line in the scheme). The degeneration was located near the ventrolateral side of the ipsilateral anterior horn; degeneration in the white matter was restricted to the high and middle cervical segments. Grey matter degeneration consisted almost entirely of uncrossed lateral bulbospinal system fibres. The degeneration both in the white and the grey matter was restricted to the side of the lesion; throughout the length of the cord, it lay in lamina 8 and in the C 1 segment also in lamina 7. Only in the thoracic segments no degeneration could be demonstrated.

In the last descriptive part of this chapter a few experiments will be described in which total severance of the medial longitudinal fascicle in a low bulbar level and a hemichordotomy at the level of the pyramidal decussation were carried out. The purpose of these experiments was to study the degeneration in the grey matter of the cord following interruption of all the descending systems in the medial longitudinal fascicle in the former experiments, and the corticospinal fibres in addition in the latter.

In these experiments the degeneration in the white matter of the cord will not be considered.

Cat H 3869

The lesion lies in rostrocaudal direction between the planes P 12 and P 15. It comprises the whole medial longitudinal fascicle with the medial reticular formation of both sides as it is bordered by the hypoglossus nerve roots, at the level of the caudal third of the inferior olive. Besides this, bilaterally the medial part of the medial lemniscus and the pyramid are involved. The animal was killed twenty days after the operation. The degeneration in the grey matter of the cord was localized as follows: in the C 7 segment in the laminae 4, 5, 6, 7, 8, 9 and 10;

X-py

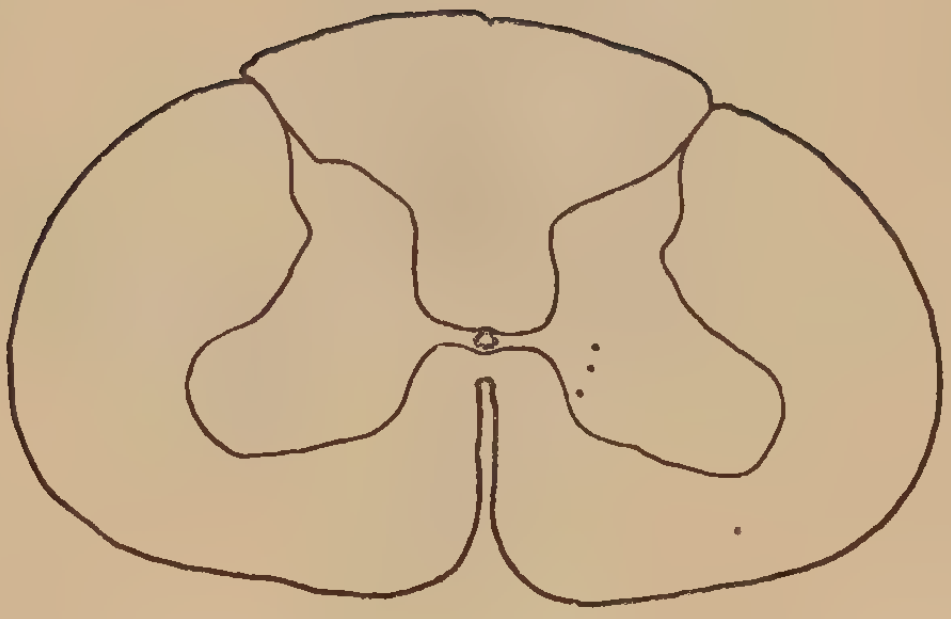

C 7

C 1

L 3

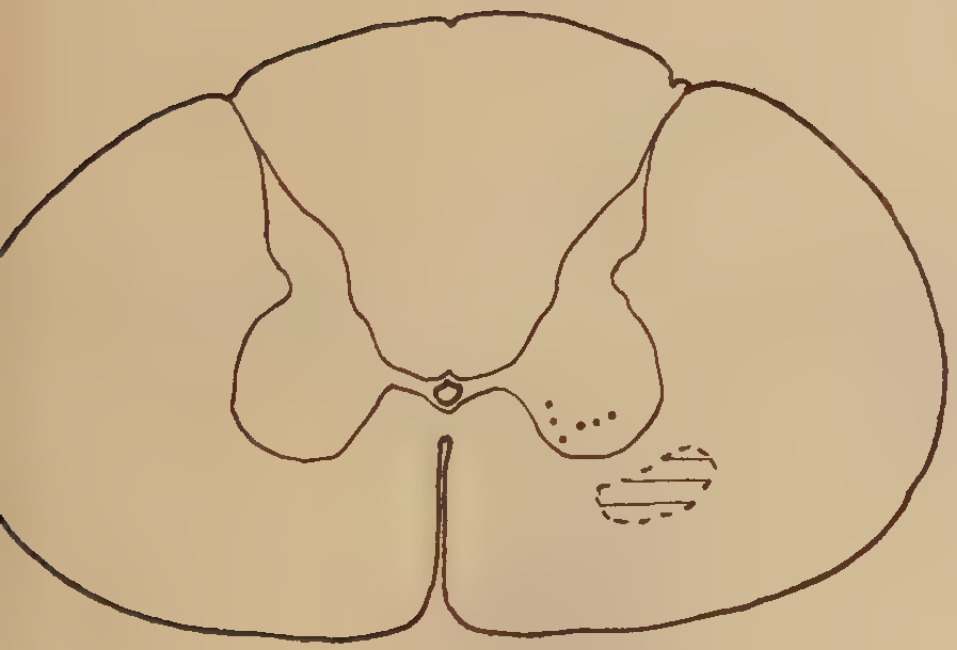

C 5

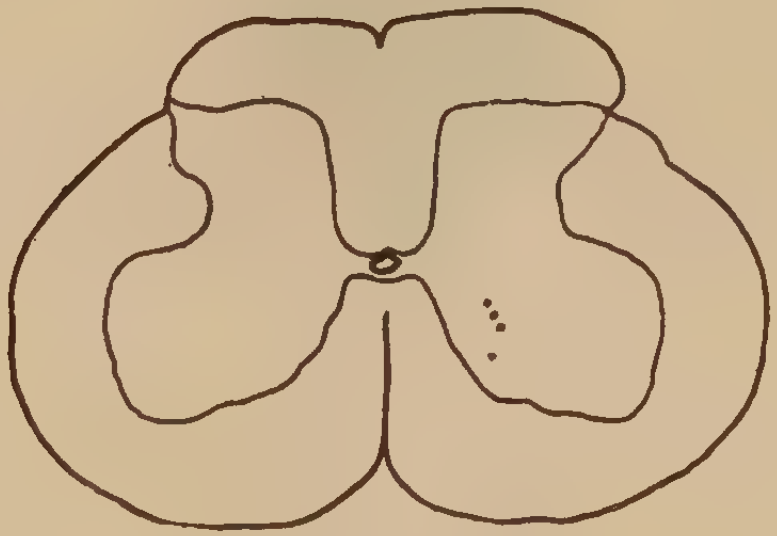

L 7

Degeneration in the cord of Cat H 5169.

P 12

P 13

P 14

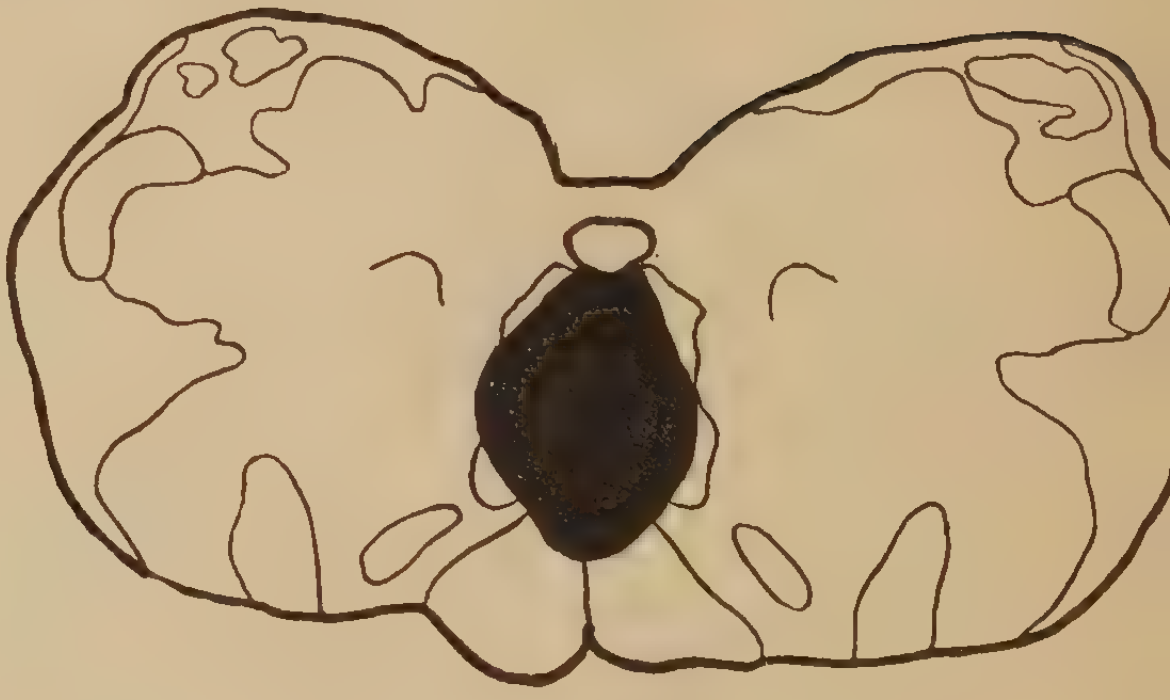

P 15

Lesion in Cat H 3869.

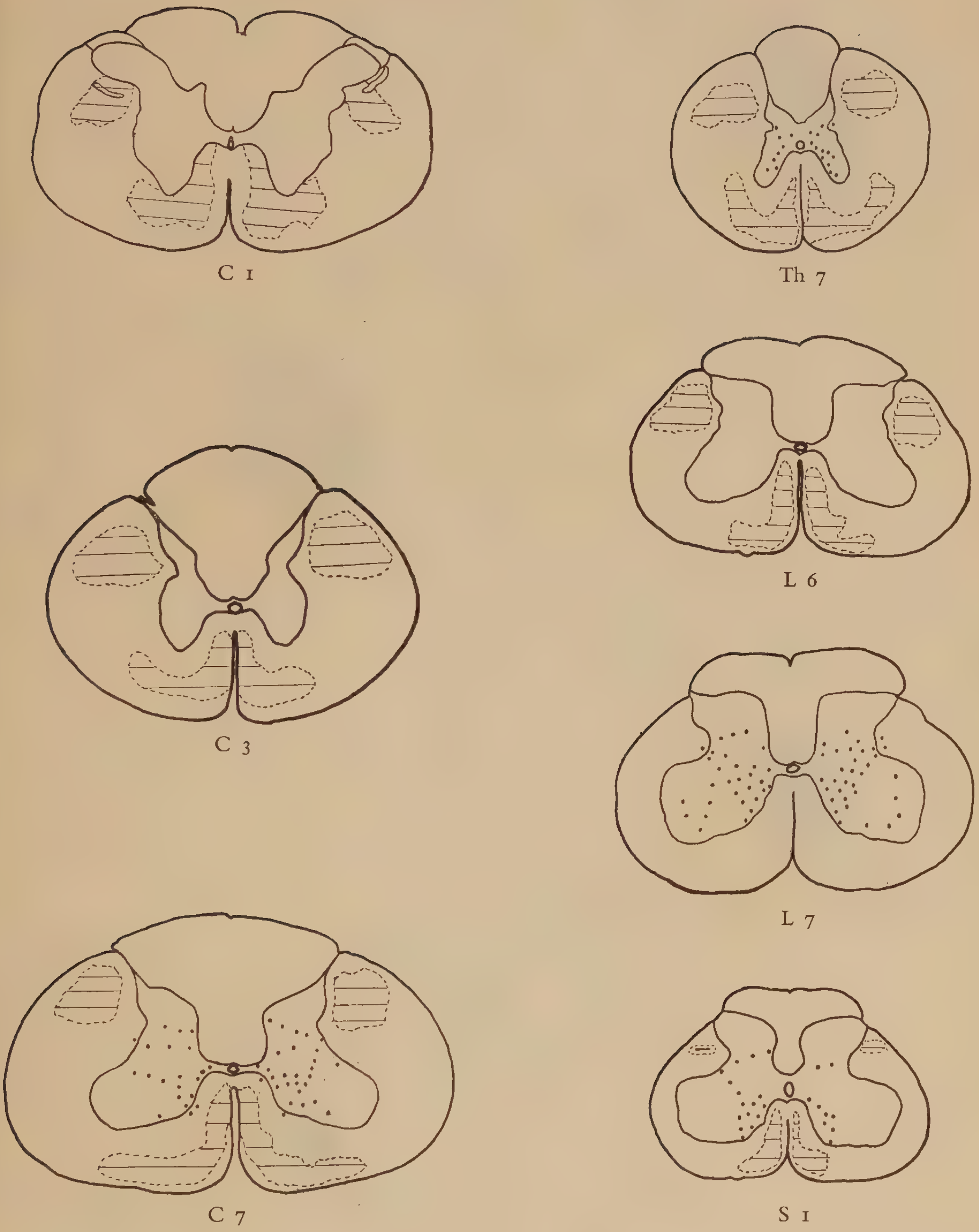

Degeneration in the cord of Cat H 3869.

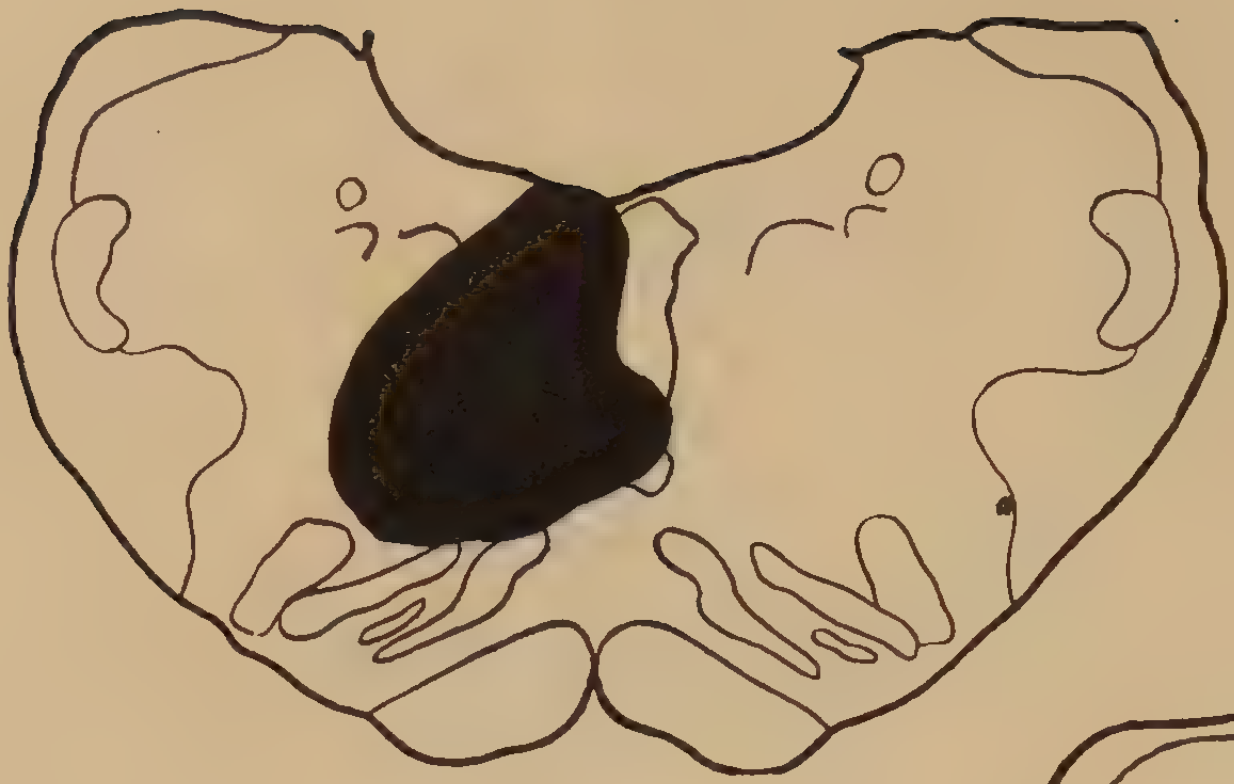

P 12

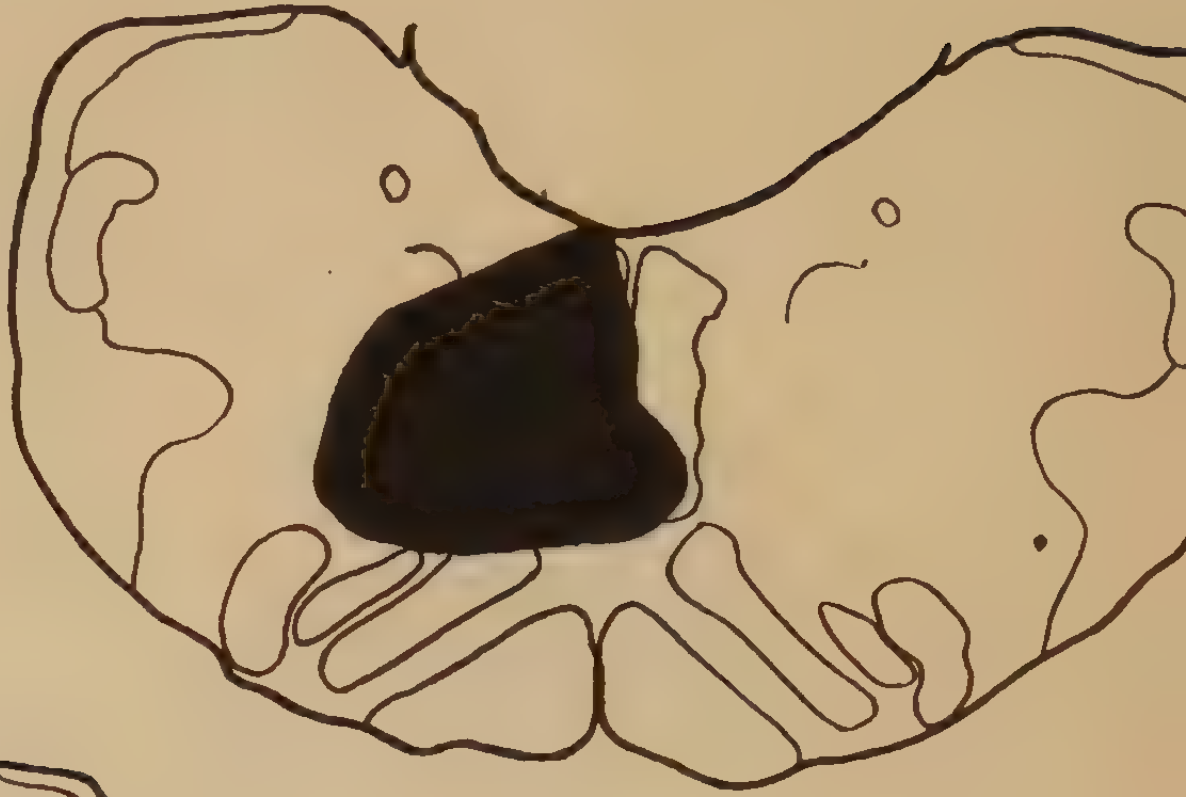

P 13

P 14

P 15

Lesion in Cat H 3625.

C 2

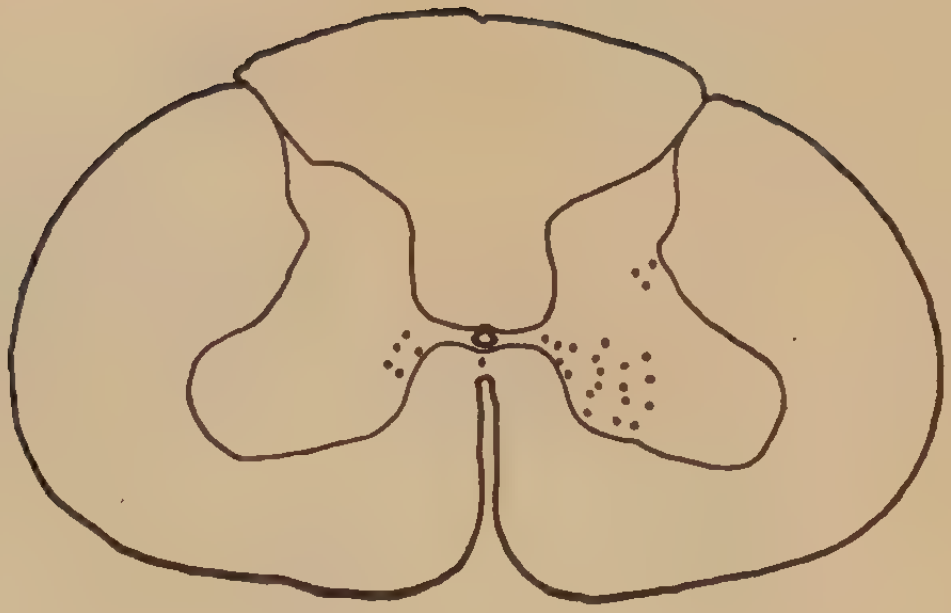

C 7

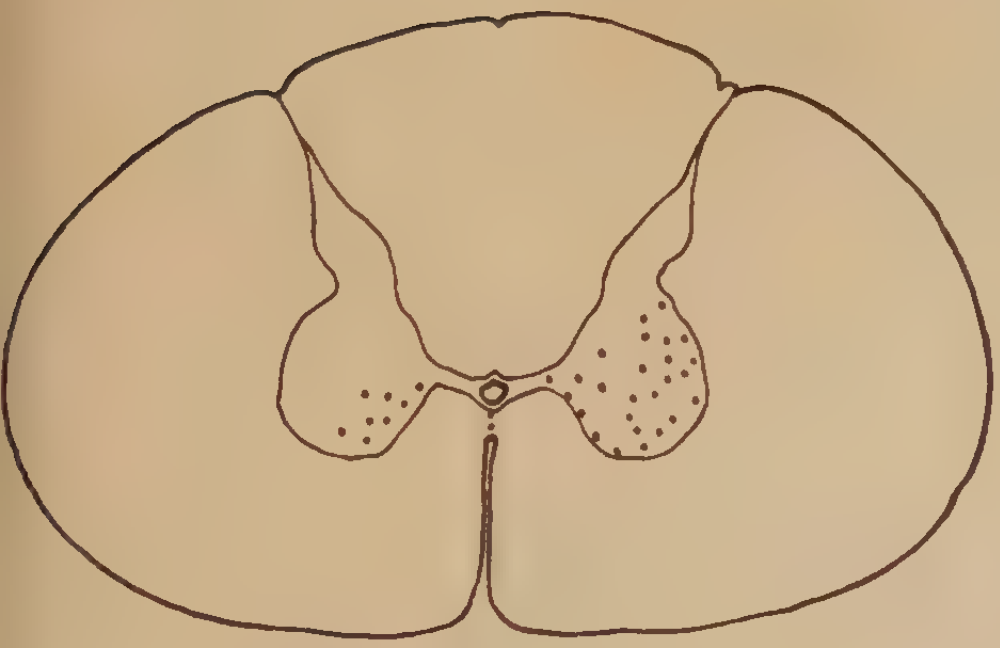

C 5

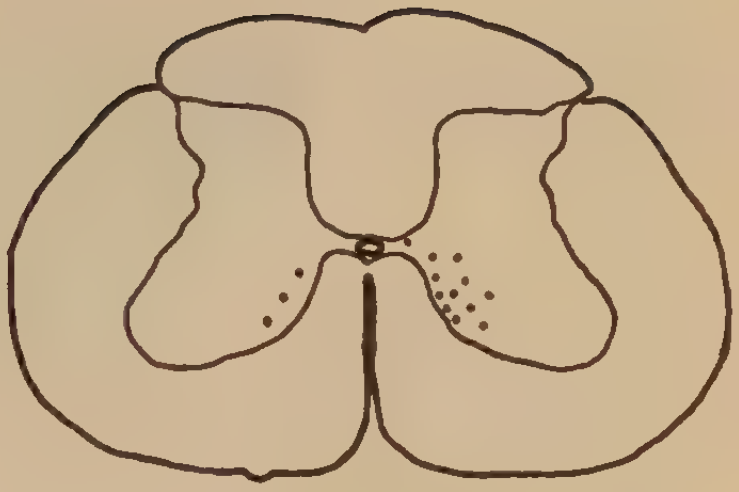

L 6

S 1

Degeneration in the cord of Cat H 3625.

in the low thoracic segments and in the L 7 segment in the laminae 5, 6, 7 and 8;
in the first sacral segment in the laminae 5, 7 and 8.

Cat H 3625

The lesion similarly lies between the planes P 12 and P 15. It comprises at one side the whole medial longitudinal fascicle with the whole medial, and the adjacent part of the lateral reticular formation. At the other side there exists a small infarction in the ventral part of the medial longitudinal fascicle. The animal was killed 19 days after the operation. Degeneration in the grey matter of the cord was localized as follows:
in the C 2 segment in the laminae 4, 5, 6, 7, 8, 9 and 10;
in the C 5 segment in the laminae 6, 7, 8, 9 and 10;
in the C 7 segment in the laminae 5, 7, 8 and 10;
in the L 6 segment in the laminae 8 and 10;
in the first sacral segment in lamina 8.

Cat H 3854

In this animal the lesion lies between the planes P 16 and P 18. It is a total hemichordotomy at mid-pyramidal decussationlevel in which a small part of the crossing pyramidal tract also is involved. The animal was killed 17 days after the operation.
Degeneration in the grey matter of the cord was localized as follows:
in the C 5 segment in the laminae 6, 7, 8, 9 and 10;
in the C 7 segment in the laminae 6, 7, 8 and 10;
in high thoracic levels and in the lumbar intumescence in the laminae 5, 6, 7, 8 and 10; in the first sacral segment in the laminae 6, 7 and 8.

As being irrelevant in this matter, the differences in the degeneration between the right and left halves of the cord, were not discussed in these last three experiments.

Most conspicuous in these animals was the absence of degenerating preterminals around the large ventrolaterally localized motor anterior horn neurones of both the cervical and the lumbar intumescences. This had already been observed in the previous chapters, but even in the present experiments with the massive descending tracts de-

P 16

P 17

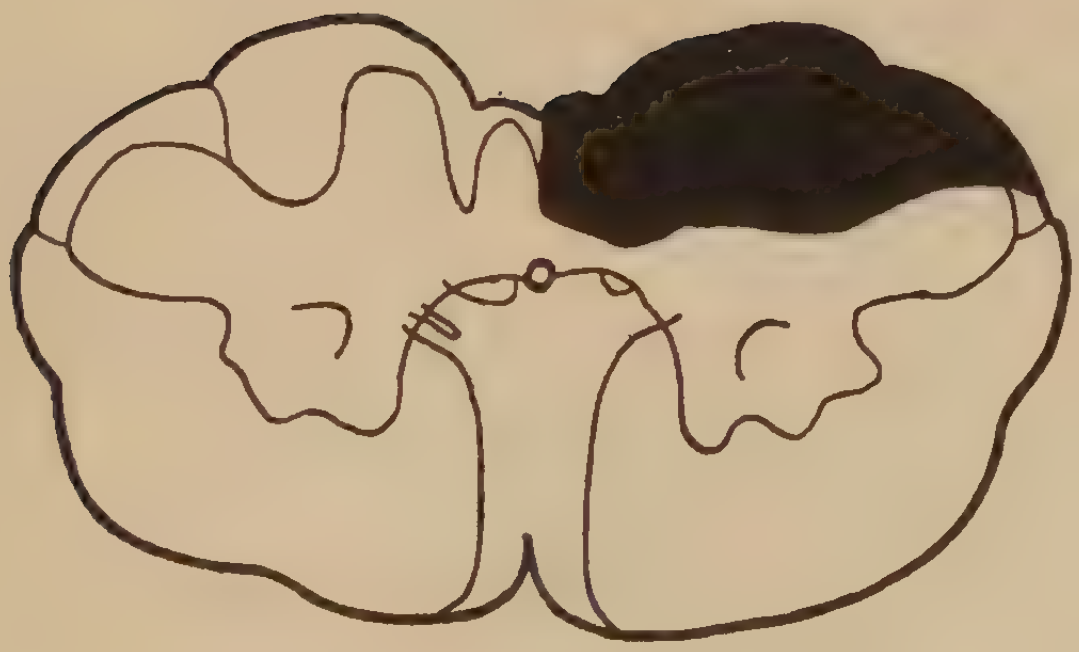

P 18

Lesion in Cat H 3854.

generation, degeneration around these cells proved to be lacking. Therefore it is justified to conclude that these ventrolaterally localized neurones are devoid of afferent connections from supraspinal centra, at least so far as can be demonstrated with the Nauta-Gygax technique.

DISCUSSION

In this chapter experiments were described in which selective lesions at the origin or in the course of reticulospinal fibresystems were more or less succesfully effectuated. The degeneration in the grey matter of the cord therefore could be attributed almost entirely to preterminal degeneration of reticulospinal fibres originating in the pons and the medulla oblongata. As announced previously, the classification of the reticulospinal fibresystems as initiated by Busch, was employed. The fibredegeneration visualized in the Häggqvist slides in the white matter of the cord, did not contradict the results of his study, also performed in the neuroanatomic laboratory at Leyden.

The systems studied were:

1. *the uncrossed medial reticulospinal tract*, originating in the medial reticular formation from the rostral pons to the caudal medulla;
2. *the uncrossed lateral bulbospinal tract*, also called fasciculus Thomasi, originating from the lateral bulbar reticular formation;
3. *the crossed pontospinal tract*, originating from the reticular formation at the level of the trigeminus motor nucleus;
4. *the crossed bulbospinal tract*, originating from the reticular formation at the level of the facial nerve genu and far more caudally.

The site of these systems in the white matter in the upper cervical segment has already been indicated by Busch, and in our study it appeared that they did not change their location very much at their descent in the cord. The crossed bulbospinal system lay most closely to the midline in the anterior fascicle: ventral to it lay the uncrossed medial reticulospinal system i.e. medioventral in the anterior funiculus. Whereas the uncrossed lateral bulbospinal system lay scattered in the anterolateral funiculus; the crossed pontospinal fibresystem could be

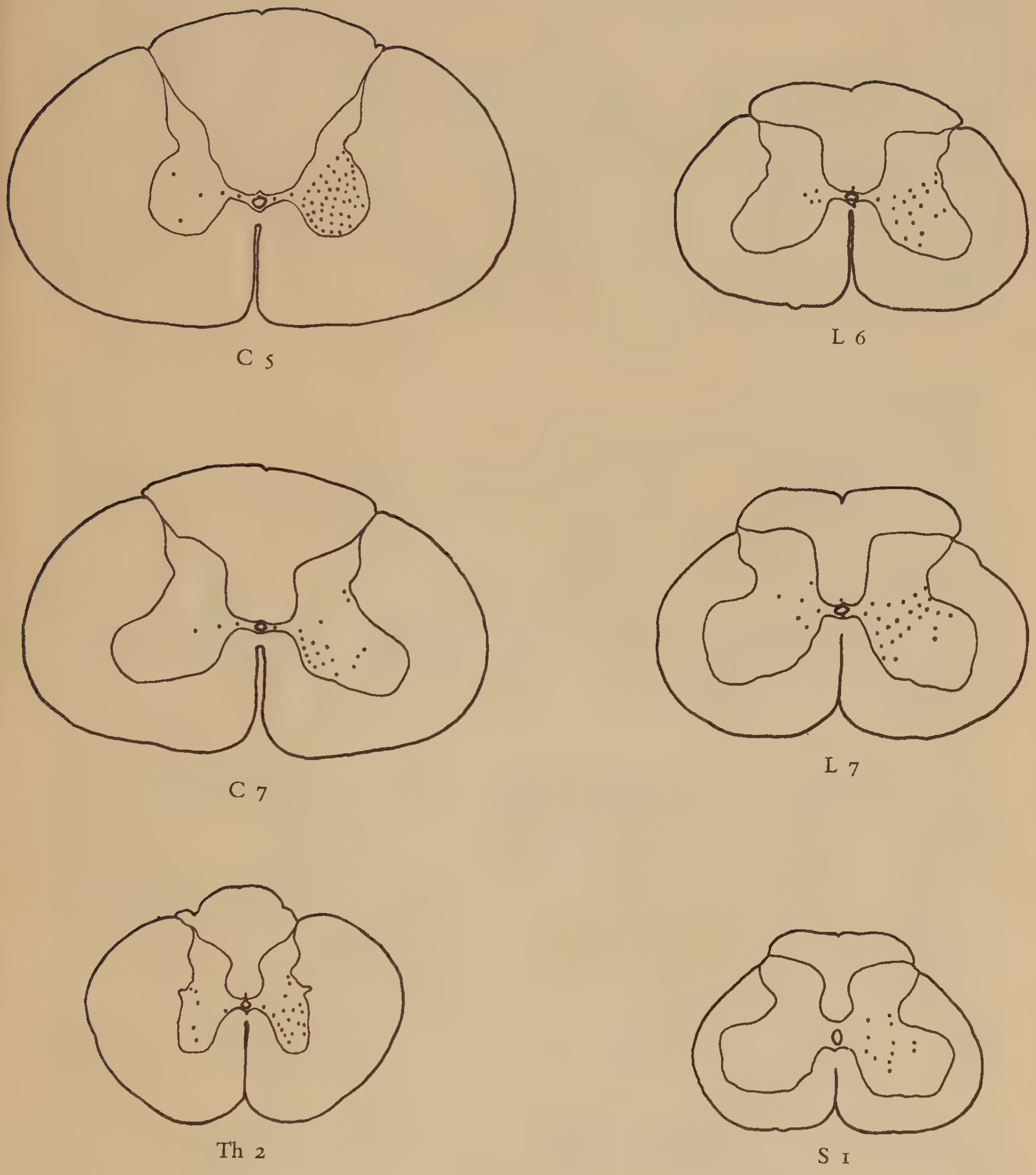

Degeneration in the cord of Cat H 3854.

found in the lateral funiculus, close to the medial tip of the rubrospinal tract.

Fibres belonging to the *medial reticulospinal tract* were severed in their course and origin between the planes P 2 and P 5 in cat H 4426 and between the planes P 3 and P 6 in cat H 5254. Concerning only the degeneration in the cord on the homolateral side of the lesion, also experiment H 4869 can be taken into account; although the lesion was much smaller and was located much more caudal in the medulla i.e. at the level of plane P 9.
At the side homolateral to the lesion the degenerated preterminals were located as follows:
at high cervical levels in the laminae 5, 6, 7, 8, 9 and 10;
at low cervical and thoracic segments and also in the lumbosacral intumescence in the laminae 7, 8 and 10; at high lumbar level (L 3) in the laminae 8, 9 and 10.
At the contralateral side the degeneration was found through the whole cord in the laminae 7, 8 and 10. Probably the degeneration was somewhat mixed with degenerated fibres of the crossed pontospinal tract (cat H 5254).

The degeneration in the grey matter of the cord after severance of fibres of the uncrossed *lateral bulbospinal tract* (Thomas' fascicle) was studied in the experiments H 5169, H 4871 and H 5028. The levels at which these fibres were damaged in their course or at their origin, were in cat H 5169 and H 4871 located between the planes P 9 and P 12, and in cat H 5028 between the planes P 10 and P 13.
In the proximal parts of the cervical cord the degenerated preterminals of this system were found in the laminae 7, 8 and 9. In the other parts of the cord the degeneration was restricted to lamina 8, it was found as far down as the lumbosacral intumescence. Only in the low cervical, thoracic- and high lumbar segments there was a small extension to be found into lamina 7.

Conclusions about the terminations of the *crossed bulbospinal fibresystem* were derived from the experiments H 4869, H 3882, H 4871 and H 5028.

In the first two experiments however, in the grey matter some overlapping of degenerated fibres of the medial reticulospinal tract, crossing the midline during their descent, might be present in the cord. Therefore the most selective results in this matter were to be got from the experiments H 4871 and H 5028. The degenerated preterminals of the crossed bulbospinal system in these cases throughout the spinal cord were located in laminae 7 and 8 and a few times in lamina 9; only in cat H 5028 they were no more found caudal to the Th 7 segment, presumably because the lesion in this animal was rather small. In the experiments mentioned the lesions lay between the planes P 7 and P 13.

We did not succeed in damaging the *crossed pontospinal fibresystem* without interrupting fibres of the other reticulospinal systems also. Thus we could not get a picture of the degeneration in the grey matter restricted to this fibresystem, and only the course of these fibres in the white matter of the cord could be studied (vide supra).

Interpretation of the results of the experiments is not easy, as the reticular fibres entering the cord are neither assembled in circumscribed tracts nor derived from circumscribed nuclei. However for the sake of brevity, we, in this study, usually speak of tracts.

As to the distance over which the reticulospinal fibres descended in the cord, it seemed certain that many fibres reached the low lumbar segments and even in experiments H 4426 and H 5254 where the lesion did not pass beyond the plane P 5 and P 6 respectively, degeneration in the grey matter of the sacral segments was still present, slight to moderate in intensity. Thus, in these experiments the fibres were chiefly derived from the lower parts of the pons and the adjacent part of the medulla, rostral to the trapezoid body, the bulbospinal fibres not being severed at all.

Whether these long fibres can be attributed to one of the systems involved, in the light of the above mentioned restrictions evidently is hard to extablish.

The morphologically less conspicuous systems are the uncrossed lateral bulbospinal tract of André Thomas and the crossed pontospinal tract. The former, consisting of relatively fine fibres, spreads in the antero-

lateral funiculus, the latter, consisting of small numbers of coarse fibres, travels in and around the medial tip of the rubrospinal tract. In experiment H 5169 in which Thomas' fascicle was involved almost exclusively, degeneration could be followed to the L 7 segment. Therefore we are justified in assuming that in all probability at least two of the four reticulospinal systems contain a contingent of fibres of that length. This should not make us forget the fact that they almost certainly consist chiefly of much shorter fibres, not surpassing the cervical cord. This is obvious from experiments H 4426, H 5254 and H 5169, where the number of degenerated fibres in the white matter decrease considerably before the C 7 segment is reached.

In cat H 5028, the lesion was relatively small and lay very dorsally; the white matter degeneration stopped at a relatively high level. It comprised only a small number of fibres of Thomas' fascicle and contralaterally the crossed bulbospinal tract. This may be due to the small number of fibres severed, rather than the systems involved.

The terminations of the four tracts do not offer much information about their specificity. They were most common in laminae 7 and 8, in the latter somewhat more than in the first. In laminae 6, 9 and 10 they were also frequent, but much less than in the first mentioned laminae. In lamina 5 terminations were very rare. Differences between the four tracts to be found are: Tract 1 (medial reticulospinal) ends principally in laminae 7, 8 and 10; but has also some terminations in laminae 6 and 9 and an occasional one in lamina 5. The many terminations of this tract are not surprising, because it is the largest, with the greatest number of fibres presumably and the largest area of origin.

Tract 2 (Thomas' fascicle) is tiny and travels widespread in the anterolateral funiculus, ending chiefly in laminae 7 and 8. Concerning its location in the white matter it should be kept in mind that fine isolated degenerated fibres may easily escape detection in the Häggqvist preparations.

Tract 3 (crossed pontospinal) seems to be orientated upon the intermediate grey matter and the posterior horn, rather than on the anterior horn. As stated already, selectivity of terminations reached in this tract, was far from satisfying.

Tract 4 (crossed bulbospinal) is the most selective, as it very predo-

minantly terminates in lamina 8, however in C 1 and C 2 segments in lamina 9 too, and besides this only in lamina 7.
With the inevitable overlapping of areas of origin and the lesions kept in mind, it seems justified to acknowledge some degree of specifity to at least three of the four tracts with regard to their site of termination in the cord. Their site in the white matter of the cord can be considered as more elective, and it proved to be related to the side on which the fibres enter the grey matter.

In this chapter experiments were recorded in which the four reticulospinal systems were interrupted at various levels of the pons and the medulla. Although the selective severance of a certain reticulospinal system, either in its origin or its course, proved to be unfeasible, with the help of the stereotactical instrument we succeeded in reaching a reasonable degree of selectivity.
Until now, as may appear from the survey of the literature, the terminations of the reticulospinal systems (and their course below the C 1 segment), has not yet been differentiated in a way comparable to that in the present chapter. Tschermak and Redlich in their study of Marchi slides, reported that "reticulo"-spinal fibres terminate in the anterior horn of the cord of the cat. In a not yet mentioned paper of Kuru, Kurati and Koyama (1959) based on Marchi-slides, terminations of the "lateral reticular spinal tract" were described in "the intermediolateral column of the grey matter; partial decussation in lumbar segments", as the authors stated it, also has been noticed. Presumably in this publication Busch' crossed pontospinal tract was lesioned.
A study with the more appropriate silver impregnation methods has not yet been done, and the findings reported in this chapter consequently should be considered as new.

CHAPTER VIII

GENERAL DISCUSSION AND CONCLUSIONS

When the results of this study are considered, the following salient features may be stressed.

Except the rubrospinal- and some of the reticulospinal fibresystems, all the systems studied (interstitio-, tecto-, reticulo- and vestibulospinal) proved to terminate, in the cervical intumescence and in the more caudal levels of the cord, along the medial border of the anterior horn. Thus, the terminations of these systems at the afore mentioned levels proved to be partly identical. With regard to the numerous afferents of the anterior horn cells, it must be stressed that the medial portion of these cells received, among others, fibres from various subcortical centres.

Terminations of the systems descending in the anterior funiculus of the spinal cord were almost wholly confined to the anterior horn; only the tecto- and medial reticulospinal fibres also terminated in the intermediate grey matter of the upper cervical segments (lamina 6 and the ventral part of lamina 5). However, even of these two systems the great majority of the fibres ended in the anterior horn (laminae 7, 8 and 9). Terminations in the intermediate grey matter and the base of the posterior horn was the rule in the rubrospinal system, of which only few fibres ended in the anterior horn. Although the crossed pontospinal system could not be severed electively enough, the impression was gained that its fibres also ended chiefly in the intermediate grey matter. Similar to the rubrospinal system it descended in the posterior part of the lateral funiculus.

With regard to these facts the termination of the corticospinal fibres in the cat as revealed by Szentágothai-Schimert, Chambers and Liu, and Kuypers ought to be considered. As previously reported, these authors found the corticospinal fibres to end in the intermediate grey matter and especially at the base of the posterior horn, whereas it is generally known that the pyramidal tract in the cat descends in the lateral funiculus in close topografical relation with the rubrospinal tract. Therefore it may be concluded that the fibresystems descending

in the anterior funiculus of the cord end predominantly in the anterior horn (laminae 7, 8 and 9), whereas the systems descending in the posterior part of the lateral funiculus end in the base of the posterior horn and in the intermediate grey matter (laminae 5 and 6).

The fibresystems descending in the anterior funiculus (and in the ventral part of the lateral funiculus), having their terminations in the anterior horn, are the interstitiospinal, the tectospinal and the vestibulospinal systems and three of the four reticulospinal systems.

The fibresystems descending in the posterolateral funiculus and having their terminations in the intermediate grey matter and in the base of the posterior horn are the corticospinal-, the rubrospinal- and the crossed pontospinal systems. It should be emphasized that the corticospinal fibres end predominantly in the base of the posterior horn.

Thus, it is clear that in the cat the localization of the long descending tracts within the white matter of the cord is related to the localization of their terminals in the grey matter. *

The terminations of the descending systems of the anterior funiculus did not show typical differences, and their areas of termination exhibited a great deal of overlapping. A similar analogy has been proved to exist between the systems descending in the posterior part of the lateral funiculus.

The crossing of fibres from both the tectospinal and the medial reticulospinal systems during their descent through the cord was a remarkable feature of these descending tracts. Consequently, a number of tectospinal fibres before terminating in the cord, crosses twice: once in toto in the mesencephalon shortly after originating from superior colliculus neurones, and once partially in the cord.

Notwithstanding the great length of a number of brainstem fibres entering the cord, the majority of these fibres, the rubrospinal ones excluded, end already in the upper cervical segments. The systems containing the very long fibres still prove to exist for a considerate part of

---

* Of comparative-anatomical interest seems the fact that in macaca, papio, the chimpanzee and in man an increasingly larger contingent of corticospinal fibres terminate in the anterior horn (Hoff and Hoff, and Kuypers). However, in these animals a progressively more important contingent of uncrossed corticospinal fibres, descending in the anterior funiculus, occurs.

short fibres. Most fibres of greatest length are found in the medial reticulospinal system and the lateral bulbospinal system; both systems entering the cord without crossing.

Efferents from the brainstem to the spinal cord proved to be especially numerous to the upper cervical segments, surpassing considerably in number those to the more caudal parts of the cord. Therefore it seems probable that the latter parts in these respects depend chiefly on propriospinal fibres from more rostral segments.

Another special feature is the lack of efferents from the brainstem and the cortex to the ventrolateral group of anterior horn cells in the cervical and lumbar intumescences. This was strikingly demonstrated in the animals with a low medullary medial longitudinal fascicle section and in the one with a hemichordotomy at a low pyramidal decussation level, in which all possible descending fibres were interrupted. Therefore it is justified to assume that these anterior horn neurones lack afferents from supraspinal centra, and possibly are subserved by centra from the lower part of the cord and/or by the posterior roots or by rostral centra through propriospinal fibres. These ways of transmission have not been taken into account in this study. Thus, it can only be supposed that the aforementioned ventrolateral anterior horn cells will react differently on impulsions from the encephalon. The physiological implications of their special lack of supraspinal afferents are entirely beyond the scope of this study.

Already in chapter II it was concluded from references of the literature that the neurones of the cord could not be classified on account of their connections. This conclusion cannot be refuted after the discussion of the present experiments. However, the hodology will off course remain of great importance for the neuro-physiologist, and perhaps this study may be of some use to future neuro-physiological experimentation.

SUMMARY

After stereotactical electrocoagulations in various subcortical centres in the cat had been made, the secondary fibredegeneration in the grey and white matter of the spinal cord was studied with the help of the Nauta-Gygax and the Häggqvist techniques. The choice of these methods was discussed. The animals were killed 10 to 21 days after the operation, and the lesions were diagrammatically represented and described.

The fibresystems studied were the interstitio-, tecto-, rubro- and vestibulospinal systems and the reticulospinal fibres originating in the pons Varoli and the medulla oblongata. Each fibresystem was studied in several animals.

In order to describe the terminations of the afore mentioned systems in the grey matter of the cord, the various opinions about the classification of the grey matter were discussed. The degeneration in our experiments was described using Rexed's cytoarchitectonical conception of the cord of the cat (1952, 1954).

For every studied segment of the cord a description and a diagram of the degeneration in the white and grey matter was given.

As was expected, the degeneration in the Nauta-Gygax slides could be traced more caudally than in the Häggqvist slides.

The *interstitiospinal fibres* were found in the white matter of the cord as caudal as high thoracic levels; they were situated dorsally in the ipsilateral sulcomarginal fascicle. The degenerated preterminals of this system could be found down to the lumbosacral segments in the laminae 7 and 8 of the ipsilateral grey matter.

The *tectospinal fibres* were found ventromedial in the contralateral sulcomarginal fascicle. Degenerated fibres in the white matter were found down to low cervical or high thoracic segments. These fibres proved to have their preterminals at high cervical levels in the laminae 8, 9a (spinal accessorius nucleus), 7, 6 and in the ventral half of lamina 5. In the lumbar segments the degenerated preterminals of this system were found in the laminae 7 and 8.

A remarkable feature was that part of the tectospinal fibres, or their collaterals, crossed the midline again during their descent through the

cord, as degenerated preterminals were also found in the homolateral grey matter, i.e. in the laminae 7, 8 and 10.
The *rubrospinal fibres* were located dorsally in the lateral funiculus; in the white matter they could be followed as far down as the sacral segments. In the grey matter degenerated preterminals were found down to coccygeal levels in the laminae 5, 6, 7 and some in lamina 8. The degeneration in the cord remained restricted to the contralateral side.
In accordance with Busch (1961) the *vestibulospinal fibres* could be distinguished in crossed- and uncrossed fibres descending in the sulcomarginal fascicle, and in direct lateral vestibulospinal fibres (from Deiters' nucleus), descending on the border of the anterior- and lateral funiculus, near the periphery of the cord. The crossed- and uncrossed vestibulospinal fibres descending in the sulcomarginal fascicle were located respectively along the anterior fissure and near the medial border of the anterior horn. The number of fibres of the latter system appeared to be considerably smaller than that of the crossed system.
These fibres from the sulcomarginal fascicle proved to end in the grey matter in lamina 8. In the experiments in which these systems were most completely interrupted, the degenerated preterminals were found down to the grey matter of the sacral parts of the cord.
The direct lateral vestibulospinal fibres, originating in Deiters' nucleus proved to end in the laminae 8 and 9 of the homolateral grey matter at high cervical segments. In the lower segments as far down as the lumbar cord, they were found in lamina 8 only.
Finally the *reticulospinal fibres*, originating in the pons Varoli and the medulla oblongata were investigated. In accordance with the experimental studies performed by Busch, these fibres could be classified in four systems, allthough the localizations we found were not exactly the same. These four systems were: the uncrossed medial reticulospinal fibres, the uncrossed lateral bulbospinal fibres (Thomas' fascicle), the crossed pontospinal fibres and the crossed bulbospinal fibres.
1. Uncrossed medial reticulospinal fibres, originating in the caudal pons and the rostral medulla, descended chiefly ventrally in the anterior funiculus of the cord. The degenerated preterminals of this fibresystem were found in the homolateral grey matter in high cervical levels in the laminae 5, 6, 7, 8, 9 and 10; in low cervical- and thoracic

levels and also in the lumbosacral intumescence in the laminae 7, 8 and 10; in high lumbar segments degeneration was seen in the laminae 8, 9 and 10. Fibres of this system, or their collaterals partly decussated during their descent through the cord, as degeneration was also found in the contralateral grey matter, i.e. in the laminae 7, 8 and 10.

2. The uncrossed lateral bulbospinal fibres (Thomas' fascicle) were found scattered in the anterior funiculus, for the greater part outside the sulcomarginal area. Degenerated preterminals of these fibres were seen exclusively in the homolateral grey matter; in the high cervical parts of the cord in the laminae 7, 8 and 9. In the lower part of the cord degeneration was found as far down as the lumbosacral intumescence in lamina 8. This fibresystem consisted chiefly of thin fibres.

3. The crossed pontospinal fibres lay in the cord dorsally in the lateral funiculus, in close topografical relationship with the medial part of the rubrospinal tract. This system proved to consist chiefly of a small number of thick fibres. Unfortunately, severance of the fibres of this system was not sufficiently selective to get a clear result about their terminations.

4. The crossed bulbospinal fibres covered a rather circumscribed area in the anterior fascicle of the contralateral side, contrarely to the other reticulospinal fibresystems. The terminations of these crossed bulbospinal fibres were found, contralateral to their origin, throughout the cord in the laminae 7 and 8, and in high cervical levels in lamina 9 too.

Although the medial reticulospinal system and Thomas' fascicle contained very long fibres, extending as far as the low lumbar segments, it appeared that a very important part of the reticulospinal fibres ended in the cervical cord. Concerning the localization of the terminalia in the several laminae of the grey matter of three of the four reticulospinal fibresystems, some degree of specificity seemed to exist.

This paper was concluded with a discussion of the results, the most important points of which will be discussed below.

1. It should be emphasized that the preterminals of most of the fibresystems studied have only rarely been investigated with an appropriate silver technique.

Besides, in earlier investigations a satisfactory selectivity of the lesions was practically never obtained, because most workers did not use a stereotactic method.

The Nauta-Gygax technique (axon staining) gives a much more accurate and detailed picture than the untill now mostly used Marchi technique (degenerated myelin staining), since with the former method unmyelinated parts of axons in the grey matter are also visualized. The drawbacks of the Glees method were mentioned.

2. It was noticed that degenerated preterminals around the ventrolateral anterior motor horn cells in the cervical- and lumbar intumescences were hardly ever seen. Even after total sections of the medullary medial longitudinal fascicle and after a hemichordotomy at a low pyramidal decussation level they appeared to be lacking. So it proved impossible to demonstrate connections from supraspinal centres to these anterior motor horn cells.

3. It was established that the number of direct descending connections from the mesencephalon, pons and medulla to the high cervical parts of the cord was much greater than those to the more caudal parts of the cord.

4. The opinion was given that it is unfeasible to give a classification of the grey matter of the cord, which is both clear and in accordance with reality, based on the connections of the ganglioncells. The same conclusion could also be drawn from the literature.

5. In the cord of the cat there seemed to exist a certain relationship between the localization of the long descending tracts in the white matter and the localization of their (pre)-terminals in the grey matter. Thus the corticospinal, rubrospinal and crossed pontospinal fibres, descending in the dorsal part of the lateral funiculus, proved to end chiefly in the intermediate grey matter and in the base of the posterior horn, whereas the interstitiospinal, the tectospinal and the vestibulospinal fibresystems, and three of the four reticulospinal fibresystems, all descending in the anterior funiculus, proved to end chiefly in the anterior horn.

6. It was pointed out that part of the tectospinal and the medial reticulospinal fibres, or their collaterals, crossed the raphe during their descent through the cord.

7. The importance of the propriospinal fibres was stressed in connection with the fact that the investigated fibresystems, the rubrospinal one excluded, proved to consist for an important part of short fibres. The

uncrossed medial reticulospinal- and the uncrossed lateral bulbospinal system contained the largest contingent of long fibres. Both these systems reached the cord without crossing the midline.

8. It could be said that the areas of termination of the fibresystems studied showed overlapping at their margins.

SAMENVATTING

Na stereotactisch aangebrachte electrocoagulaties in een aantal subcorticale centra bij de kat werd de secundaire vezeldegeneratie in de witte en de grijze stof van het ruggemerg bestudeerd, na een overlevingstijd variërend van 10 tot 21 dagen. Dit werd gedaan met behulp van de Häggqvist- en de Nauta-Gygax methode. De motivering van de keuze dezer kleurmethoden werd uitvoerig besproken. De aangebrachte laesies in de hersenstam werden in schema gebracht en beschreven.

De onderzochte vezelsystemen waren de interstitiospinale, de tectospinale, de rubrospinale en de vestibulospinale systemen, en de reticulospinale vezels ontspringend in de pons Varoli en de medulla oblongata. Ieder vezelsysteem werd bij verschillende proefdieren onderzocht en de literatuur betreffende de diverse systemen werd besproken.

In verband met de beschrijving van de eindigingen der genoemde vezelsystemen werden de verschillende meningen over de indeling van de grijze stof in het ruggemerg in het kort besproken. Aan de hand van de cytoarchitectonische indeling van het ruggemerg van de kat volgens Rexed (1952, 1954), werd de waargenomen degeneratie in de grijze stof van het ruggemerg beschreven. Tevens werd de degeneratie in de witte en de grijze stof van het ruggemerg in alle experimenten — voor ieder onderzocht ruggemergssegment apart — in schema gebracht. Het was te verwachten dat in de coupes gekleurd volgens Nauta-Gygax, tot op een aanzienlijk lager niveau in het ruggemerg degeneratie zou worden gevonden dan in de coupes gekleurd volgens Häggquist.

De *interstitiospinale vezels* werden in de witte stof van het ruggemerg tot op hoog thoracaal niveau steeds dorsaal in de homolaterale sulcomarginale fasciculus gevonden, terwijl de praeterminalia van dit systeem in de homolaterale grijze stof, tot in de lumbosacrale segmenten, in laminae 7 en 8 te vinden waren.

De *tectospinale vezels* konden, ventromediaal in de heterolaterale sulcomarginale fasciculus, tot op laag cervicaal of hoog thoracaal niveau worden aangetoond. De eindigingen van de vezels bleken in onze experimenten in de grijze stof te liggen op hoog cervicaal niveau in

laminae 8, 9a (spinale accessorius kern), 7, 6 en in het ventrale deel van lamina 5. In de lumbale delen van het ruggemerg bevond de degeneratie zich in laminae 7 en 8. Tevens bleek, dat een deel der tectospinale vezels (of hun collateralen) opnieuw de raphe passeerden, want ook in de homolaterale grijze stof werden degenererende praeterminalia gevonden en wel in laminae 7, 8 en 10.

De *rubrospinale vezels* bleken dorsaal in de heterolaterale zijstreng te zijn gelocaliseerd; zij werden in de witte stof tot in het sacrale merg aangetroffen. In de grijze stof werden de degenererende praeterminalia tot op coccygeaal niveau in laminae 5, 6 en 7 en enigermate in lamina 8 waargenomen, echter uitsluitend in de heterolaterale grijze stof.

In navolging van Busch (1961) konden de *vestibulospinale vezels* worden onderscheiden in vezels die descenderen in de sulcomarginale fasciculus, gekruist en ongekruist, en ongekruist descenderende, laterale vestibulospinale vezels afkomstig uit de kern van Deiters. De laatsten bleken in de dwarscoupe van het ruggemerg gelegen te zijn op de grens van voor- en zijstreng, dicht bij de peripherie. De gekruist- en ongekruist afdalende vestibulospinale vezels in de sulcomarginale fasciculus waren respectievelijk gelocaliseerd langs de fissura mediana en langs de mediale rand van de voorhoorn. Het ongekruiste systeem was aanzienlijk kleiner dan het gekruiste. De vestibulospinale vezels afdalend in de sulcomarginale fasciculus bleken te eindigen in lamina 8. Bij de meest volledige onderbrekingen van deze vezelsystemen werd tot in de grijze stof van het sacrale merg degeneratie gevonden.

De ongekruiste, laterale vestibulospinale vezels, afkomstig uit de kern van Deiters, bleken in de homolaterale grijze stof te eindigen in laminae 8 en 9 op hoog cervicaal niveau. Tot in laag lumbale segmenten waren de vezeleindigingen van dit systeem te vinden in lamina 8.

Tenslotte werden de *reticulospinale vezels*, ontspringend in de pons en de medulla oblongata, bestudeerd. Wederom in navolging van Busch werden deze vezels in vier systemen ingedeeld, te weten de ongekruiste mediale reticulospinale vezels, de ongekruiste laterale bulbospinale vezels (fasciculus Thomasi), de gekruiste pontospinale vezels en de gekruiste bulbospinale vezels. Wij waren in staat de bevindingen van Busch grotendeels te bevestigen.

1. De ongekruiste mediale reticulospinale vezels, ontspringend caudaal in de pons en rostraal in de medulla oblongata, bleken in het myelum voornamelijk ventraal in de voorstreng te descenderen. In de homolaterale grijze stof werden op hoog cervicale niveaus de degenererende praeterminalia van dit systeem gevonden in laminae 5, 6, 7, 8, 9 en 10. In de laag cervicale en de hoog thoracale segmenten en ook in de lumbosacrale intumescentie werden deze praeterminalia gevonden in laminae 7, 8 en 10. Hoog lumbaal bevond de degeneratie zich in laminae 8, 9 en 10. De vezels van dit systeem — of hun collateralen — bleken tijdens hun beloop door het ruggemerg voor een gedeelte de mediaanlijn te passeren. Dit was af te leiden uit het feit dat ook in de heterolaterale grijze stof door het gehele ruggemerg, zij het ook in mindere mate, degeneratie werd gevonden in laminae 7, 8 en 10.
2. De ongekruiste laterale bulbospinale vezels (fasciculus Thomasi) bleken verspreid te liggen in de anterolaterale funiculus, echter grotendeels buiten het sulcomarginale gebied. De degenererende praeterminalia werden uitsluitend in de homolaterale grijze stof gevonden, en wel in de hoog cervicale delen van het ruggemerg in laminae 7, 8 en 9. Op lager niveau werd de degeneratie tot in de lumbosacrale intumescentie gevonden in lamina 8. Dit systeem bleek voornamelijk te bestaan uit dunne vezels.
3. De gekruiste pontospinale vezels bleken in de dwarscoupe van het ruggemerg te liggen dorsaal in de zijstreng, in nauwe topografische relatie met het mediale deel van het rubrospinale vezelsysteem. Het betrof hier voornamelijk een klein aantal dikke vezels. Deze pontospinale vezels werden helaas niet selectief genoeg onderbroken om een duidelijke uitspraak te kunnen doen omtrent hun eindigingen in de grijze stof.
4. De gekruiste bulbospinale vezels besloegen in de heterolaterale voorstreng, in tegenstelling tot de andere reticulospinale systemen, een nog al scherp omschreven areaal. Vrijwel in alle ruggemergssegmenten bevonden zich hun eindigingen in de heterolaterale grijze stof in laminae 7 en 8, hoog cervicaal echter ook in lamina 9.

Hoewel in het mediale reticulospinale vezelsysteem en in de fasciculus Thomasi zeer lange vezels voorkwamen, welke reikten tot in de laag

lumbale segmenten, bleek toch een belangrijk deel der reticulospinale vezels te eindigen in het cervicale merg. Er werd een geringe mate van specificiteit gevonden met betrekking tot de localisatie der eindigingen van drie van de vier reticulospinale systemen in de diverse laminae in de grijze stof.

Ons onderzoek werd beëindigd met een algemene beschouwing over de verkregen resultaten.

Puntsgewijs zullen thans de voornaamste conclusies worden vermeld.

1. Allereerst leek het belangrijk te wijzen op het feit, dat de meeste onderzochte vezelsystemen tot op heden slechts zelden met een daartoe geëigende zilverkleuring wat betreft hun eindigingen werden bestudeerd. Bovendien werd in vroegere onderzoekingen vrijwel nimmer een bevredigende selectiviteit van de laesies bereikt, o.a. omdat de meeste auteurs geen gebruik maakten van een stereotactische methodiek.

   De methode volgens Nauta-Gygax (axonkleuring) geeft een veel nauwkeuriger en tevens veel uitvoeriger beeld dan de tot nu toe veelal toegepaste kleuring volgens Marchi (kleuring van gedegenereerde myeline). Bij de eerstgenoemde methodiek worden immers eveneens de niet gemyeliniseerde vezelgedeelten in de grijze stof zichtbaar gemaakt. Op de bezwaren van de Glees methodiek werd gewezen.
2. Er werd opgemerkt dat in de cervicale- en de lumbosacrale intumescenties om de ventrolateraal gelegen grote motorische voorhoorncellen vrijwel nimmer degenererende praeterminalia werden gevonden. Dit was ook niet het geval na volledige onderbrekingen van de fasciculus longitudinalis medialis op laag medullair niveau en na een hemichordotomie ter hoogte van de pyramide kruising. Het bleek dus niet mogelijk directe verbindingen aan te tonen vanuit supraspinale centra naar de genoemde voorhoorncellen.
3. Voorts werd vastgesteld dat tussen mesencephalon, pons en medulla oblongata en de hoog cervicale delen van het ruggemerg het aantal directe descenderende verbindingen veel talrijker was dan het aantal verbindingen met de meer caudale delen van het ruggemerg.
4. Mede op grond van literatuurstudie werd de mening geponeerd, dat het op basis van de verbindingen der gangliëncellen ondoenlijk

was een overzichtelijke en met de werkelijkheid overeenstemmende indeling van de grijze stof van het ruggemerg op te stellen.

5. Er bleek bij de kat een zeker verband te bestaan tussen de localisatie van de lange afdalende vezelsystemen in de witte stof van het ruggemerg en de localisatie van de eindigingen dezer systmen in de grijze stof. De cortico-, rubro- en gekruiste pontospinale vezels die in de zijstreng afdalen bleken voornamelijk te eindigen in de intermediaire grijze stof en aan de basis van de achterhoorn, terwijl de interstitio-, tecto- en vestibulospinale vezels en drie van de vier reticulospinale vezelsystemen, die in de voorstreng descenderen, voor het overgrote deel in de voorhoorn bleken te eindigen.
6. De aandacht werd gevestigd op het overschrijden der mediaanlijn van een deel der tectospinale- en mediale reticulospinale vezels (of hun collateralen) in hun beloop door het ruggemerg.
7. Er werd gewezen op het belang der propriospinale vezels in verband met het feit dat de onderzochte systemen voor een belangrijk deel, de rubrospinale baan uitgezonderd, uit korte vezels bleken te bestaan. Het mediale reticulospinale- en het laterale bulbospinale systeem bleken nog het grootste aantal lange vezels te bevatten. Deze beide vezelsystemen bereikten ongekruist het ruggemerg.
8. In het algemeen kon worden gezegd, dat de eindigingsarealen van de meeste der onderzochte systemen elkaar in de randgebieden overdekten.

REFERENCES*)

BALTHASAR, K.: Morphologie der Tibialis- und Peronaeus-Kerne bei der Katze. Arch. f. Psych. u. Ztschr. Neur., 188: 345-378, 1952.

BECHTEREW, W. VON: Über ein besonderes im vorderem Teil der Seitenstränge des Rückenmarkes verlaufendes Bündel langer Fasern. Neur. Zbl., 7: 155-156, 1885.

BECHTEREW, W. VON: (1897), as cited by Tschermak, 1898.

BEUSEKOM, G. T. VAN: Fibre analysis of the anterior and lateral funiculi of the cord in the cat. Thesis Leiden, 1955.

BOK, S. T.: Das Rückenmark. In: VON MÖLLENDORFF: Hdb. d. mikr. Anat. d. Menschen., 4: 478-578, 1928.

BOWSHER, D., BRODAL, A. and WALBERG, F.: The relative values of the Marchi method and some silver techniques. Brain, 83: 150-161, 1960.

BOYCE, R.: A contribution to the study of descending degenerations in the brain and spinal cord, and of the seat of origin and paths of conduction of the fits in absinthe epilepsy. Phil. Transact. Roy. Soc. London, Ser. B, 186: 321-382, 1896.

BUCHANAN, A. R.: The course of the secondary vestibular fibers in the cat. J. Comp. Neurol., 67: 183-204, 1937.

BUCHER, V. M. and BÜRGI, S. M.: Some observations on the fiber connections of the di- and mesencephalon in the cat. II. Fiber connections of the pretectal region and the posterior commissure. J. Comp. Neurol., 96: 139-178, 1952.

BUSCH, H. F. M.: An anatomical analysis of the white matter in the brainstem of the cat. Thesis Leiden, 1961.

CAJAL, S. RAMÓN Y: Histologie du système nerveux de l'homme et des vertébrés, 378-523. Madrid, 1909.

CHAMBERS, W. W. and LIU, C. N.: Corticospinal tract of the cat. J. Comp. Neur., 108: 23-57, 1957.

CHAMBERS, W. W., LIU, C. Y. and LIU, C. N.: A modification of the Nauta technique for staining of degenerating axons in the central nervous system. Anat. Rec., 124: 391, 1956.

CLARKE, J.: Further researches on the grey substance of the spinal cord. Philos. Trans. Royal Soc., 149: 437-467, 1851.

COLLIER, J. and BUZZARD, F.: Descending mesencephalic tracts in cat, monkey and man. Brain, 24: 177-221, 1901.

ECONOMO, C. J. VON, and KARPLUS, J. P.: Zur Physiologie und Anatomie des Mittelhirns. Arch. f. Psychiat., 46: 275-356, 377-429, 1910.

ELLIOT, H. C.: Studies on the motor cells of the spinal cord. Amer. J. of Anat., 70: 95-117, 1942.

EVANS, D. H. L. and HAMLYN, L. H.: Silver degeneration methods in the central nervous system. J. Anat. London, 90: 193-203, 1956.

FERRARO, A., PACELLA, B. L. and BARRERA, S. E.: Effects of lesions of the medial vestibular nucleus. J. Comp. Neurol., 73: 7-36, 1940.

FOERSTER, O. and GAGEL, O.: as cited by Nathan and Smith, 1955.

FRASER, E. H.: An experimental research into the relations of the posterior longitudinal bundle and Deiters' nucleus. J. Physiol., Lond., 27: 372-398, 1901.

GEHUCHTEN, A. VAN: Connections centrales du noyeau de Deiters et des masses grises voisines. Le Névraxe, 6: 19-73, 1904.

GEHUCHTEN, P. VAN: Recherches expérimentales sur les terminaisons du nerf vestibulaire et sur les voies vestibulaires centrales. Rev. d'oto-neuro-oculistique, 5: 777-791, 1927.

GIBSON, W. C.: Degeneration of the boutons terminaux in the spinal cord. Arch. Neurol. Psych. Chicago, 38: 1145-1147, 1937.

* The literature was studied until the end of 1960, an occasional publication excepted.

GLEES, P.: Terminal degeneration within the central nervous system as studied by a new silver method. J. Neuropath. Exp. Neurol., 5: 54-59, 1946.

GLEES, P. and NAUTA, W. J. H.: A critical review of studies on axonal and terminal degeneration. Mschr. Psych. Neurol., 129: 74-91, 1955.

GRAY, L. P.: Some experimental evidence on the connections of the vestibular mechanism in the cat. J. Comp. Neurol., 41: 319-365, 1926.

HASSLER, R. and HESS, W. R.: Experimentelle und anatomische Befunde über die Drehbewegungen und ihre nervösen Apparate. Arch. f. Psychiat. u. Ztschr. Neurol., 192: 488-526, 1954.

HAYHOW, W. R.: Experimental degeneration of optic axons in the lateral geniculate body of the cat. Acta Anat., 37: 281-289, 1959.

HELD, H.: Die centralen Bahnen des Nervus acusticus bei der Katze. Arch. f. Anat. u. Physiol., Anat. Abth., 271-291, 1891.

HELD, H.: Über eine directe acustische Rindenbahn und den Ursprung des Vorderseitenstranges beim Menschen. Arch. f. Anat. u. Physiol., Anat. Abth., 257-269, 1892.

HELD, H.: Die Beziehungen des Vorderseitenstranges zu Mittel- und Hinterhirn. Abh. Math.-phys. Classe Kön. Sächs. Ges. d. Wissensch., 18: 351-357, 1893.

HINMAN, A. and CARPENTER, M. B.: Efferent projections of the red nucleus in the cat. J. Comp. Neur., 113: 61-83, 1959.

HOFF, E. C. and HOFF, H. E.: Spinal terminations of the projection fibres from the motor cortex of primates. Brain, 57: 454-474, 1934.

JACOBSOHN, L.: Über die Kerne des menschlichen Rückenmarks. Anhang z. d. Abhandl. Kgl. Preuss. Akad. Wiss. 72 pp. Berlin, 1908.

KLIMOFF, J.: Über die Leitungsbahnen des Kleinhirns. Arch. f. Anat. u. Physiol., Anat. Abt., 11-28, 1899.

KOHNSTAMM, O.: Über die Coordinationskerne des Hirnstammes und die absteigenden Spinalbahnen. Mschr. f. Psychiat. u. Neurol., 8: 261-293, 1900.

KURU, M., KURATI, T. and KOYAMA, Y: The bulbar vesiculoconstrictor centre and the bulbo-sacral connections arising from it. A study of the function of the lateral reticulospinal tract. J. Comp. Neur., 113: 365-388, 1959.

KUYPERS, H. G. J. M.: An anatomical analysis of cortico-bulbar connexions to the pons and the lower brainstem in the cat. J. of Anat., 92: 198-219, 1958.

KUYPERS, H. G. J. M.: Central projections to motor- and somatosensory cell groups. Brain, 83: 161-185, 1960.

KUYPERS, H. G. J. M., FLEMMING, W. R. and FARINHOLT, J. W.: Descending projections to spinal motor- and sensory cell-groups in the monkey; cortex versus subcortex. Science, 132: 38-40, 1960.

LEWANDOWSKY, M.: Untersuchungen über die Leitungsbahnen des Truncus Cerebri und ihren Zusammenhang mit denen der Medulla Spinalis und des Cortex Cerebri. Fischer, Jena, 1904.

LLOYD, R. E.: On chromatolysis in Deiters' nucleus after hemisection of the cord. J. Physiol., 25: 191-195, 1900.

MARBURG, O. and WARNER, F. J.: The pathways of the tectum (anterior colliculus) of the midbrain in cats. J. nerv. ment. Dis., 106: 415-446, 1947.

MASSAZZA, A.: as cited by Rexed 1952.

MASSOPUST, L. C.: Terminal degeneration study of the posterior longitudinal fasciculus. Anat. Rec., 127: 330, 1957.

MEESSEN, R. and OLSZEWSKI, J.: Cytoarchitektonischer Atlas des Rautenhirns des Kaninchens. Karger, Basel, 1949.

METTLER, F. and ZIMMERMAN, F. T.: Homolateral reflex exaggeration after brainstem lesion. J. Comp. Neurol., 113-129, 1943.

MONAKOW, C. VON: Experimenteller Beitrag zur Kenntniss des Corpus restiforme, des "äusseren Acusticuskerns" und deren Beziehung zum Rückenmark. Arch. f. Psychiat., 14: 1-16, 1883.

MONAKOW, C. VON: Striae acusticae und untere Schleife. Arch. f. Psychiat., 22: 1-27, 1890.

MONAKOW, C. VON: Der rote Kern, die Haube und die Regio subthalamica bei einigen Säugetieren und beim Menschen. Arb. Hirnanat. Inst. Zürich, III: 49-267; id. IV: 103-226, 1909.

MÜNZER, E. and WIENER, H.: Das Zwischen- und Mittelhirn des Kaninchens und die Beziehungen dieser Teile zum übrigen Centralnervensystem, mit besonderer Berücksichtigung der Pyramidenbahn und Schleife. Mschr. f. Psychiat. u. Neurol., 12: 241-279, 1902.

MUSKENS, L. J. J.: An anatomico-physiological study of the posterior longitudinal bundle in its relation to forced movements. Brain, 36: 352-426, 1914.

MUSSEN, A. T.: Experimental investigations on the cerebellum. Brain, 50: 313-349, 1927.

NATHAN, P. W. and SMITH, M. C.: Long descending tracts in man. I. Review of the present knowledge. Brain, 78: 248-303, 1955.

NATHAN, P. W. and SMITH, M. C.: Fasciculi proprii of the spinal cord in man. Brain, 82: 610-669, 1959.

NAUTA, W. J. H. and RYAN, L. F.: Selective silver impregnation of degenerating axons in the central nervous system. Stain Techn., 27: 174-179, 1952.

NAUTA, W. J. H. and GYGAX, P. A.: Silver impregnation of degenerating axons in the central nervous system; a modified technic. Stain Techn., 29: 91-93, 1954.

NAUTA, W. J. H.: Über die sogenannte terminale Degenerationen im Zentralnervensystem und ihre Darstellung durch Silberimpregnation. Schw. Arch. f. Neurol. u. Psych., 66: 353, 1950.

NAUTA, W. J. H.: Silver impregnation of degenerating axons. In: Windle, W. F.: New research techniques of neuroanatomy, 17-26. Thomas, Illinois, 1957.

ONO, N.: Untersuchungen und Studien über die Ursprungszellen des N. phrenicus. Japan. J. of Med. Sci. I, Anat., V: 1, 1934.

PAPEZ, J. W.: Reticulospinal tracts in the cat. J. Comp. Neur., 41: 365-409, 1926.

PAWLOW, W.: Les voies descendantes des tubercules quadrijumeaux supérieurs. Le Névraxe, 1, 57-76, 129-138, 1900.

PEARCE, G. W. and GLEES, P.: The tectal projection to the brainstem reticular formation in the cat. J. Anat., London, 90: 599, 1956.

PFEIFFER, R. A.: Über der feineren Bau des Zentralnervensystems eines Anencephalus. Mschr. f. Psych. u. Neur., 40: 1-30, 1916.

PITTS, R. F.: The respiratory centre and its descending pathways. J. Comp. Neur., 72: 605-625, 1940.

POMPEIANO, O. and BRODAL, A.: Experimental demonstration of a somatotopical origin of the rubrospinal fibers in the cat. J. Comp. Neurol., 108: 225-252, 1957.

POMPEIANO, O. and BRODAL, A.: The origin of vestibulospinal fibres in the cat. An experimental study, with comments on the descending medial longitudinal fasciculus. Arch. Ital. Biol., 95: 166-195, 1957.

PROBST, M.: Über vom Vierhügel, von der Brücke und vom Kleinhirn absteigende Bahnen. Dtsch. Ztschr. Nervenheilk., 15: 192-221, 1899.

PROBST, M. :Experimentelle Untersuchungen über die Schleifenendigung, die Haubenbahnen, das dorsale Längsbündel und die hintere Commissur. Arch. f. Psychiat., 33: 1-57, 1900.

PROBST, M.: Experimentelle Untersuchungen über die Anatomie und Physiologie der Leitungsbahnen des Gehirnstammes. Arch. f. Anat. u. Physiol., Anat. Abt., suppl., 147-254, 1902.

RAMONES, G. J.: The motor cell columns of the lumbo-sacral spinal cord of the cat. J. Comp. Neur., 94: 313-364, 1951.

RASDOLSKY, J.: Über die Endigung der extraspinalen Bewegungssysteme im Rückenmark. Ztschr. f. d. ges. Neur. u. Psych., 86: 361-374, 1923.

RASMUSSEN, A. T.: Secondary vestibular tracts in the cat. J. Comp. Neurol., 54: 143-171, 1932.

RASMUSSEN, A. T.: Tractus tecto-spinalis in the cat. J. Comp. Neurol., 63: 501-525, 1936.

RASMUSSEN, G. L.: Selective silver impregnation of synaptic endings. In: Windle, W. F.: New research techniques of neuroanatomy, 27-39. Thomas, Illinois, 1957.

REDLICH, E.: Beitrage zur Anatomie und Physiologie der motorischen Bahnen bei der Katze. Mntschr. f. Psych. u. Neur. V: 112-128; 192-207, 1899.

REXED, B.: The cytoarchitectonic organization of the spinal cord in the cat. J. Comp. Neur., 96: 415-496, 1952.

REXED, B.: A cytoarchitectonic atlas of the spinal cord in the cat. J. Comp. Neur., 100: 297-397, 1954.

ROTHMANN, M.: as cited by Nathan and Smith 1955.

RUSSELL, J. S. R.: The origin and destination of certain afferent and efferent tracts in the medulla oblongata. Brain, 20: 409-440, 1897.

SCHUEREN, A. VAN DER: Etude anatomique du faisceau longitudinal postérieur. Le Névraxe, 13: 183-309, 1912.

SIE, P. G.: Localization of fibresystems within the white matter of the medulla oblongata and the cervical cord in man. Thesis, Leiden, 1956.

SPRAGUE, J. M.: The distribution of dorsal root fibres on motor cells in the lumbosacral cord of the cat, and the site of excitatory and inhibitory terminals in monosynaptic pathways. Proc. Royal Soc., 149: 534-557, 1958.

STILLING, B.: as cited by Rexed 1952.

SZENTÁGOTHAI-SCHIMERT, J.: Die Endigungsweise der absteigenden Rückenmarksbahnen. Ztschr. f. Anat. u. Entw. Gesch., 111: 322-330, 1942.

TASIRO, S.: Experimentell-anatomische Untersuchung über die efferenten Bahnen aus den Vierhügeln der Katze. Ztschr. mikr. anat. Forsch., 47: 1-32, 1940.

THOMAS, A.: Le faisceau cérébelleux descendant. Compt. Rend. Soc. Biol., sér. 10, 4: 36-37, 1897.

THOMAS, A.: Etude sur quelques faisceaux descendantes de la moelle. J. de Physiol. Path. gén., I: 47-61, 1899.

THOMAS, A.: (1903), as cited by Nathan and Smith 1955.

THOMAS, D. M., KAUFMAN, R. P., SPRAGUE, J. M. and CHAMBERS, W. W.: Experimental studies of the vermal cerebellar projections in the brainstem of the cat. J. Anat., 90: 371-386, 1956.

TORVIK, A. and BRODAL, A.: The origin of reticulospinal fibers in the cat. An experimental study. Anat. Rec., 128: 113-137, 1957.

TSCHERMAK, A.: Über den centralen Verlauf der aufsteigenden Hinterstrangbahnen und deren Beziehungen zu den Bahnen im Vorderseitenstrang. Arch. f. Anat. u. Physiol. Leipzig. Anat. Abt., 291-403, 1898.

TSURUYAMA, K.: Untersuchung über die medullaren und ganglionären Ursprunge des N. accessorius bei der Katze. Japan. J. of Med. Scien. I, Anat. VII: 1-45, 1938.

VERHAART, W. J. C.: The fibre structure of the cord in the cat. Acta Anat., 18: 88-100, 1953.

VERHAART, W. J. C. and BEUSEKOM, G. T. VAN: Fibre tracts in the cord in the cat. Acta Psych. et Neur. Scand., 33: 359-367, 1958.

WALBERG, F.: Descending connections to the lateral reticular nucleus. An experimental study in the cat. J. Comp. Neur., 109: 363-389, 1958.

WALBERG, F., BOWSHER, D. and BRODAL, A.: The termination of primary vestibular fibres in the vestibular nuclei in the cat. An experimental study with silver methods. J. Comp. Neur., 110: 391-421, 1958.

WALDEYER, H. (1888): as cited by Rexed 1952.

WARWICK, R. and MITCHELL, G. A. G.: Phrenic nucleus of the macaque. J. Comp. Neur., 105: 553-575, 1956.

WINKLER, C.: Handboek der Neurologie. II: De bouw van het Zenuwstelsel, dl. II. Haarlem, F. Bohn, 1920.

WOODBURNE, R. T.: Certain phylogenetic anatomical relations of localizing significance for the mammalian central nervous system. J. Comp. Neur., 71: 215-257, 1939.

YOSHIDA, I.: Ein Beitrag zur Kenntnis der zentralen Vestibularisbahn. Fol. Anat. Japon., 2: 283-288, 1924.

ZIEHEN, TH.: Anatomie des Zentralnervensystems. In: v. Bardeleben: Hdb. d. Anat. des Menschen; Bd. 4, Abt. 1. Fischer, Jena, 1899.